

MEDICAL REVIEW

**JOURNAL OF THE SOCIETY OF PHYSICIANS OF VOJVODINA OF THE
MEDICAL SOCIETY OF SERBIA**
THE FIRST ISSUE WAS PUBLISHED IN 1948

Editor-in-Chief

LJILJA MIJATOV UKROPINA

Assistant to the Editor-in-Chief for Clinical Branches: PETAR SLANKAMENAC

Assistant to the Editor-in-Chief for Imaging Methods: VIKTOR TILL

Assistants to the Editor-in-Chief

BOJANA KRSTONOŠIĆ

ŽELJKO ŽIVANOVIĆ

EDITORIAL BOARD

OKAN AKHAN, Ankara
ANDREJ ALEKSANDROV, Birmingham
STOJANKA ALEKSIĆ, Hamburg
VLADO ANTONIĆ, Baltimor
ITZHAK AVITAL, Bethesda
KAREN BELKIĆ, Stockholm
JEAN-PAUL BEREGI, Lille Cedex
HELENA BERGER, Ljubljana
MILAN BREBERINA, Novi Sad
RADOVAN CVIJANOVIĆ, Novi Sad
VLADIMIR ČANADANOVIĆ, Novi Sad
IVAN DAMJANOV, Kansas City
DRAGAN DANKUC, Novi Sad
OMER DEVAJA, Meidstone
PETAR DRVIŠ, Split
TATJANA ĐURĐEVIĆ-MIRKOVIĆ, Novi Sad
VERA GRUJIĆ, Novi Sad
IRENA HOČEVAR BOLTEŽAR, Ljubljana
MARINA JOVANOVIĆ, Novi Sad
DRAGAN KATANIĆ, Novi Sad
ALEKSANDAR KIRALJ, Novi Sad
DRAGAN KOVAČEVIĆ, Novi Sad
DUŠKO KOZIĆ, Novi Sad
DUŠAN LALOŠEVIĆ, Novi Sad
JORGE MANUEL COSTA LAINS, Coimbra
VELJKO MARIĆ, Foča
SMILJANA MARINKOVIĆ, Novi Sad

VLADIMIR MARTINEK, Bad Aibling
SINIŠA MASLOVARA, Osijek
JASNA MIHAILOVIĆ, Novi Sad
LJILJA MIJATOV UKROPINA, Novi Sad
MIROSLAV MILANKOV, Novi Sad
IGOR MITIĆ, Novi Sad
NADA NAUMOVIĆ, Novi Sad
ALEKSANDRA NOVAKOV MIKIĆ, Novi Sad
AVIRAM NISSAN, Ein Karem
JANKO PASTERNAK, Novi Sad
LJUBOMIR PETROVIĆ, Novi Sad
MIHAEL PODVINEC, Basel
JOVAN RAJS, Danderyd
PETAR E. SCHWARTZ, New Haven
MILAN SIMATOVIĆ, Banja Luka
TOMAŠ SKRIČKA, Brno
PETAR SLANKAMENAC, Novi Sad
EDITA STOKIĆ, Novi Sad
ALEXANDER STOJADINOVIĆ, Glen Alen
GORAN STOJILJKOVIĆ, Novi Sad
VIKTOR TILL, Novi Sad
TIBOR TOT, Falun
TAKASHI TOYONAGA, Kobe
KONSTANTIN VIKTOROVIĆ SUDAKOV, Moskva
NADA VUČKOVIĆ, Novi Sad
ZORAN VUJKOVIĆ, Banja Luka
PETAR VULEKOVIĆ, Novi Sad

Proof-reading for Serbian Language: Dragica Pantić

Proof-reading for English Language: Jasminka Anojčić

Technical Secretary: Vesna Šaranović

Technical Support: "Grafit" Novi Sad

UDC and descriptors prepared by: the Library of the Faculty of Medicine, Novi Sad

MEDICAL REVIEW is published two-monthly (six double issues per a year) in the circulation of 1000 copies. Payment for individuals from the territory of Serbia for the year 2016 is 3,000.00 dinars (the VAT being calculated in) and 4,000.00 dinars for the individuals outside the territory of Serbia, and 8,000.00 dinars (+ the VAT) for institutions. The payments are to be made to the account number 340-1861-70 or 115-13858-06, with the remark "Additional membership fee for the Medical Review".

Copyright © Društvo lekara Vojvodine Srpskog lekarskog društva Novi Sad 1998.

**The manuscripts can be submitted on the web-page: aseestant.ceon.rs/index.php/medpreg/.
Address Editorial: Društvo lekara Vojvodine Srpskog lekarskog društva, 21000 Novi Sad, Vase Stajica 9,
Tel. 021/521-096; 063/81 33 875, E-mail: dlv@neobee.net; Web: www.dlv.org.rs**

MEDICINSKI PREGLED

ČASOPIS DRUŠTVA LEKARA VOJVODINE SRPSKOG LEKARSKOG DRUŠTVA
PRVI BROJ JE ŠTAMPAN 1948. GODINE.

Glavni i odgovorni urednik
LJILJA MIJATOV UKROPINA

Pomoćnik urednika za kliničke grane: PETAR SLANKAMENAC

Pomoćnik urednika za imidžing metode: VIKTOR TILL

Pomoćnici urednika:
BOJANA KRSTONOŠIĆ
ŽELJKO ŽIVANOVIĆ

REDAKCIJSKI ODBOR

OKAN AKHAN, Ankara
ANDREJ ALEKSANDROV, Birmingham
STOJANKA ALEKSIĆ, Hamburg
VLADO ANTONIĆ, Baltimor
ITZHAK AVITAL, Bethesda
KAREN BELKIĆ, Stockholm
JEAN-PAUL BEREGI, Lille Cedex
HELENA BERGER, Ljubljana
MILAN BREBERINA, Novi Sad
RADOVAN CVIJANOVIĆ, Novi Sad
VLADIMIR ČANADANOVIĆ, Novi Sad
IVAN DAMJANOV, Kansas City
DRAGAN DANKUC, Novi Sad
OMER DEVAJA, Meidstone
PETAR DRVIŠ, Split
TATJANA ĐURĐEVIĆ-MIRKOVIĆ, Novi Sad
VERA GRUJIĆ, Novi Sad
IRENA HOČEVAR BOLTEŽAR, Ljubljana
MARINA JOVANOVIĆ, Novi Sad
DRAGAN KATANIĆ, Novi Sad
ALEKSANDAR KIRALJ, Novi Sad
DRAGAN KOVAČEVIĆ, Novi Sad
DUŠKO KOZIĆ, Novi Sad
DUŠAN LALOŠEVIĆ, Novi Sad
JORGE MANUEL COSTA LAINS, Coimbra
VELJKO MARIĆ, Foča
SMILJANA MARINKOVIĆ, Novi Sad

VLADIMIR MARTINEK, Bad Aibling
SINIŠA MASLOVARA, Osijek
JASNA MIHAILOVIĆ, Novi Sad
LJILJA MIJATOV UKROPINA, Novi Sad
MIROSLAV MILANKOV, Novi Sad
IGOR MITIĆ, Novi Sad
NADA NAUMOVIĆ, Novi Sad
ALEKSANDRA NOVAKOV MIKIĆ, Novi Sad
AVIRAM NISSAN, Ein Karem
JANKO PASTERNAK, Novi Sad
LJUBOMIR PETROVIĆ, Novi Sad
MIHAEL PODVINEC, Basel
JOVAN RAJS, Danderyd
PETAR E. SCHWARTZ, New Haven
MILAN SIMATOVIĆ, Banja Luka
TOMAŠ SKRIČKA, Brno
PETAR SLANKAMENAC, Novi Sad
EDITA STOKIĆ, Novi Sad
ALEXANDER STOJADINOVIĆ, Glen Alen
GORAN STOJILJKOVIĆ, Novi Sad
VIKTOR TILL, Novi Sad
TIBOR TOT, Falun
TAKASHI TOYONAGA, Kobe
KONSTANTIN VIKTOROVIĆ SUDAKOV, Moskva
NADA VUČKOVIĆ, Novi Sad
ZORAN VUJKOVIĆ, Banja Luka
PETAR VULEKOVIĆ, Novi Sad

Lektor za srpski jezik: Dragica Pantić

Lektor za engleski jezik: Jasminka Anojčić

Tehnički sekretar: Vesna Šaranović

Tehnička podrška: „Grafit“, Novi Sad

Izrada UDK i deskriptora: Biblioteka Medicinskog fakulteta, Novi Sad

MEDICINSKI PREGLED izlazi dvomesečno (šest dvobroja godišnje), u tiražu od 1000 primeraka. Pretplata za pojedince sa teritorije Srbije za 2016. godinu iznosi 3.000,00 dinara (sa uračunatim PDV-om), a 4.000,00 dinara za pojedince van teritorije Srbije, a za ustanove 8.000,00 dinara (uz dodavanje PDV-a). Uplate se vrše na račun broj 340-1861-70 ili 115-13858-06, s naznakom „Dodatna članarina za Medicinski pregled”.
Copyright © Društvo lekara Vojvodine Srpskog lekarskog društva Novi Sad 1998.

Prijem rukopisa vrši se u elektronskoj formi na stranici: asestant.ceon.rs/index.php/medpreg/.

Adresa redakcije: Društvo lekara Vojvodine Srpskog lekarskog društva,
21000 Novi Sad, Vase Stajića 9, Tel. 021/521-096; 063/81 33 875

E-mail: dlv@neobee.net; Web: www.dlv.org.rs

Editor-in-Chief/Glavni i odgovorni urednik

Prof. dr Miroslav Milankov

Editorial Board/Uređivački odbor

Prof. dr Miroslav Milankov

Prof. dr Dragan Savić

Prof. dr Milan Stanković

Doc. dr Zoran Gojković

Doc. dr Srđan Ninković

Doc. dr Vladimir Harhaji

Asist. dr sc. med. Radmila Matijević

Proof-reading for English Language/*Lektor za engleski jezik*: Jasminka Anojčić

Proof-reading for Serbian Language/*Lektor za srpski jezik*: Dragica Pantić

Technical Secretary/*Tehnički sekretar*: Vesna Šaranović

Technical Support/*Tehnička podrška*: „Grafit”, Novi Sad

UDK and descriptor prepared by the Library of the Faculty of Medicine, Novi Sad

Izrada UDK i deskriptora: Biblioteka Medicinskog fakulteta, Novi Sad

Printed by/*Štampa*:

Uprava za zajedničke poslove pokrajinskih organa - Odsek za poslove štamparije

Circulation: 300 copies/*Tiraž: 300 primeraka*

Clinical Center of Vojvodina, Novi Sad/*Klinički centar Vojvodine Novi Sad*

Department of Orthopedic Surgery and Traumatology

Klinika za ortopedsku hirurgiju i traumatologiju

University of Novi Sad, Faculty of Medicine/*Univerzitet u Novom Sadu, Medicinski fakultet*

SIXTY YEARS OF THE DEPARTMENT OF ORTHOPEDIC SURGERY AND TRAUMATOLOGY

***60 GODINA KLINIKE ZA
ORTOPEDSKU HIRURGIJU I
TRAUMATOLOGIJU***

Novi Sad, 23.12.2016. godine

CONTENTS

EDITORIAL

Miroslav Milankov and Zoran Gojković SIX DECADES OF DEVELOPMENT	7-9
Vladimir Harhaji, Srđan Ninković, Predrag Rašović, Ivica Lalić, Merhan Salabat and Miodrag Vranješ SURGICAL TREATMENT OF UNSTABLE PELVIC RING INJURIES	11-14
Milan Stanković, Nataša Janjić, Ivica Lalić, Nemanja Gvozdenović, Igor Elez and Miodrag Vranješ SHORT VS LONG POSTERIOR FIXATION OF THORACOLUMBAR SPINE INJURIES	15-21
Ivica Lalić, Vladimir Harhaji, Vaso Kecojević, Srđan Ninković, Oliver Dulić and Predrag Rašović ANALYSIS OF ILIZAROV APPARATUS APPLICATION IN ACUTE TRAUMATIC LESIONS AND TREATMENT OF COMPLICATIONS OF DIFFERENT PARTS OF MUSCULOSKELETAL SYSTEM AT THE DEPARTMENT OF ORTHOPEDIC SURGERY AND TRAUMATOLOGY IN NOVI SAD	23-33
Dragan Savić, Aleksandar Lažetić, Veselin Bojat, Srđan Radić, Zoran Gojković and Vladimir Harhaji ARTHROPLASTY OF THE HIP JOINT	35-40
Aleksandar Lažetić, Mirka Lukić Šarkanović, Dragan Savić, Oliver Dulić, Srđan Radić and Mirko Obradović KNEE OSTEOARTHRITIS AND ARTHROPLASTY OF THE KNEE JOINT	41-45
Srđan Ninković, Slađana Radosavljević, Vladimir Harhaji, Ivica Lalić, Nataša Janjić and Mirko Obradović THE USE OF PARTIAL PROSTHESIS IN SHOULDER SURGERY	47-51
Miodrag Vranješ, Ivan Vukašinović, Mirko Obradović, Mile Bjelobrk, Zlatko Budinski and Miroslav Milankov MORPHOMETRIC CHARACTERISTICS OF THE PATELLAR TENDON	53-58
Nataša J. Janjić, Oliver Dulić, Srđan Ninković, Vladimir Harhaji, Zoran Gojković and Miroslav Milankov FUNCTIONAL PERFORMANCE TEST AFTER ANTERIOR CRUCIATE LIGAMENT RECONSTRUCTION WITH HYBRID TIBIAL FIXATION	59-66
Predrag Rašović, Vladimir Harhaji, Srđan Ninković, Ivica Lalić, Marija Marinković and Miroslav Milankov CORRELATION BETWEEN GRAFT CONTAMINATION INCIDENCE AND LENGTH OF SURGERY PERFORMED TO RECONSTRUCT ANTERIOR CRUCIATE LIGAMENT	67-71
Vaso Kecojević, Ivica Lalić, Vladimir Harhaji, Predrag Rašović, Miodrag Vranješ and Mirko Obradović ANKLE ARTHROSCOPY	73-76
Oliver Dulić, Ivica Lalić, Nataša Janjić, Predrag Rašović, Gordan Gavrilović and Džihan Abazović IN STEP WITH CONTEMPORARY TRENDS-STEM-CELLTHERAPY AS A KEY DRIVER OF REGENERATIVE ORTHOPEDICS AT THE CLINICAL CENTER OF VOJVODINA – PRELIMINARY DATA FOR THE TREATMENT OF KNEE OSTEOARTHRITIS AND OSTEOCHONDRAL LESIONS.....	77-84
Radmila Matijević, Vladimir Harhaji, Zoran Gojković, Predrag Rašović, Veselin Bojat and Ivica Lalić RELATIONSHIP BETWEEN BODY MASS INDEX AND OSTEOPOROSIS	85-88
Jovan Grujić and Milica Grujić PRODUCTION OF MEDICAL PRODUCTS FOR THE PURPOSES IN ORTHOPEDICS AND TRAUMATOLOGY IN NOVI SAD.....	89-95
CONTRIBUTION FROM HISTORY OF MEDICINE.....	97-101

SADRŽAJ

UVODNIK

Miroslav Milankov i Zoran Gojković

ŠEST DECENIJA RAZVOJA 7-9

Vladimir Harhaji, Srđan Ninković, Predrag Rašović, Ivica Lalić, Merhan Salabat i Miodrag Vranješ

OPERATIVNI TRETMAN NESTABILNIH POVREDA KARLIČNOG PRSTENA..... 11-14

Milan Stanković, Nataša Janjić, Ivica Lalić, Nemanja Gvozdenović, Igor Elez i Miodrag Vranješ

KRATKA NASUPROT DUGOJ POSTERIORNOJ FIKSACIJI POVREDA TORAKOLUMBALNE KIČME..... 15-21

Ivica Lalić, Vladimir Harhaji, Vaso Kecojević, Srđan Ninković, Oliver Dulić i Predrag Rašović

ANALIZA PRIMENE APARATA PO ILIZAROVU KOD AKUTNIH POVREDA I KOMPLIKACIJA LEČENJA POJEDINIH SEGMENTA LOKOMOTORNOG SISTEMA NA KLINICI ZA ORTOPEDSKU HIRURGIJU I TRAUMATOLOGIJU U NOVOM SADU..... 23-33

Dragan Savić, Aleksandar Lažetić, Veselin Bojat, Srđan Radić, Zoran Gojković i Vladimir Harhaji

ARTROPLASTIKA KUKA 35-40

Aleksandar Lažetić, Mirka Lukić Šarkanović, Dragan Savić, Oliver Dulić, Srđan Radić i Mirko Obradović

OSTEOARTRITIS KOLENA I ARTROPLASTIKA KOLENA 41-45

Srđan Ninković, Slađana Radosavljević, Vladimir Harhaji, Ivica Lalić, Nataša Janjić i Mirko Obradović

PRIMENA PARCIJALNIH PROTEZA U HIRURGIJI RAMENA..... 47-51

Miodrag Vranješ, Ivan Vukašinović, Mirko Obradović, Mile Bjelobrck, Zlatko Budinski i Miroslav Milankov

MORFOMETRIJSKE KARAKTERISTIKE LIGAMENTA ČAŠICE..... 53-58

Nataša J. Janjić, Oliver Dulić, Srđan Ninković, Vladimir Harhaji, Zoran Gojković i Miroslav Milankov

FUNKCIONALNI REZULTATI NAKON REKONSTRUKCIJE PREDNJEG UKRŠTENOG LIGAMENTA TEHNIKOM HIBRIDNE FIKSACIJE 59-66

Predrag Rašović, Vladimir Harhaji, Srđan Ninković, Ivica Lalić, Marija Marinković i Miroslav Milankov

UTICAJ DUŽINE TRAJANJA OPERATIVNOG ZAHVATA NA INCIDENCIJU KONTAMINACIJE KALEMA TOKOM REKONSTRUKCIJE PREDNJEG UKRŠTENOG LIGAMENTA KOLENA 67-71

Vaso Kecojević, Ivica Lalić, Vladimir Harhaji, Predrag Rašović, Miodrag Vranješ i Mirko Obradović

ARTROSKOPIJA SKOČNOG ZGLOBA 73-76

Oliver Dulić, Ivica Lalić, Nataša Janjić, Predrag Rašović, Gordan Gavrilović i Džihan Abazović

U KORAK SA SAVREMENIM TRENDOVIMA – TERAPIJA MATIČNIM ČELIJAMA KAO KLJUČNI POKRETAČ REGENERA- TIVNE ORTOPEDIJE U KLINIČKOM CENTRU VOJVODINE – PRELIMINARNI REZULTATI LEČENJA OSTEOARTRITISA I OSTEOHONDALNIH LEZIJA 77-84

Radmila Matijević, Vladimir Harhaji, Zoran Gojković, Predrag Rašović, Veselin Bojat i Ivica Lalić

ODNOS IZMEĐU INDEKSA TELESNE MASE I OSTEOPOROZE 85-88

Jovan Grujić i Milica Grujić

PROIZVODNJA MEDICINSKIH SREDSTAVA ZA POTREBE ORTOPEDIJE I TRAUMATOLOGIJE U NOVOM SADU 89-95

PRILOG IZ ISTORIJE MEDICINE..... 97-101



Building of the Department of Orthopedic Surgery and Traumatology
Zgrada Klinike za ortopedsku hirurgiju i traumatologiju

EDITORIAL

UVODNIK

Clinical Center of Vojvodina, Novi Sad
Department of Orthopedic Surgery and Traumatology
University of Novi Sad, Faculty of Medicine

UDK 614.2:617.3(497.113 Novi Sad)(091)
DOI: 10.2298/MPNS16S1007M

SIX DECADES OF DEVELOPMENT

ŠEST DECENIJA RAZVOJA

Miroslav MILANKOV and Zoran GOJKOVIĆ

The Department of Orthopedic Surgery and Traumatology of the Clinical Center of Vojvodina is today a modern hospital providing health care for the patients with trauma and disorders of the locomotion system. It all started in the 1930s in Novi Sad, when top surgeons of the time, including Dr. Vujić, Dr. Pravdica, Dr. Holender and Dr. Brezovski [1] started to treat orthopedic patients. A great impulse in treating orthopedic patients came from Dr. Katherine MacPhail who established Children's Sanatorium for the Treatment of Bone Tuberculosis in Sremska Kamenica, which was in operation until 1992 [2, 3]. After the end of the Second World War, there was a department for orthopedic surgery within the Main Provincial Hospital which in 1956 grew into the first independent Department of Orthopedics and Traumatology led by the experienced orthopedic surgeon, Dr. Vladimir Raženj. From 1959 till 1963 the Department was led by Prim. Dr. Dobrivoje Gradištanac. In 1963, this Department together with the former „English Hospital“ at Sremska Kamenica was incorporated into the so-called Clinic for Surgical Diseases and divided in the Department of Orthopedics (led by Prof. Milenko Dosen [4–6]) and separate Department of Traumatology (led by Prim. Dr. Stojan Letić [7, 8]) which existed as such until 1975, when they were integrated again into a single unit which evolved into the Department of Orthopedic Surgery and Traumatology in 1980 [9]. In 1998, the head of the Clinic was Prof. Dr. Jovan Krajinović [10], under whose leadership the orthopedic surgical practice in Vojvodina transformed into a modern surgical discipline with the Department being a leading centre for treating foot and ankle pathology [11, 12]. During the social turmoil in the last decade of the 20th century, the medical doctors of the Department took an active part in treating the wounded and injured people both at the Department and in the field. A significant contribution to the organization of the

medical care service at that time was given by Prof. Dr. Djordje Janjić [13] who was the head of the Department between 2000 and 2003, and after that Prof. Dr. Goran Ercegan [14] (2003–2007) became a medical director of the hospital. He was succeeded by Prof. Dr. Miroslav Milankov, who occupied this position for a short time, to be followed by Prof. Dr. Dragan Savić [15], who was a medical director from 2007 to March 2016. He introduced the European standards into the operation of the Department. Prof. Dr. Dragan Savić was replaced at this position by Dr. Aleksandar Lažetić [16] who made great efforts to introduce new *osteosynthesis techniques* for the treatment of fractures into the routine orthopedic trauma practice. Today, the medical director of the Department is again Prof. Dr. Miroslav Milankov [17].

The modern osteosynthesis techniques for the treatment of fractures have successfully been applied at the Department for many years now. Intramedullary locking nails were introduced into daily practice by Prof. Dr. Saša Vukadinović [18] in the 1980s.

The first hip replacement surgery was conducted back in 1969 and such a surgical procedure has become a common practice at the Department [19]. Namely, some 500 hip prosthetic implants are placed each year. Since 1990, when Prof. Dr. Goran Ercegan conducted the first knee replacement surgery [20] some 350 knee implants are placed each year.

Bone allo-transplantation was introduced within the transplantation program back in the 1980s upon the initiative of Prof. Dr. Aleksandar Jovanović and today bone allografts are used in revision hip surgery and revision anterior cruciate ligament (ACL) reconstruction surgery.

Sports traumatology has always held an important place at the Department [21]. The first arthroscopic meniscectomy was conducted at the Department in 1993, and arthroscopic reconstruction of the anterior cruciate ligament (ACL) in the knee was done in 1998 [22–24], followed by the arthroscopic

Table 1. Medical Directors of the Department of Orthopedic Surgery
Tabela 1. Direktori Klinike za ortopedsku hirurgiju i traumatologiju

Dr. Vladimir Raženj	1956-1959
Prim. Dr. Dobrivoje Gradištanac	1959-1963
Prof. Milenko Došen	1963-1979
Prof. Dr. Jovan Krajčinović	1980-1998
Prof. Dr. Djordje Janjić	1998-2003
Prof. Dr. Goran Ercegan	2003-2007
Prof. Dr. Miroslav Milankov	2007-2007
Prof. Dr. Dragan Savić	2007-2016
Dr. Aleksandar Lažetić	2016-2016
Prof. Dr. Miroslav Milankov	2016-

shoulder reconstruction in 2010 [25]. Today around 330 ACL reconstructions in the knee are done each year at the Department, as well as 300 arthroscopic interventions in the knee, shoulder, elbow and ankle.

Bone infections have always posed huge problems for orthopedic surgeons [26, 27]. Therefore, the infection control ward has been for many years headed by Prof. Dr. Stevan Vukadinović [28, 29], and today by Prof. Dr. Milan Stanković.

Spine traumas have also been treated at the Department for many years, and excellent results have been achieved thanks to Prof. Dr. Aleksandar Jovanović and Prof. Dr. Aleksandar Miličić [30, 31]. Their work has been continued by Prof. Dr. Milan Stanković and Dr. Vaso Kecojević.

Credits for the development of scientific thinking and for publishing of a great number of scientific papers in domestic and renowned world medical journals go to Prof. Dr. Želimir Mikić [32–34] who has directed young generations of orthopedic

surgeons and shown them how to develop their scientific and academic career. Experimental surgery was well developed at the end of the past century when a huge number of master's and doctoral theses were written [35, 36]. The Department's medical doctors attended many medical conferences in the country and abroad where they presented our results. In addition, our young medical doctors gained valuable medical experience at the orthopedic centers throughout Europe.

Today the Department employs 23 medical doctors, 47 nurses and medical technicians, 6 physiotherapists, and 3 medical statisticians. In the Clinics 2,400 surgeries and 32,000 medical examinations are done on a yearly basis. The Department is the base of educational activity of the Faculty of Medicine of Novi Sad and it employs three full professors, four assistant professors and 8 assistant lecturers.

References

- Gusman Đ. Kratak istorijat razvoja ortopedske hirurgije i traumatologije u Novom Sadu. Novi Sad: Društvo lekara Vojvodine; 1979.
- Mikić Ž. 'Srpska majka iz Škotske' - dr Elsi Inglis (1864-1917). Med Pregl. 2008;61:419-6.
- Dobanovački D, Mikić Ž, Vučković N. Istorijat Anglo-jugoslovenske dečje bolnice u Sremskoj Kamenici. Med Pregl. 2015;68:277-82.
- Dosen M, Vukadinović S. Functional results after application of total hip prosthesis. Med Pregl. 1973;26:69-77.
- Dosen M, Gusman D, Jovanović M. Antero-lateral access for subastragalar and metatarsal (triple) arthrodesis. Med Pregl. 1968;21:123-8.
- Dosen M, Krajcinović J. 2 cases of undiagnosed posterior shoulder dislocation. Med Pregl. 1969;22:367-70.
- Letić S. Fractures of head and neck of radius. Med Pregl. 1967;20:333-6.
- Letić S, Mikić Z. Contribution to the knowledge on ligament injuries of the knee-a case of O'Donoghue's "unhappy triad". Med Pregl. 1967;20:253-6.
- Mikić Z. Development of orthopedics and founding of the Clinic for Orthopedic Surgery and Traumatology in Novi Sad. Med Pregl. 1998;51:457-68.
- Krajcinović J, Krajcinović O. Bilateral total hip prosthesis replacement in a single procedure. Med Pregl. 1998;51:175-7.
- Krajcinović J. Biomechanics of the inner arch of the sole. Med Pregl. 1988;41:70-3.
- Krajcinović J, Cirić V. Surgical treatment of calcaneus fractures. Med Pregl. 1986;39:23-6.
- Avramov S, Janjić D, Somer T, Popović L, Kolak R, Zoricic D. The Institute of Surgery in Novi Sad as a trauma center-10 years' experience. Med Pregl. 1997;50:521-6.
- Ercegan G, Mikić Z, Krajcinović J, Somer T, Janjić D, Vučić D. Early functional and anatomic results after total condylar knee prosthesis implantation. Med Pregl. 1991;44:209-13.
- Savić D. Allotransplantation in orthopedic surgery. Med Pregl. 2012;65:189-90.
- Somer T, Milicić A, Lazetić A, Brankov M. Fracture of a transfixed intramedullary nail in a patient with pseudoarthrosis of the femoral diaphysis. Med Pregl. 1994;47:59-61.
- Milankov M, Obradović M, Vranješ M, Budinski Z. Bone-patellar tendon-bone graft preparation technique to increase cross-sectional area of the graft in anterior cruciate ligament reconstruction. Med Pregl. 2015;68:371-5.
- Vukadinović S, Stanić D. Ender nails in the therapy of transtrochanteric fractures. Med Pregl. 1984;37:161-3.

19. Savić D, Krajinović J, Jovanović A, Miličić A, Milankov M, Stanković M. Arthroplasty in the treatment of congenital anomalies of the hip in adults. *Med Pregl.* 1997;50:120-3.

20. Gojković Z. Implantation of the knee joint endoprosthesis. *Med Pregl.* 2015;68:367-9.

21. Somer T, Bokorov B, Vukadinović S, Tubić M, Brankov M. Radiographic diagnosis of acute injuries of the collateral ligaments of the knee joint. *Med Pregl.* 1987;40:281-5.

22. Ristic V, Ninković S, Harhaji V, Milankov M. Causes of anterior cruciate ligament injuries. *Med Pregl.* 2010;63:541-5.

23. Ristic V, Ninković S, Harhaji V, Stanković M, Savić D, Milankov M. Reconstruction of anterior cruciate ligament by using two different techniques. *Med Pregl.* 2010;63:845-50.

24. Ninković S, Avramov S, Harhaji V, Obradović M, Vranješ M, Milankov M. Influence of different levels of sports activities on the quality of life after the reconstruction of anterior cruciate ligament. *Med Pregl.* 2015;68:116-21.

25. Milankov M. Treatment of the first shoulder dislocation. *Med Pregl.* 2010;63:155-7.

26. Milankov M, Krajinović J, Banić B, Vukadinović S, Jovanović A, Miličić A, Savić D. The value of local administration of antibiotics in treatment of bone infections. *Med Pregl.* 1994;47:111-4.

27. Milankov M, Jovanović A, Miličić A, Somer T, Vukadinović S, Savić D. Evaluation of the usefulness of suction dra-

inage in the treatment of nonspecific bone infections monitored with C-reactive protein. *Med Pregl.* 1999;52:489-94.

28. Vukadinović S, Krajinović J, Secen S. Trochanteroliliac coaptation in the treatment of septic complications after alloarthroplasty of the hip. *Med Pregl.* 1986;39:373-7.

29. Vukadinović S. Factors which have an effect on infections in orthopedic surgery. *Med Pregl.* 1995;48:347-52.

30. Miličić A, Jovanović A, Milankov M, Savić D, Stanković M. Fractures of the spine in patients with ankylosing spondylitis. *Med Pregl.* 1995;48:429-31.

31. Miličić A, Jovanović A, Milankov M, Savić D, Stanković M. Etiopathogenic, diagnostic and therapeutic aspects of stress fractures. *Med Pregl.* 1995;48:319-22.

32. Mikić, Z. Three cases of injury on a combine used for harvesting Indian corn. *Med Pregl.* 1966;19:161-4.

33. Mikić Z, Somer T, Tubić M, Ercegan G. Enthesitis of the pisiform bone. *Med Pregl.* 1985;38:523-5.

34. Mikić Z. The gloves of love. *Med Pregl.* 2010;63:133-7.

35. Vukadinović S, Somer L, Mikić Z, Somer T, Ercegan G. Morphologic characteristics and static resistance of transplanted patellar ligaments after replacement of the cruciate ligaments in the knee--an experimental study in a dog. *Med Pregl.* 1993;46:406-12.

36. Vukadinović S, Mikić Z, Ercegan G, Somer T. Anatomic characteristics of the knee joint in dogs. *Med Pregl.* 1984;37:209-14.

Rad je primljen 2. 11. 2016.

Recenziran 10. 12. 2016.

Prihvaćen za štampu 16. 12. 2016.

BIBLID.0025-8105:(2016):LXIX:Suppl 1:7-9.



Medical and non-medical staff employed at the Department of Orthopedic Surgery and Traumatology,
Clinical Center of Vojvodina, Novi Sad
Svi zaposleni Klinike za ortopedsku hirurgiju i traumatologiju Kliničkog centra Vojvodine Novi Sad

SURGICAL TREATMENT OF UNSTABLE PELVIC RING INJURIES*OPERATIVNI TRETMAN NESTABILNIH POVREDA KARLIČNOG PRSTENA***Vladimir HARHAJI^{1,2}, Srđan NINKOVIĆ^{1,2}, Predrag RAŠOVIĆ^{1,2}, Ivica LALIĆ^{1,2},
Merhan SALABAT² and Miodrag VRANJEŠ^{1,2}****Summary**

Introduction. Unstable pelvic ring injuries are among the most serious injuries of skeletal system. As they are often associated with young age and multiple organ injuries they are difficult for management. **Material and Methods.** This study included 26 unstable pelvic ring injuries surgically treated at the Department of Orthopedic Surgery and Traumatology from August 2008 until August 2015. The average age of 22 males and 4 female patients was 45.4 years. The most common mechanism for injury was a traffic accident (19), fall from height (6), and one patient was buried under rubble. Out of 26 patients who were operated, 24 had type C injury and two had type B injury according to Tiles classification. The average follow-up time was 23 months (8 – 84 months). The functional outcome was assessed by means of Majeed and Iowa Pelvic Score. **Results.** Pelvic ring injuries were healed in all 26 patients. A leg length discrepancy was found in 13 patients and it was 9 mm on average. Four patients reported using walking stick, and 5 out of 26 had sexual dysfunction. Majeed score was 72.1 on average (23 to 100), and Iowa Pelvic Score was 76.5 (38 to 100). **Conclusion.** Unstable pelvic ring injuries are difficult to be surgically treated. When these injuries are treated adequately and timely, good results can be expected. Average scores achieved by our patients are very good for both scales.

Key words: Pelvic Bones; Fractures, Bone; Fracture Fixation, Internal; Treatment Outcome; Disability Evaluation; Pain Measurement

Introduction

Pelvic ring injuries with its complicated three-dimensional osseous anatomy and close relation to all neuro-vascular structures for lower extremities are challenging for treatment. As a result of high energy trauma, they are often associated with other organs and system injuries. Since their prevalence is 20 – 37 per 100.000 people, they are not common [1]. Pelvic ring injury accounted for 20% of injuries in polytraumatized patients thus having vast influence on high morbidity and mortality [2]. The aim of this study was to report the functional outcome of first 26 unstable pelvic ring injuries surgically treated at the Department of Orthopedic Surgery and Traumatology in Novi Sad.

Sažetak

Uvod. Nestabilne povrede karličnog prstena spadaju u najteže povrede lokomotornog aparata. One su komplikovane za zbrinjavanje i često udružene sa povredama drugih organa. **Materijal i metode.** Analizirali smo 26 nestabilnih povreda karličnog prstena koje su operativno lečene na Klinici za ortopedsku hirurgiju i traumatologiju od avgusta 2008. do avgusta 2015. godine. Prosečna starost 22 muškarca i četiri žene, uključenih u ovo ispitivanje, bila je 45,4 godine. Najveći broj pacijenata povređen je u saobraćajnoj nezgodi (19), prilikom pada sa visine (6), dok je jedan pacijent povredu karličnog prstena zadobio prilikom zatrpavanja. Svih 26 pacijenata su operisani, 24 zbog povrede tipa C, a dva zbog povrede karličnog prstena tipa B po Tileu. Prosečno vreme praćenja bilo je 23 meseca (8–84 meseca). Za procenu funkcionalnog ishoda koristili smo *Majeed* i *Iowa Pelvic Score* skale. **Rezultati.** Sve povrede karličnog prstena bile su sanirane. Kod 13 pacijenata postojala je razlika u dužini nogu koja je prosečno iznosila 9 mm. Četiri pacijenta su koristila štap pri hodu, dok je petoro prijavilo probleme sa seksualnom funkcijom. Prosečan skor prema *Majeed* skali iznosio je 72,1 (od 23 do 100), dok je prema *Iowa Pelvic* bodovnoj skali prosečno postignuto 76,5 bodova (38–100). **Zaključak.** Nestabilne povrede karličnog prstena su zahtevne za zbrinjavanje operativnim putem. Ukoliko se tretiraju na adekvatan način i pravovremeno, može se očekivati dobar postoperativni funkcionalni rezultat. Na našem uzorku prosečne vrednosti obe primenjene bodovne skale spadaju u vrlo dobre.

KLjučne reči: karlične kosti; prelomi kosti; unutrašnja fiksacija preloma; ishod lečenja; procena nesposobnosti

Material and Methods

Unstable pelvic ring injuries were surgically treated in 26 patients in the period from August 2008 to January 2015. They were classified according to Marvin Tiles classification (**Table 1**) [3]. There were 24 males and 4 female patients (**Figure 1**). The youngest and the oldest patient were 22 and 74 years old, respectively. The average age was 45.4 years. Majority of our patients were injured in a motor vehicle accident (19), fall from height (6), and one patient was buried under rubble. Only one patient was operated on the day of injury, and one 20 days after trauma. On average, the patients were operated 7.8 days after getting injured. All injuries were stabilized with the external fixator, plates and screws,

Abbreviations

IPS – Iowa Pelvic Score
SI – sacroiliac

or just screws, or a combination of these. **Table 2** shows the fixation techniques applied in our patients. According to our protocol early mobilization and rehabilitation started on the first postoperative day with the passive range of motion of hip and knee on the injured side and muscle strength exercises. The patients were also encouraged to walk with crutches without weight bearing on the first postoperative day.

The average follow-up time was 23 months (8 – 84 months). The functional outcome was assessed by Majeed [4] and Iowa Pelvic Score [5].

Results

All pelvic ring injuries were healed.

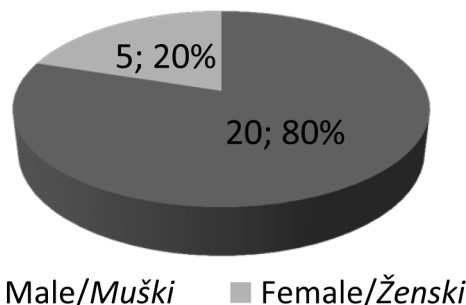
The average Majeed score was 72.1 (ranging from 23 to 100) which is considered a good clinical grade. Pain is the most common residual problem after pelvic ring injuries. Most of patients in these series had slight or mild pain, and only one had intense pain associated with activity. The average score for pain was 22 points. Ideally, all patients return to their pre-injury job and level activities. According to the results of this study most patients were able to get back to their job but the average working score was 15 points. None of the patients felt pain in sitting position. Of five patients who had a sexual intercourse issue, three complained that it was uncomfortable and two said it was even painful if prolonged, the average score being 3.7 points. Four patients were using one stick while walking. The average section five Majeed score was 11.7. Most of our patients had some degree of limp, scoring 8.7 points on average. Walking distance was limited for most patients (7.8 points on average).

The average Iowa Pelvic Score was 76.5, ranging from 38 to 100. IPS (Iowa Pelvic Score) has two major sections: activities of daily living (20 out of 100 points) and individual score (80 out of 100 points). When asked various questions, our patients replied they could perform most of activities of daily living with 15.5 points on average. The lowest score for pain and limp was recorded in the second section “Individual score”, being 71 points on average.

Discussion

There were some attempts at surgical treatment of unstable pelvic ring injuries in previous decades which were not standard of care at that time at the Department of Orthopedic Surgery and Traumatology.

Sex structure / Polna struktura



Graph 1. Sex structure

Grafikon 1. Polna struktura

Internal fixation of unstable pelvic ring injuries became standard of care in 2008, and since then it has been applied in these 26 patients included in our study. Benefits of surgical treatment of these injuries are undisputable as stated by Marvin Tile [6]. He pointed out that internal fixation could prevent instability and malunion of pelvic ring and also result in lower incidence of complications such as deep vein thrombosis, pneumonia, urinary infections, decubitus ulcers etc. Because of biomechanical studies more trauma surgeons believe that unstable ring injuries must be fixed internally [7, 8].

In our study, the most common mechanism of injury was a motor vehicle accident – 69%. Van Loon et al. found that 94.8% of patients with open book pelvic lesion were injured in a car accident [9]. Many others have found that car accidents are the most frequent injury patterns for pelvic ring [10–12].

Pain is the most common residual symptom after internal stabilization of pelvic fractures. That is the reason why Majeed and authors of Iowa Pelvic Score included pain in both scoring systems and allocated the most points for pain [4, 5]. Routt et al. suggest minimally invasive percutaneous screw fixation for rapid relief of pain [13]. Borg et al. agree with Majeed's conclusion that pain has the most important role in determining the functional outcome after pelvic ring injury fixation [14].

One of the most frustrating difficulties after pelvic ring injury and internal stabilization is sexual dysfunction. Sexual intercourse is made very difficult for male patients due to the pain felt across the pubic symphysis or SI (sacroiliac) joints, depending on fracture pattern [4]. Kellam et al. report that women usually complain of dyspareunia after lateral compression injuries [15]. Oliver et al. found that 31% of female patients from their study sample had dyspareunia but this did not

Table 1. Injury classification

Tabela 1. Klasifikacija povreda

	B1	C1	C2	C3
No of patients/Broj pacijenata	1	14	9	1

Table 2. Fixation techniques
Tabela 2. Tehnike stabilizacije

Type of fixation/ <i>Tip stabilizacije</i>	Patients <i>Pacijent</i>	(%)
Symphyseal plate/ <i>Ploča za simfizu</i>	1	4
External fixator/ <i>Spoljašnji fiksator</i>	3	12
SI screws/ <i>SI zavrtnjevi</i>	3	12
Posterior plate/ <i>Ploča pozadi</i>	3	12
Symphyseal plate + posterior plate/ <i>Ploča za simfizu + ploča pozadi</i>	2	8
Symphyseal plate + SI screws/ <i>Ploča za simfizu + SI zavrtnjevi</i>	7	28
Symphyseal plate + anterior plate + SI screws/ <i>Ploča za simfizu + ploča napred + SI zavrtnjevi</i>	1	4
Anterior plate + posterior plate/ <i>Ploča napred + ploča pozadi</i>	3	12
SI screws + external fixator/ <i>SI zavrtnjevi + spoljašnji fiksator</i>	1	4
SI screws + anterior plate/ <i>SI zavrtnjevi + ploča napred</i>	1	4

affect the ability to have an orgasm [11]. Five of our patients (19.2%) reported sexual dysfunction.

Van Loon et al. reported excellent Majeed score of 95.7 points in their study. Asci et al. also reported excellent functional outcome of 93.3 points per Majeed scale, with minimal score of 72 and maximal of 100 [16]. Milenkovic et al. had eleven patients (57.9%) with excellent and eight (42.1%) with good results [17]. In our series of first 26 patients the average Majeed score was 72.1. If three patients with the lowest score were excluded, the average score would increase to 87.8 points.

Van Loon also analyzed his patients with Iowa Pelvic Score. The lowest result was 82, and highest 90, the average score being 86 points. In the study of Salari et al., 72 patients were treated with percutaneous screw stabilization of SI joint [18]. All patients were asymptomatic and the mean IPS was 95 (SD 5.5). Ayvaz et al. reported in their article the average IPS to be 86 (range 82–90), with eleven excellent and nine good

IPS scores [19]. The average Iowa Pelvic Score in our patients was 74.9, the lowest score being 60 and maximal 100 points in two patients [19].

Conclusion

Unstable pelvic ring injuries need to be anatomically reduced and internally fixed to achieve good and excellent functional outcome. The surgical treatment is not without complications. However, conservative treatment leads to malunions, gross disability and dependence on other people. The long-term outcome of non-surgical treatment of pelvic ring fractures is connected with even bigger problems because of gait disturbance, vertebral column secondary deformity and a lot of pain. Because of the possibility of percutaneous fixation of fractured pelvic ring in majority of cases, non-surgical treatment should not be taken into consideration.

References

- Gansslen A, Pohlemann T, Paul Ch, Lobenhoffer Ph, Tscherner H. Epidemiology of pelvic ring injuries. *Injury*. 1996;27 Suppl 1:S-A13-20.
- Matewski D, Szymkowiak E, Bilinski P. Analysis of management of patient with multiple injuries of the locomotor system. *Int Orthop*. 2008;32(6):753-8.
- Tile M. Acute pelvic fractures: I. causation and classification. *J Am Acad Orthop Surg*. 1996;4:143-51.
- Majeed SA. Grading the outcome of pelvic fractures. *J Bone Joint Surg Br*. 1989;71(2):304-6.
- Nepola JV, Trenhaile SW, Miranda MA, Butterfield SL, Fredericks DC, Riemer BL. Vertical shear injuries: is there a relationship between residual displacement and functional outcome? *J Trauma*. 1999;46(6):1024-9.
- Tile M. Pelvic ring fractures: should they be fixed? *J Bone Joint Surg Br*. 1988;70:1-12.
- Leung KS, Chien P, Shen WY. Operative treatment of unstable pelvic fractures. *Injury*. 1992;23:31-7.
- Ward EF, Tomasin J, Vander-Griend RA. Open reduction and internal fixation of vertical shear pelvic fractures. *J Trauma*. 1987;27(3):291-5.
- Van Loon P, Kuhn S, Hofmann A, Hessmann MH, Rommens PM. Radiological analysis, operative management and functional outcome of open book pelvic lesions: a 13-year cohort study. *Injury*. 2011;42(10):1012-9.
- Korovessis P, Baikousis A, Stamatakis M, Katonis P. Medium and long-term results of open reduction and internal fixation for unstable pelvic ring fractures. *Orthopedics*. 2000;23(11):1165-71.
- Oliver CW, Twaddle B, Agel J, Routt ML Jr. Outcome after pelvic ring fractures: evaluation using the medical outcomes short form SF-36. *Injury*. 1996;27(9):635-41.
- Harvey-Kelly KF, Kanakaris NK, Obakponovwe O, West RM, Giannoudis PV. Quality of life and sexual function after traumatic pelvic fracture. *J Orthop Trauma*. 2014;28(1):28-35.
- Routt ML Jr, Simonian PT, Grujic L. The retrograde medullary superior pubic ramus screw for treatment of anterior pelvic ring disruptions: a new technique. *J Orthop Trauma*. 1995;9:35-44.
- Borg T, Hernefalk B, Carlsson M, Larsson S. Development of pelvic discomfort index to evaluate outcome following fixation for pelvic ring injury. *J Orthop Surg (Hong Kong)*. 2015;32(2):146-9.

15. Kellam JF, McMurty RY, Paley D, Tile M. The unstable pelvic fracture: operative treatment. *Orthop Clin North Am.* 1987;18:25-41.

16. Asci R, Sarikaya S, Buyukalpelli R, Saylik A, Yilmaz AF, Yildiz S. Voiding and sexual dysfunctions after pelvic fracture urethral injuries treated with either initial cystostomy and delayed urethroplasty or immediate primary urethral realignment. *Scand J Urol Nephrol.* 1999;33(4):228-33.

17. Milenkovic S, Mitkovic M, Saveski J, Micic I, Mitkovic M, Stamenic S. Surgical treatment of the unstable type C pelvic injury. *Acta Chir Iugosl.* 2013;60(2):53-8.

Rad je primljen 2. 11. 2016.

Recenziran 10. 12. 2016.

Prihvaćen za štampu 16. 12. 2016.

BIBLID.0025-8105:(2016):LXIX:Suppl 1:11-14.

18. Salari P, Cannada LK, Moed BR. Do asymptomatic patients have normal function after percutaneous fixation of the posterior pelvic ring? A case-control pilot study. *J Orthop Surg Res.* 2015;10:68.

19. Ayvaz M, Caglar O, Yilmaz G, Guvendik GI, Acaroglu RE. Long-term outcome and quality of life of patients with unstable pelvic fractures treated by closed reduction and percutaneous fixation. *Turkish journal of trauma and emergency surgery.* 2011;17(3):261-6.

Clinical Center of Vojvodina, Novi Sad
Department of Orthopedic Surgery and Traumatology¹
University of Novi Sad, Faculty of Medicine²

UDK 616.711-001-089.84
DOI: 10.2298/MPNS16S1015S

SHORT VS LONG POSTERIOR FIXATION OF THORACOLUMBAR SPINE INJURIES

KRATKA NASUPROT DUGOJ POSTERIORNOJ FIKSACIJI POVREDA TORAKOLUMBALNE KIČME

Milan STANKOVIĆ^{1,2}, Nataša JANJIĆ^{1,2}, Ivica LALIĆ^{1,2}, Nemanja GVOZDENOVIĆ^{1,2}, Igor ELEZ¹
and Miodrag VRANJEŠ^{1,2}

Summary

Introduction. More than a quarter of total number of posterior fixations of thoracolumbar spine is unsuccessful. **Material and methods.** The aim is to compare short and long fixation of thoracolumbar spine injuries. During the period of 2006 to 2015 we examined 99 patients at the Department of Orthopedic Surgery and Traumatology of Clinical Center of Vojvodina. Short fixation was performed in 63 cases and long fixation in 36 cases. All patients underwent clinical, radiographic and neurological evaluation. Mean age in the short fixation group was 47 (18-66) and in the long fixation group it was 43 (17-70). Mean follow-up time was 4,5 years. **Results.** Implants were extracted in 14 cases of short and in 4 cases of long fixation. Collapse of anterior part of vertebral body developed in 28,45% in the short fixation group and in 22,43% in the long fixation group whereas angulation value was 10,2° and 12,3° respectively. Mean low back outcome scale value was 61 points in the short fixation group and 50 in the long fixation group. There were 22 patients with neurological deficit. Full recovery was recorded in 8 patients (36,4%) of the short fixation group and in 17 patients (22,7%) of the long fixation group. Complications developed in 15 patients (23,8%) of the short fixation group and 11 (30,6%) of the long fixation group. **Conclusion.** Short fixation is biomechanically weaker but provides a better functional recovery than long fixation.

Key words: Lumbar Vertebrae; Thoracic Vertebrae; Spinal Fractures; Orthopedic Fixation Devices; Treatment Outcome; Fracture Fixation, Internal

Introduction

Spine injuries are frequent. The outcome of the treatment of unstable thoracolumbar spine injuries is often uncertain and depends on many factors, mainly on final neurological status of the patient, pain severity, degree of correction of traumatic spine deformity and complications. Surgical approach and ways of fixation of these injuries are still controversial [1]. Posterior transpedicular fixation has become increasingly popular during the past several years. The short posterior fixation [2] is stabilization of the injured vertebra together with the adjacent upper and lower vertebrae and the long posterior fixation is stabilization of the injured vertebrae together with two adjacent

Sažetak

Uvod. Više od četvrtine zadnjih fiksacija povreda torakolumbalne kičme je neuspešno. **Materijal i metode.** Cilj rada bio je uporediti kratku i dugu fiksaciju povreda torakolumbalne kičme. U periodu 2006–2015. na Klinici za ortopediju Kliničkog centra Vojvodine ispitivano je 99 pacijenata. U 63 slučaja činjena je kratka fiksacija, a kod 36 pacijenta duga. Pacijenti su ispitivani klinički, radiografski i neurološki. Prosečna starost u grupi kratka fiksacija bila je 47 godina (18–66), a u grupi duge fiksacije 43 (17–70). Vreme praćenja prosečno je bilo 4,5 godine. **Rezultati.** Implantat je izvađen u 14 slučajeva kod kratke i kod četiri pacijenta iz grupe pacijenata kojima je urađena duga fiksacija. Kolabiranje prednje strane tela pršljena kod kratke fiksacije bilo je 28,45%, a kod duge 22,43%, dok je angulacija iznosila 10,20, odnosno 12,30. Prosečna vrednost *low back outcome scale* bila je kod kratke fiksacije 61 poen, a kod duge 50. Od 22 pacijenata sa neurološkim ispadom, u grupi kratke fiksacije oporavilo se njih 8(36,4%), a u grupi u kojoj je urađena duga fiksacija, od njih 17 (22,7%) oporavilo se 7 (41,1%). Komplikacije su viđene kod 15 pacijenata (23,8%) grupe kojoj je urađena kratka fiksacija i 11 iz grupe kojoj je urađena duga fiksacija (30,6%). **Zaključak.** Kratka fiksacija je biomehanički slabija, ali daje bolji funkcionalni oporavak od duge fiksacije. **Glavne reči:** lumbalni pršljenovi; grudni pršljenovi; prelom kičme; uređaji za ortopedsku fiksaciju; ishod lečenja; unutrašnja fiksacija preloma

upper and two lower vertebrae. About a quarter of total number of posterior fixations turns out to be a failure regarding the degree of deformity correction, stability of construction and related complications [3]. The short fixation leads to lesser muscle trauma and lesser number of “stiffened” segments of the spine which should lead to a better functional result but it is shown over a long period of time that this weaker construction leads to a recurrent deformity [4]. Therefore it is necessary to compare long and short fixation from several aspects so that a surgeon can decide which way of stabilization should be used in individual cases.

The aim of this study is to analyze functional, radiographic and neurological results of posterior

Abbreviations

SF	– short fixation
LF	– long fixation
t	– t test
AD ⁰ in	– angular deformity initially
AD ⁰ k	– angular deformity control
B _x in %	– the collapse of the anterior wall of the vertebral body initially
B _x k %	– the collapse of the anterior wall of the vertebral body control
LBOS	– low back outcome scale
χ^2	– Chi-square test
$\chi^2 > \chi^2_{\alpha}$	– the ratio of the value of the Chi-square test for short and long fixation

fixation of these injuries and to compare short and long fixation.

Material and Methods

During the period from 2006 to 2015 at the Department of Orthopedic Surgery and Traumatology, and at the Emergency Department of the Clinical Centre of Vojvodina 175 patients with spinal injury were operated. There were 147 patients with thoracolumbar spine injury, 18 of them died, 30 of them did not come to checkups so we analyzed 99 of them. Short fixation was performed in 63 cases of unstable thoracolumbar spine injury and long posterior transpedicular stabilization was performed in 36 patients.

There were 74 (75%) male and 25 (25%) female participants. Mean age was 47 years (ranging from 18 to 66) and 43 years (ranging from 17 to -70) in the group with short fixation and in the group with long fixation, respectively. The oldest and the youngest patient was 70 and 17 years old, respectively. The patients underwent clinical, radiographic and neurological examination. Standard native radiographies and computed tomography (CT) were used.

The most frequently injured vertebra was L1 (34 cases) followed by Th12 (25 cases), L2 (14 patients) and Th11 (11 cases). The lower lumbar spine, levels L3-L5, was injured in 8 cases and the medial and upper thoracic spine, levels Th1-Th10 in 7 cases. The most frequent injuries were unstable burst fractures Magerl type "A3" [5] in 69 cases, type "A2" in 12 cases, "B1" in 10 cases and types "B2" and "C" in 4 cases each.

Radiographic analysis consisted of angle measurement of local angulation using Cobb's method and calculation of percentage of collapse of the anterior side of vertebral body at the checkup [6]. We took mean value of anterior height of two adjacent vertebrae as the initial value of the vertebral height before the injury (**Scheme 1**).

Neurological evaluation and follow-up were performed using Frankel's score system [7]. Neurological impairment was observed in 39 patients (39.4%), i.e. in 17 patients (47.2%) from the group with long fixation and in 22 patients (34.9%) from the group with short fixation. Complete paralysis (Frankel "A") was noted in 5 (7.9%) cases in the group with short fixation and in 4 (11.1%) cases in

the group with long fixation while an incomplete neurological deficit (Frankel "B" – "D") was noted in 17 (27%) cases in the group with short fixation and in 13 (36.1%) cases in the group with long fixation.

The surgical procedure consisted of transpedicular stabilization of the injured level together with adjacent upper and lower vertebral levels. We displayed the posterior part of vertebrae to the transversal processes by using a standard posterior approach. Then we opened pedicles of the injured and the adjacent vertebrae through the known projection points on the small vertebral joints. We placed poliaxial screws through these openings. In cases with neurological deficit we performed posterior decompression – partial or complete laminectomy and extraction of bony fragments from the spinal canal until dural sac was completely free. Then we placed modified rods to the grooves at the screw' heads. We manipulated the rods to gain distraction and derotation along with the hyperextension of the injured level which led to the correction of deformity and indirect decompression of the spinal canal at the level of fracture and stenosis. Short fixation consisted of stabilization of the injured level together with one adjacent upper and lower levels and long fixation consisted of stabilization together with two adjacent upper and lower levels. Early postoperative mobilization of patients started the next day and consisted of turning to sides and performing active exercises for body and extremities. In cases with neurological deficit it consisted of turning to sides, gradual verticalization, breathing exercises and positioning of the legs in order to prevent flexion contractures of the joints.

Functional examination at checkups was performed by means of Low Back Outcome Scale (LBOS) score system [8]. Maximum result was 75 points. Functional result was graded as "excellent" (65-75 points), "good" (50-64 points), "satisfactory" (30-49 points) and "poor" (0-29 points). We also included pain intensity felt by the patient at the end of the treatment and it was evaluated by the pain intensity scale – 0 points – no pain, 3 points – weak pain, 6 points – medium pain, 9 points – severe pain. After discharge from the hospital the physical treatment was performed at some of the specialized rehabilitation centers. Mean follow-up time was 4.5 years (2-8).

Results

Average final collapse of the anterior part of vertebral body was 42.25% in cases with short fixation and 32.45% with long fixation, that being statistically significant ($t=2.35$ $p<0.05$) while final angulation was 10.2° in the group with short fixation and 12.3° in the group with long fixation ($t=0.77$ $p>0.05$).

Average value of LBOS – the scale of functional capacity was 61 points (good) in cases with short fixation and 50 points (good) in cases with long fixation. Zero hypothesis is that distributions of frequencies of LBOS points of short and long fixations χ^2 i χ^2_{α} are equal. \bar{X}_{sr} long=1.77, \bar{x}_{sr} short=1.07; $\chi^2=48.75$; $r=3$;

Table 1. Radiographic and functional parameters and complications caused by the implants
Tabela 1. Radiografski i funkcionalni parametri i komplikacije vezane za implantat

	AD ⁰ in	AD ⁰ K	t	B _x in %	B _x K %	t	LBOS	χ^2	$\chi^2 > \chi^2_{\alpha}$	Implant migration	Implant extraction
							point/ bod			Pomeranje im- plantata (%)	Vađenje implanta- ta (%)
SF	18,6	10,2	0,77	51,4	42,2	2,4	61	48,75		24	22
LF	21,7	12,3	(p>0,05)	54,8	32,5	(p<0,05)	50	3,841	(p<0,05)	20	11

Legend:

SF- short fixation/*kratka fiksacija*, LF - long fixation/*duga fiksacija*, t - t test, AD⁰ in - angular deformity initially/*lokalna angulacija inicijalno*, AD⁰ k - angular deformity control/*lokalna angulacija kontrola*, B_x in % - the collapse of the anterior wall of the vertebral body initially/*kolaps prednjeg dela tela pršljena inicijalno*, B_x k % - the collapse of the anterior wall of the vertebral body control/*kolaps prednjeg dela tela pršljena kontrola*, LBOS - low back outcome scale/*ishoda skala donjeg dela leđa*, χ^2 - Chi-square test/*Hi-kvadrat test*, $\chi^2 > \chi^2_{\alpha}$ - the ratio of the value of the Chi-square test for short and long fixation/*odnos hi-kvadrat testova kratke i duge fiksacije*

I=1 for binomial distribution, k= 1; $\alpha=0.05$; $\chi^2_{\alpha}=3,841$. As $\chi^2 > \chi^2_{\alpha}$ we reject the zero hypothesis with the risk α and conclude that the differences between frequencies distribution are significant.

Implant fracture and migration was noted at checkups in 29 cases (46%) in the group with short fixation and in 11 cases (30.5%) in the group with long fixation. There was a statistical significance between the groups regarding this parameter (p<0,05). Implants were removed in 14 cases (22.2%) with short and in 4 cases (11.1%) with long fixation. Radiographic and functional results as well as complications related to implants are displayed in **Table 1**.

Eight (36.4%) out of 22 patients from the group with short fixation and 7 out of 17 patients from the group with long fixation (41.1%) recovered from neurological deficit. Neurological recovery was observed only in subgroups with partial neurological deficit ("B", "C", "D"). Eight (44%) out of 17 patients in the group with short fixation and 7 (53.9%) of 13 patients from the group with long fixation with initial neurological status Frankel "B", "C" and "D" recovered from partial neurological deficit. Neurological status of patients is given in **Table 2**.

Complications were present in 15 patients (23.8%) in the group with short fixation and in 11 patients in the group with long fixation (30.6%). The most frequent complication was urinary infection with positive bacterial culture during the observation period and it was noted in 12 patients (12%) from the group with short fixation and 8 patients (22.2%) from the group with long fixation. All patients had severe neurolo-

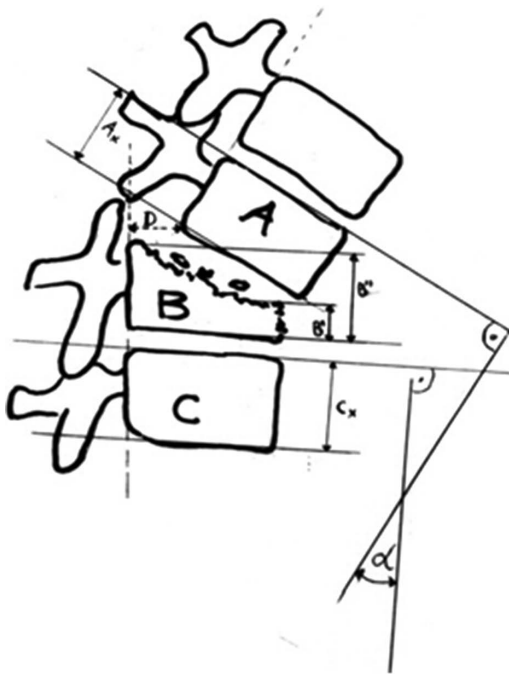
gical deficit (Frankel "B", "C" and "D"). Pneumonia was noted in 4 patients (6.32%) in the group with short fixation and in 3 patients (8.34%) in the group with long fixation. Deep wound infection occurred in one patient (1.58%) from the group with short fixation and in 2 patients (5.6%) in the group with long fixation. Infection was treated by local tissue debridement, irrigation and antibiotics with the removal of the implants (**Graph 1**).

Discussion

In this study we noticed a higher percentage of implant fracture and migration in the group with short fixation (24% compared to 20% in the other group) as well as a higher percentage of the need for implant extraction (22% compared to 11% in the group with long fixation). Farrokhi et al. [9] compared complications caused by transpedicular implants in short fixation. The results showed that these complications occurred in 21.4% of cases in the group with bridging of the fracture level and in only 5.26% in the group where the broken vertebra was included into the instrumentation. In most cases in our study we performed vertebral fixation with bridging the injured vertebra, those are the "A3" types of injuries with fracture of the base or the pedicle itself within crushing the vertebra so our results are similar to the results of the „bridging“ subgroup in Farrokhi's study. Jutte and Castelein [10] noticed complications related to implants in more than 50% of the cases of total of 105 transpedicular instrumentations. They

Table 2. Neurological evaluation**Tabela 2.** Neurološka evaluacija

Frankel Initially <i>Frankel Početno</i>	Frankel final - short fixation <i>Frenkel finalno - kratka fiksacija</i>					Frankel final - long fixation <i>Frenkel finalno - duga fiksacija</i>				
	A	B	C	D	E	A	B	C	D	E
A	5					4				
B		2	1				2	1	1	
C			4	3				1	3	
D				3	4				3	2
E					41					19



Scheme 1. Calculation of radiographic parameters on an X-ray

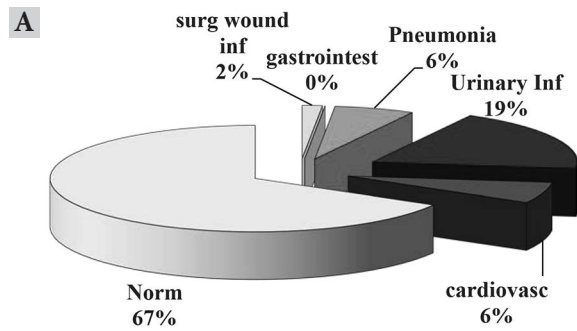
Šema 1. Merenje i izračunavanje radiografskih parametara na rendgenskom snimku

- α – angle of local angulation/*ugao lokalne angulacije*
- B^{II} – anterior height of the vertebral body prior to fracture/*prednja visina tela pre povređivanja*
- $B^{II}=(Ax + Cx):2 \cdot 100\%$
- B^I – measured anterior height of the fracture vertebral body/*izmerena visina prednjeg dela tela prelomljenog pršljena*
- B_x – percentage of reduction of the anterior part of fractured vertebra $B_x\%=(B^{II}-B^I)/B^{II} \cdot 100\%$ /*procenat smanjenja prednje visine tela slomljenog pršljena $B_x\%=(B^{II}-B^I)/B^{II} \cdot 100\%$*
- Ax – anterior height of the upper adjacent vertebral body/*prednja visina tela susednog višeg pršljena*
- Cx – anterior height of the lower adjacent vertebral body/*prednja visina tela susednog nižeg pršljena*
- D – translation/*translacija*

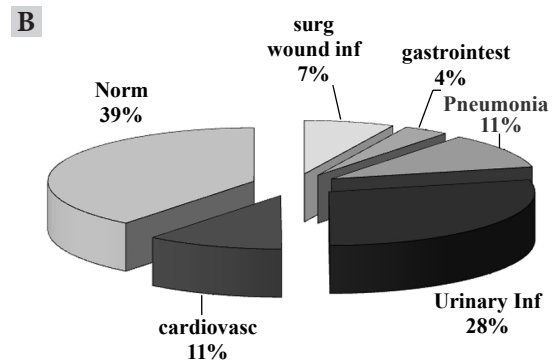
considered a complication every position of the implant which was not the ideal position. They noticed an implant fracture in 12.4% of the cases, which was less than in our study. The same authors removed the instrumentation in 10% of the case, that being half of the frequency in our study. We presume that one of the reasons of our poorer results compared to Jutte’s study is that we often performed the instrumentation with technical inaccuracy.

We also noticed that the final collapse of the body of the injured vertebra in patients treated with short stabilization (25%) was 10% larger compared to treatment with long fixation (32.34%). Vertebral body collapse occurred regularly after burst fractures. In those cases, due to crushing of the vertebral body there was no anterior part of the vertebra so the patient’s weight bent the implant during the

process of verticalization [11]. We, as well as other authors [12], have noticed that when the patient’s weight above the fracture level is transferred to only one pair of transpedicular screws without the support of the anterior part of the vertebral body, the instrumentation suffers much larger load than in cases when the weight is distributed to more screws which are placed proximally. The difference between the groups of patients can be explained to a certain extent by the difference in age. The Patients from the short fixation group were 4 years older on average than in the long fixation group. In older patients bones are weaker so the fixation of transpedicular screws is weaker [13]. Guven et al. [14] noticed the collapse of the fractured thoracolumbar vertebrae treated with short and long transpedicular fixation in 16.4% and 10.6%, respectively and Tezeren [15] in 15% and 8%, respectively. Our results are significantly poorer (42.2% and 32%) although according to this parameter in our study the long fixation is significantly more efficient than the short fixation. A reason of this significant deviation of results may be that in our study we surgically treated so-called “A3” bursting fractures without grafting the anterior column of the vertebra in most cases while the aforementioned authors did not use this technique in



A. Short fixation
A. Kratka fiksacija



B. Long fixation
B. Duga fiksacija

Graph 1. Complications
Grafikon 1. Komplikacije

treatment of Magerl "A3" types of fractures. Besides, we cannot hide our technical errors during the instrumentation placement in some cases which is significant because instrumentation which is not done perfectly leads to vertebral body collapse as shown by some authors [16].

Güven et al. [14] noticed mean angulation of 8° and 7.2° in the groups with short and long fixation, respectively while we noticed 10.2° and 12.3° , respectively, in other words somewhat lower mean values and poorer result in the group with long fixation. The reason for this is that the starting values of angular deformity in the group with long fixation in our study were significantly higher than in the group with short fixation (18.6° short and 21.7° long fixation). On the other hand, Güven had completely homogeneous groups regarding this parameter in his study.

Tezeren et al. [14] noticed mean final values of angulation in 18 patients – 10° and 6° for short and long fixation, respectively so it can be concluded that the results were significantly better with long fixation. It is possible that these results are a consequence of a smaller group compared to our study, which included 99 patients. The loss of correction of the fractured vertebral body treated with transpedicular fixation cannot be avoided. In their earlier studies, Carl et al. [17] noticed recurrent kyphosis and collapse of almost 90% of the accomplished correction of burst fractures of the thoracolumbar spine while Louis [18] reported that the injured patients with corrected kyphosis and vertebral diameters developed recurrent deformity which could be up to 50% of the initial deformity. It needs to be stated that Louise used older types of instrumentation – neutralization plates and screws which are not tightly connected with them. Louise plates were widely used in pathology of vertebral column [19]. Alanay [20] examined two groups of patients treated with short transpedicular fixation with transpedicular grafting and without grafting. He managed to get correction of the deformity in about half of examined cases from both groups. These results are similar to ours. In a study done by a group of Korean authors [21], short and long posterior fusion of thoracic and lumbar vertebral fractures were compared after the Cotrel-Dubouset instrumentation. A higher percentage of successful fusion was accomplished in the group with short fusion although final collapse of broken vertebrae was 24% compared to 17% after long fusion. Final local angulation was also bigger in the group with short fusion than with long fusion (the mean difference was 5.7°) but the functional recovery at the end of the study was better.

We can draw a conclusion that short fixation is biomechanically weaker than long fixation.

The functional outcome represented by the LBOS scale in our study is significantly better in the patients treated with short fixation which is similar to the result obtained by Korean authors in their study.

In our study the mean value was 61 points in the group with short fixation and 50 in the group with long fixation. Tezeren [14] also used this scale for comparison of short and long fixation and got mean LBOS scale value of 61 points in the short fixation group and 63 points in the long fixation group. These are functional results which are significantly different in comparison with our study and that may be explained by the fact that we included the patients both without and with neurological deficit and Tezeren included only the patients without neurological deficit. The functional status is also affected by general surgical complications which we noted in significantly higher percentage in the long fixation group which was not the case in Tezeren's study. Besides that, the patients in Tezeren's study were younger (40 years old) while in our study they were 43 and 47 years old in the long and the short fixation group, respectively. It is known that younger patients regenerate their fun-

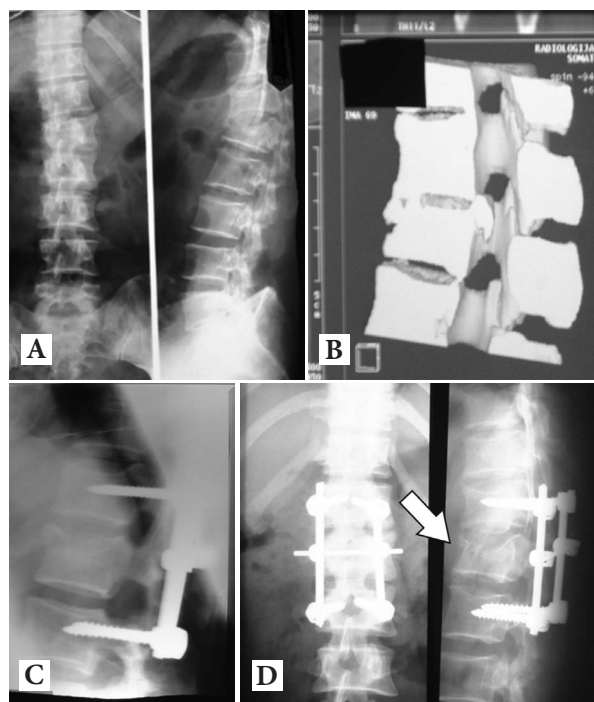


Figure 1. Short transpedicular fixation – the collapse of the body

Slika 1. Kratka transpedikularna fiksacija – kolaps tela

A: „burst“ fracture of the body L1 (arrow key), „burst“ prelom tela L1 (strelica)

B: CT of the fracture - retro-pulsion of the fragments and stenosis/CT snimak preloma - retropulzija fragmenata i stenozna

C: Postoperative status - the arrow is pointing restoration of vertebral body dimensions/Postoperativni status – strelica pokazuje restoraciju dimenzija tela pršljenja

D: Control anteroposterior and lateral X-ray - there was a collapse of the body to its original dimensions (arrow)/Kontrolni anteroposteriorni i profilni rendgenski snimak – došlo je do kolapsa tela do početnih dimenzija (strelica)

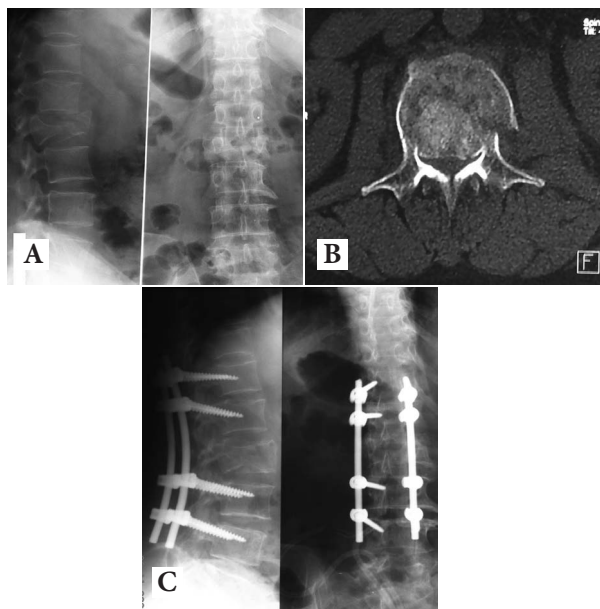


Figure 2. Long transpedicular fixation
Slika 2. Duga transpedikularna fiksacija

A: comminutive fracture L2 – initial X-ray/rasprskavajući prelom L2 – inicijalni RTG

B: axial CT - the display of size of the vertebral body comminution fracture and bilateral fractures of pedicle base/aksijalni CT – prikaz veličine rasprskavanja tela pršljena i prelomi baza oba pedikla

C: postoperative AP and lateral X-ray – transpedicular instrumentation placed to two levels above and two under the fracture/ postoperativni prednje-zadnji i bočni RTG – transpedikularna instrumentacija sa fiksacijom dva nivoa iznad i ispod nivoa preloma

ctional status more easily and more quickly than older patients. Wei et al. [22] also conducted functional research of the patients treated with short and monosegmental fixation of thoracolumbar spine. They found the mean LBOS scale value of 74.9 points in the group with monosegmental fixation, which is much better result than in our study, and 60.2 points in the group with short fixation, which is similar to our result. We can conclude that shorter fixation leads to a better functional recovery of patients. That “saves” more dynamic segments, allows more mobility of the spine which leads to better functional status of the spine as a whole [23]. Alanay [20] also conducted an examination of the functional status and pain. Functional result and pain was expressed by Likert’s scale (pain intensity graded from 0 to 10). The results were similar in both groups of patients – 7.0 points in the group where

transpedicular grafting was used and 7.2 in the group where grafting was not used. These results are somewhat poorer than ours.

Deep infection of surgical wound when treating spine trauma was recorded in about 4.7% of the cases in Jutta’s [10] study, which is similar to our results in the long fixation group (5.6%). In the short fixation group of our study a deep wound infection was recorded in just one patient (1.58%). The difference can be explained by shorter surgery time and lesser tissue trauma during the short fixation. Complications of transpedicular fixations of the thoracolumbar spine were examined also by Farrokhi et al [9]. The percentage of deep infection was 5.25% in the “including” group and 9.5% in the “bridging” group. “Including” means that fractured vertebra was also fixated through the pedicles and “bridging” means that that fractured vertebra was skipped. The results of Farrokhi are similar to our results. Guven [14] recorded one case of deep vein thrombosis. In our research the most frequent complication was urinary infection in both groups (in 19% and 28% of the patients from the short and long fixation group, respectively). It was recorded only in the patients who suffered neurological deficit and had a urinary catheter for a long time. Other frequent complications included pneumonia in four cases in the short (6%) and four cases in long fixation group (11%).

Neurological status of patients in both groups was better than the initial one. Better recovery was recorded in the long fixation group (36.4% short and 44% long fixation). The difference of neurological recovery was statistically significant in the subgroups of incomplete lesions (“B”, “C”, “D”), being better in long fixation (in 53.9% and 44% of the patients from the long and short fixation group, respectively). This difference can partially be explained by better and more stable reconstruction of the vertebral column by using long instrumentation which enables more aggressive early rehabilitation and also by a fact that partial neurological deficit was much more frequent in the long instrumentation group (36% long, 27% short). In other words patients with bigger neurological deficits were in the long fixation group. The size of neurological recovery was, on average, in both groups one Frankel grade which has also been reported by other authors [24].

Conclusion

Short fixation of the thoracolumbar spine fractures as biomechanically weaker allows recurrence of the traumatic deformation to a larger extent than long fixation but is less invasive and provides better functional result with fewer complications.

References

1. Cheng LM, Wang JJ, Zeng ZL, Zhu R, Yu Y, Li C, et al. Pedicle screw fixation for traumatic fractures of the thoracic and lumbar spine. *Cochrane Database Syst Rev.* 2013 May 31;(5):CD009073.
2. Dick W, Kluger P, Magerl F, Woerdorfer O, Zach G. A new device for internal fixation of thoracolumbar and lumbar

spine fractures: the ‘fixateur interne’. *Paraplegia.* 1985;23 (4):225-32.

3. Lonstein JE, Denis F, Perra JH, Pinto MR, Smith MD, Winter RB. Complications associated with pedicle screws. *J Bone Joint Surg Am.* 1999;81(11):1519-28.

4. Oda I, Abumi K, Yu BS, Sudo H, Minami A. Types of spinal instability that require interbody support in posterior lumbar reconstruction: an in vitro biomechanical investigation. *Spine (Phila Pa 1976)*. 2003;28(14):1573-80.
5. Magerl F, Aebi M, Gertzbein SD, Harms J, Nazarian S. A comprehensive classification of thoracic and lumbar injuries. *Eur Spine J*. 1994;3(4):184-201.
6. Kuklo T, Polly D, Owens B, Zeidman S, Chang A, Klemme W. Measurement of thoracic and lumbar fracture kyphosis: evaluation of intraobserver, interobserver, and technique variability. *Spine (Phila Pa 1976)*. 2001;26:61-5.
7. Frankel HL, Hancock B, Hyslop G, et al. The value of postural reduction in the initial management of closed injuries of the spine with paraplegia and tetraplegia. I Paraplegia. 1969;7(3):179-92.
8. Greenough CG, Fraser RD. Assessment of outcome in patients with low-back pain. *Spine (Phila Pa 1976)*. 1992;17(1):36-41.
9. Farrokhi MR, Razmkon A, Maghami Z, Nikoo Z. Inclusion of the fracture level in short segment fixation of thoracolumbar fractures. *Eur Spine J*. 2010;19(10):1651-6.
10. Jutte PC, Castelein RM. Complications of pedicle screws in lumbar and lumbosacral fusions in 105 consecutive primary operations. *Eur Spine J*. 2002;11:594-8.
11. Cunningham BW, Seftor JC, Shono V, McAfee PC. Static and cyclical biomechanical analysis of pedicle screw spinal constructs. *Spine (Phila Pa 1976)*. 1993;18:1677-88.
12. Korovessis P, Baikousis A, Deligianni D, Mysirlis Y, Soucacos P. Effectiveness of transfixation and length of instrumentation on titanium and stainless steel transpedicular spine implants. *J Spinal Disord*. 2001;14:109-17.
13. Defino HL, Vendrame JR. Role of cortical and cancellous bone of the vertebral pedicle in implant fixation. *Eur Spine J*. 2001;10:325-33.
14. Guven O, Kocaoglu B, Bezer M, Aydin N, Nalbantoglu U. The use of screw at the fracture level in the treatment of thoracolumbar burst fractures. *J Spinal Disord Tech*. 2009;22(6):417-21.
15. Tezeren G, Kuru I. Posterior fixation of thoracolumbar burst fracture: short-segment pedicle fixation versus long-segment instrumentation. *J Spinal Disord Tech*. 2005;18(6):485-8.
16. Kramer DL, Rodgers WB, Mansfield FL. Transpedicular instrumentation and short-segment fusion of thoracolumbar fractures: a prospective study using a single instrumentation system. *J Orthop Trauma*. 1995;9:499-506.
17. Carl AL, Tromanhauser SG, Roger DJ. Pedicle screw instrumentation for thoracolumbar burst fractures and fracture-dislocations. *Spine (Phila Pa 1976)*. 1992;17(8 Suppl):S317-24.
18. Louis CA, Gauthier VY, Louis RP. Posterior approach with Louis plates for fractures of the thoracolumbar and lumbar spine with and without neurologic deficits. *Spine (Phila Pa 1976)*. 1998;23(18):2030-40.
19. Miličić A, Jovanović A, Milankov M, Savić D, Stanković M. Frakture kičme u bolesnika s ankiloznim spondilitisom. *Med Pregl*. 1995;48(11-12):429-31.
20. Alanay A, Acaroglu E, Yazici M, Oznur A, Surat A. Short-segment pedicle instrumentation of thoracolumbar burst fractures: does transpedicular intracorporeal grafting prevent early failure? *Spine (Phila Pa 1976)*. 2001;26(2):213-7.
21. Moon MS, Choi WT, MoonYW, Kim YS, Moon JL. Stabilisation of fractured thoracic and lumbar spine with Cotrel-Dubousset instrument. *J Orth Surg (Hong Kong)*. 2003;11(1):59-66.
22. Wei FX, Liu SY, Liang CX, Li HM, Long HQ, Yu BS, et al. Transpedicular fixation in management of thoracolumbar burst fractures: monosegmental fixation versus short-segment instrumentation. *Spine (Phila Pa 1976)*. 2010;35(15):E714-20.
23. Boucher M, Bhandari M, Kwok D. Health-related quality of life after short segment instrumentation of lumbar burst fractures. *J Spinal Disord*. 2001;14:417-26.
24. Singhal B, Mohammed A, Samuel J, Mues J and Kluger P. Neurological outcome in surgically treated patients with incomplete closed traumatic cervical spinal cord injury *Spinal Cord* 2008;46:603-7.

Rad je primljen 2. 11. 2016.

Recenziran 10. 12. 2016.

Prihvaćen za štampu 16. 12. 2016.

BIBLID.0025-8105:(2016):LXIX:Suppl 1:15-21.



All doctors employed the Department of Orthopedic Surgery and Traumatology
Svi lekari Klinike za ortopedsku hirurgiju i traumatologiju

Clinical Center of Vojvodina, Novi Sad
Department of Orthopedic Surgery and Traumatology¹
University of Novi Sad, Faculty of Medicine²

UDK 616.71-001.5-089
DOI: 10.2298/MPNS16S1023L

ANALYSIS OF ILIZAROV APPARATUS APPLICATION IN ACUTE TRAUMATIC LESIONS AND TREATMENT OF COMPLICATIONS OF DIFFERENT PARTS OF MUSCULOSKELETAL SYSTEM AT THE DEPARTMENT OF ORTHOPEDIC SURGERY AND TRAUMATOLOGY IN NOVI SAD

ANALIZA PRIMENE APARATA PO ILIZAROVU KOD AKUTNIH POVREDA I KOMPLIKACIJA LEČENJA POJEDINIHIH SEGMENTA LOKOMOTORNOG SISTEMA NA KLINICI ZA ORTOPEDSKU HIRURGIJU I TRAUMATOLOGIJU U NOVOM SADU

**Ivica LALIĆ^{1,2}, Vladimir HARHAJI^{1,2}, Vaso KECOJEVIĆ¹, Srđan NINKOVIĆ^{1,2},
Oliver DULIĆ¹ and Predrag RAŠOVIĆ^{1,2}**

Summary

Introduction. For multiply traumatized or polytraumatized patients, the preservation of normal limb function with minimal complication is the highest priority. The supreme principle of the Ilizarov technique is to achieve limb stability with equality, without deformities, with sufficient muscle function and full range of joint movement with minimal risk of infection. It is also of great importance to decrease the length of immobility with the least possible number of surgical procedures. **Material and Methods.** We present a retrospective and partially prospective study with the analysis of the Ilizarov apparatus application for managing acute traumatic fractures, bone fracture complications and other orthopedic conditions eligible for treatment with this technique. This study covers our experiences and results gained in the period from 2003 to 2016. The analysis included a broad spectrum of orthopedic and traumatology conditions such as acute fractures, non-union fractures, malunion fractures, pseudoarthrosis, congenital and acquired bone deformities and the final treatment after total knee joint replacement failures. **Results.** After a long follow-up time, the long-term results were assessed by estimating the results of clinical examinations, X-ray evaluations, Association for the Study and Application of the Method of Ilizarov bone and functional scoring system and Karlstrom and Olerud functional scoring system evaluations. **Conclusion.** The introduction of the Ilizarov method at our Department 13 years ago has justified its application in everyday clinical practice by achieving excellent results in the treatment of the most complicated orthopedic and trauma conditions.

Key words: Ilizarov Technique; Treatment Outcome; Postoperative Complications; Orthopedic Fixation Devices; Fractures, Bone; Arthrodesis; Multiple Trauma; Pseudoarthrosis; Fractures, Malunited

Sažetak

Uvod. Kod pacijenata koji su doživeli višestruke prelome ili politraumu, očuvanje normalne funkcije ekstremiteta sa minimalnim komplikacijama najveći je prioritet. Uspostavljanje stabilnog ekstremiteta, jednake dužine, bez deformacije, sa dobrom mišićnom funkcijom, dobrom pokretljivošću zglobova i minimalnim rizikom od pojave infekcije predstavljaju principe koji su osnove primene ove tehnike. Takođe je bitno da vreme onesposobljenosti bude minimalno i da se uradi što manje hirurških postupaka. U većini slučajeva, spoljna fiksaciona tehnika Ilizarova omogućuje ostvarenje ovih principa. **Materijal i metode.** Predstavljamo retrospektivnu i delom prospektivnu studiju analize primene aparata po Ilizarovu u lečenju akutnih preloma, komplikacija preloma i drugih ortopedsko-traumatoloških stanja koja su rešavana ovom tehnikom. U analizi su korišćena zapažanja primene aparata na pojedinim segmentima lokomotornog sistema u periodu 2003–2016. godine. Analizom su obuhvaćena stanja lečenja akutnih preloma, nesraslih preloma, loše sraslih preloma, svih vrsta pseudoartroza, urođenih i stečenih deformiteta kostiju, artrodeza, kao i njegova primena kod neuspešnih totalnih artroplastika kolena. **Rezultati.** Dugogodišnjim praćenjem pacijenata i analizom dobijenih rezultata možemo sa sigurnošću reći da je primena ovog aparata u velikoj meri doprinela izlečenju pacijenata i smanjivanju procenta postoperativnih komplikacija. Procena rezultata lečenja na pojedinim segmentima vršena je kliničkim pregledima, radiografski, primenom koštanih i funkcionalnih skora *Association for the Study and Application of the Method of Ilizarov* i primenom *Karlstrom–Olerud* funkcionalnog bodovnog sistema. **Zaključak.** Uvođenje transosealne osteosinteze aparatom po Ilizarovu na Klinici za ortopedsku hirurgiju i traumatologiju u Novom Sadu, nakon trinaestogodišnjeg praćenja i analize, potpuno je opravdano jer rešava najsloženije prelome, komplikacije i ostala ortopedsko-traumatološka nezbrinuta stanja.

Ključne reči: tehnika po Ilizarovu; ishod lečenja; postoperativne komplikacije; uredaji za ortopedsku fiksaciju; prelomi kosti; artrodeze; politrauma; pseudoartroze; loše srasli prelomi

Abbreviations

AO	– Arbeitsgemeinschaft für Osteosynthesefragen
OTA	– Orthopaedic Trauma Association
MRI	– magnetic resonance imaging
CT	– computerised tomography
n	– number of patients
ASAMI	– Association for the Study and Application of the Method of Ilizarov
AOFAS	– American Orthopedic Foot and Ankle Society
ORIF	– open reduction and internal fixation
TKA	– total knee arthroplasty

Introduction

The Ilizarov method is an excellent alternative to more conventional methods in cases of severe wound contamination and in cases of soft tissue and bone loss [1]. The treatment of bone loss occurring as a result of acute trauma has traditionally been a complex surgical problem. In an attempt to avoid the problems associated with deficient graft materials and free tissue transfers, internal bone transport is a technique that has been a successful methodology for bony reconstruction for acute bone loss [2]. In addition, the Ilizarov fixator may achieve stability even in cases of bone comminution when internal fixation devices can do no better than tenuous fixation. Nonunion of long bones is often associated with a significant loss of function of affected extremity, joint stiffness, muscle atrophy, diffuse osteopenia, and even an extremity amputation or systemic manifestations in the case of infection. Indications for an appropriate treatment method are often unclear [3]. In complex nonunion, intramedullary nailing is preferred in delayed consolidation and hypertrophic nonunion without angular defects or hypometria, while the Ilizarov method is more often indicated in atrophic nonunion and in hypertrophic nonunion with hypometria and angular defects [4]. The ring frame supports and stabilizes the underlying bone by means of transfixion wires and half pins. The frame stability increases with the increasing wire diameter and tension, the use of more wires per ring, placing wires on opposite sides of the ring and inserting wires in different planes. Increasing crossing angles of wires to 90° provides maximal stability and crossing angles of less than 60° may allow the bone to slide along the wires requiring the use of opposing olive wires or the addition of a half pin. Olive wires provide an important buttress effect in the correction of angular deformity [5]. Ankle arthrodesis represent the most common surgical treatment as a definite solution for various diseases which lead to an ankle joint destruction, postoperative complications, unsuccessful operative and non-operative procedures performed on this joint. Patients with multiple failures of total knee arthroplasty (TKA) often have significant bone loss, recalcitrant infection, extensor mechanism loss or wound problems that present a complicated surgical picture, making a revision TKA difficult or impossible [6]. Furthermore, post-

operative infection remains a challenge, commonly requiring multiple procedures to manage [7].

Material and Methods

This study has been aimed at making a retrospective and partly prospective analysis of the use of the Ilizarov device on a particular segment of the musculoskeletal system that was applied at the Department of Orthopaedic Surgery and Traumatology in Novi Sad from January 2003 until September 2016. The total number of applied devices on a particular segment of the musculoskeletal system for different kinds of injuries and healing complications was 387 (**Table 1**). The average age of the patients was 43.2 years (ranging from 18 to 67 years). Data were collected from the patients' histories for each segment separately, and from the scientific papers published in journals. In this study we used the methods of clinical examination, standard radiography, CT-scans, as well as ASAMI bone scoring systems for bone healing identification and ASAMI function scoring system, Karlstrom – Olerud, Stewart-Hundley functional scale for humerus and American Orthopedic Foot and Ankle Society (AOFAS). The average follow-up time was 36 months (ranging from 25 to 76 months). There were also complications regarding treatment (nonunion, infection, reapplication of device, nerve and blood vessel injuries, pin breaking, and device stability). Of the total number of patients, 222 (57.5%) were treated for acute injury, 52 (13.7%) were treated for pseudoarthrosis except septic ones, bone and joint deformities were treated in 35 patients (9.0%), knee arthrodesis following failed knee arthroplasty in 31 (8.0%), nonunion in 23 (5.9%), posttraumatic ankle arthrodesis in 20 (5.1%), posttraumatic arthrodesis of elbow in 1 (0.25%) and septic pseudoarthrosis in 3 patients (0.7%). Surgeries were most often performed on the lower leg (216 patients i.e. 55.9%), and the wrist joint was operated only in 5 patients (1.2%), thus being the rarest location. All surgeries were performed by the strict rules of the Ilizarov device application. Postoperative follow-up was performed at the polyclinic and by invitation.

Results

The results of fracture healing and fracture complications are shown here by segments. *Upper arm*: the total number of fractures of the upper arm, including proximal, midshaft and distal intraarticular was 20. Complete fracture healing was achieved in 19 cases (95%). Healing was prolonged in one case (5%). Complications were as follows: pin tract infection developed in 5 cases, and it was solved by antibiotics prescription and every day wound cleaning; transitory radial nerve palsy, one case of transitory ulnar nerve palsy, and one pseudoaneurism of the brachial artery (iatrogenic). Functional outcomes were measured by means of the Stewart-Hundley scoring scale, the results being as follows: 15 excel-

Table 1. Number of operation by segments musculoskeletal system and the type of injuries and complications
Tabela 1. Broj operacija po segmentima lokomotornog sistema, tipu povrede i komplikacija

Segment <i>Segment</i>	N ^o of oper. <i>Br. oper.</i>	Acute fractures <i>Akutni prelomi</i>	Non – union <i>Nesrastanje</i>	Pseudo-arthrosis <i>Pseudo-artroza</i>	Septic pseudo-arthrosis <i>Septična pseudoartroza</i>	Deformities <i>Deformiteti</i>	Post – traumatic arthrodesis <i>Posttraumatska artrodeza</i>	Arthrodesis after failed TKA <i>Artrodeza nakon neuspešne TKA</i>
Humerus <i>Nadlaktica</i>	47	21	9	17			1	
Forearm <i>Podlaktica</i>	17	6	4	7				
Scaphoid <i>Čunasta kost</i>	5			5				
Femur <i>Natkolenica</i>	18	9		9				
Floating knee <i>Plivajuće koleno</i>	15	15						
Knee/ <i>Koleno</i>	31							31
Tibial plateau <i>Tibijalni plato</i>	82	82						
Tibial shaft <i>Golenjača</i>	88	38	10	14	3	23		
Tibial pilon <i>Tibijalni pilon</i>	46	37				9		
Ankle joint <i>Skočni zglob</i>	25	2				3	20	
More segments <i>Više segmenata</i>	13	13						
Total/ <i>Ukupno</i>	387	222	23	52	3	35	21	31

lent, 4 good and 1 poor. Humeral shaft nonunion was treated successfully in 9 cases by the combination of compression-distraction closed osteosynthesis. Of 17 humeral shaft pseudoarthrosis (including atrophic, normotrophic and hypertrophic, excluding septic ones), 15 were completely healed (88.2%); in 2 cases the device was re-applied with the opening of the infection site. Open compressive osteosynthesis was used in 5 cases. In 3 cases the device was placed over the previously used intramedullary and Ender nails. Complete healing was achieved in such cases. *Forearm:* fresh segmental fractures of the forearm were treated in 6 cases. Complete healing was achieved in 5 cases, while one patient had hypertrophic pseudoarthrosis that was treated by reapplication of the device. Two pin tract infections and one transitory radial nerve palsy developed. Four nonunions of the forearm were solved by means of closed monolocal compressive osteosynthesis. Of the 7 forearm nonunions, 2 were radial bone alone; 6 were healed in one stage, and one needed device reapplication. Open bilocal compression-distraction treatment was applied in 2 cases. *Scaphoid bone:* there were 5 cases of nonunion of the scaphoid bone. All except one healed completely. The treatment which followed the frame application consisted of three stages: the frame was distracted 1 mm per day until radiographs showed a 2–3 mm opening at the scaphoid nonunion site (10 days on average); the scaphoid nonunion site was

then compressed for 5 days at a rate of 1 mm per day, with the wrist in 15° of flexion and 15° of radial deviation; the third stage involved immobilization with the Ilizarov fixator for 6 weeks. Open reduction and internal fixation (ORIF) and autologous grafting were performed in one case. *Femur:* nine segmental multi-fragmented fractures, 3 of which being open Gustillo-Anderson type II, were operated by the closed monolocal compression-distraction osteosynthesis technique. Complete fracture healing was achieved in 8 patients, and was prolonged in one case. There were 9 cases of pseudoarthrosis (7 hypertrophic, 2 normotrophic) treated by closed monolocal compression-distraction osteosynthesis. Pin tract infections developed in 4 cases. In 2 cases pins were removed and necrectomy was performed. *Floating knee:* 15 patients were treated for floating knee. The right leg was involved in 9 and the left one in 6 patients. There were 10 Type 1, 3 Type 2A and 2 Type 2B floating knee injuries (Blake & McBryde classification). The sample consisted of 10 male and 5 female patients. The mechanism of injury was a road traffic accident. Out of 15 injuries, 9 fractures were closed and 6 were open. The average age was 36 years. All patients were walking full weight bearing on the fourth postoperative day. Both fracture sites were united in 13 patients (90%), within the average healing time of 10 months.

According to the Karlstrom criteria the end results were: excellent in 8, good in 3, acceptable in 2 and poor in 2 cases. The complications were knee stiffness in 3, delayed union of tibia in 2 and superficial infection in 3 cases.

Knee arthrodesis after failed TKA: the retrospective study showed clinical data for 31 patients treated by the Ilizarov method. There were 17 males and 14 female patients, whose average age was 62.3 years. Cierny-Mader classification and the Engh classification were used for the clinical and pathoanatomic assessment and for the assessment of the bony defect, respectively. Complete healing was documented in 26 patients (83.8%). Average time of bone healing was 5.7 months (ranging from 3 from -18). Average limb shortening was 4.7 cm. Average follow-up period was 21 months. Out of 5 nonunions (16.1%) which developed as complications, 3 were septic intra-articular nonunions, and in two cases the devices were removed due to intolerance.

Tibial plateau: Data sheets for all patients involved in the study contained the following data: gender, age, diagnosis at admission, etiology of the injury, category and type of the injury (classifica-

tion according to Gustillo-Anderson, Oestern and Tscherne, Schatzker and (AO/OTA)) diagnosed by radiological methods (anterior-posterior, lateral-lateral and oblique radiographs) before and after surgery and at follow up. CT scans were performed before surgery. We used MRI in suspected vascular and ligamentous injuries associated with proximal tibial fractures. The classification according to Gustillo-Anderson classifies open fractures into five different categories: I, II, IIIA, IIIB and IIIC. Schatzker classification of complex proximal tibial fractures encompasses grades IV, V and VI. In the period from 2003 to 2016, we treated 82 patients (53 male and 29 female) between the ages of 28 and 77 years (mean 57.6). According to the category of injury, high-energy injuries prevailed in our patients' population (**Table 2**). Conventional radiography was used in all types of fractures. Coronal and sagittal three dimensional reconstructive CT images revealed the exact location and degree of articular depression and found intact regions of the plateau above which a stable construction could be incorporated and olive wires placed (**Figures 1 and 2**). The femoral frame was set in 25 cases when the

Table 2. Review of patient data by type, number and cause of injury

Tabela 2. Pregled podataka o pacijentima prema vrsti, broju i uzroku povređivanja

		n	%
Sex/Pol	Male/Muški	53	64,6
	Female/Ženski	29	35,4
Side/Strana	Right/Desna	50	61,0
	Left/Leva	32	39,0
Mechanism of injury/Mehanizam povrede	Fall/Pad	44	53,6
	Traffic/Saobraćaj	22	26,8
	Riding/Vožnja	10	12,1
Energy type/Energetski tip	Work/Rad	4	4,8
	Assault/Napad	2	2,4
	Low-energy/Niskoenergetske	19	23,1
Type of fracture (Gustillo - Anderson classification) Tip preloma (Gustilo-Andersonova klasifikacija)	High-energy/Visokoenergetske	63	76,9
	I	10	40,0
	II	8	32,0
	III A	4	16,0
Diagnosis/Dijagnoza	III B	3	12,0
	Open/Otvoren	25	30,5
	Closed/Zatvoren	57	69,5
Soft tissue injury (Oestern and Tscherne) Povreda mekog tkiva (Oestern i Tscherne)	Grade 0/Stepen 0	2	9,0
	Grade 1/Stepen 1	3	14,0
	Grade 2/Stepen 2	17	77,0
Type of fracture (Schatzker classification) Tip preloma (Schatzker klasifikacija)	IV	17	20,7
	V	34	41,4
	VI	31	37,8
Type of fracture (AO/OTA classification) Tip preloma (AO/OTA klasifikacija)	B3	3	3,6
	C1	5	6,1
	C2	5	6,1
	C3	69	84,1

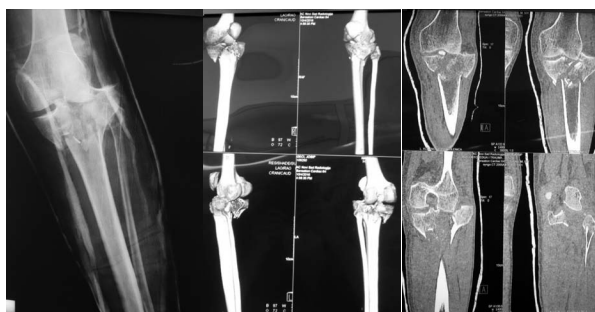

Figure 1. Preoperative AP x-ray, 3D and sagittal CT of proximal tibial fracture.

Slika 1. Preoperativna AP radiografija, 3D i sagitalni CT preloma proksimalne tibije




Figure 2. Intraoperative image after reduction of tibial condyles and the placement wires with olives

Slika 2. Intraoperativni prikaz nakon redukcije kondila tibije i postavke igala sa olivom

distraction over the knee was necessary. In Schatzker V-VI fractures, two rings were added to the structure on the distal part of the femur (**Figure 3**). Out of 25 patients with femoral frames, 13 had hinged rods over the knee joint to allow active movement. The femoral frame was removed 5 weeks after surgery on average. All fractures have healed successfully (**Figure 4**). Circular fixators could be removed without anesthesia for type IV fractures after 16 weeks on average (from 12 to 21 weeks) and for type V-VI after 18 weeks (from 15 to 26 weeks) after surgery. As for the results, 59 were excellent (71.9%), 14 were good (17%), 6 were fair (7.3%) and 3 were poor (3.6%) according to ASAMI bone results (**Table 3**). Regarding complications, transitory peroneal nerve lesions and deep vein thrombosis developed in 4 cases and in 3 cases, respectively. Twenty patients had 39 pin site infections, Checketts-Otterburns grades 1-3, all of which were successfully treated with oral antibiotics and five had pin tract infection grade 4 that healed after pin removal. There were no cases of bone allograft reabsorption. Broken pins were recorded in 5 patients, all of which were replaced in short term intravenous anesthesia. There were 5 cases of deep tissue infection, which were successfully treated with soft tissue debridement and

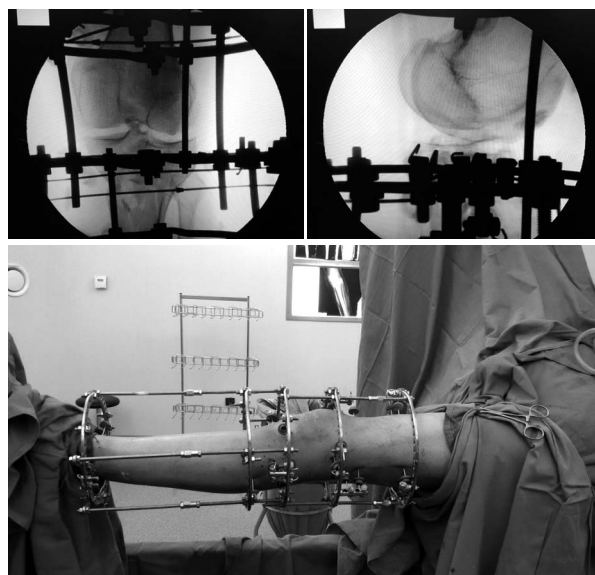


Figure 3. Tibio-femoral ring and radiography after the surgery

Slika 3. Tibiofemoralni ram i radiografija nakon završetka operacije

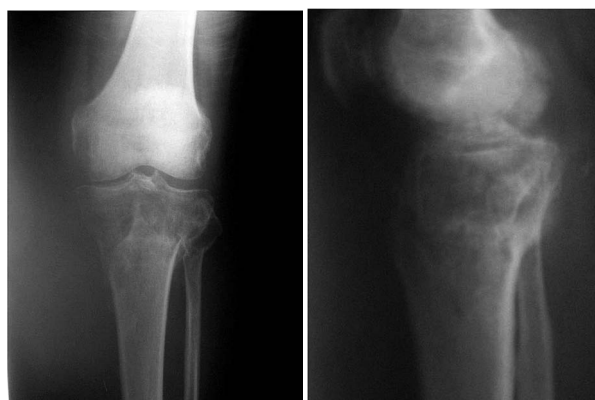

Figure 4. Complete healing of tibial plateau fracture after 12 months

Slika 4. Potpuno srastanje platotibijalnog preloma nakon 12 meseci

parenteral antibiotic use. None of our patients developed osteomyelitis. Neither was the compartment syndrome recorded in our series of patients. One patient had septic arthritis. If the femoral frame was not assembled and cancellous allografts and autografts were not used, the average operative time was 95 minutes (ranging from 80 to 130 minutes). In cases where femoral frame was added and cancellous allografts and autografts were used, the average operative time was longer – 135 minutes (ranging from 105 to 155). The reliability of the modified system for functional evaluation according to Karlstrom-Olerud scoring system was analyzed using Cronbach's alpha coefficient. The values were expressed as Cronbach's alpha coefficient at the three time intervals. On check-up after 6, 12

Table 3. Assessment of bony status by (ASAMI) scoring system**Tabela 3.** Procena koštanog statusa pomoću (ASAMI) bodovnog sistema

Bone results <i>Koštani rezultati</i>		n	%
Excellent <i>Odličan</i>	Union, no infection, deformity < 7°, limb length discrepancy < 2.5 cm <i>Srastanje, bez infekcije, deformitet < 7°, skraćenje ekstremiteta < 2,5 cm</i>	59	71.9
Good <i>Dobar</i>	Union + any two of the following: no infection, deformity < 7°, limb length discrepancy < 2.5 cm/ <i>Srastanje + bilo koja dva od sledećih: bez infekcije, deformitet < 7°, skraćenje ekstremiteta < 2,5 cm</i>	14	17,0
Fair <i>Zadovoljavajući</i>	Union + only one of the following: no infection, deformity < 7°, limb length discrepancy < 2,5 cm/ <i>Srastanje + jedan od sledećih: bez infekcije, deformitet < 7°, skraćenje ekstremiteta < 2,5 cm</i>	6	7,3
Poor <i>Loš</i>	Non union/refracture/union + infection + deformity > 7° + limb length discrepancy > 2.5 cm/ <i>Nesrastanje/refraktura/srastanje + infekcija + deformitet > 7° + skraćenje ekstremiteta > 2,5 cm</i>	3	3,6

and 18 months, Cronbach's alpha coefficient was 0.841, 0.869 and 0.891 respectively. The obtained Cronbach's alpha coefficient values exceeded 0.80, thus our modified scale for functional evaluation according to Karlstrom-Olerud proved to be reliable in this study. *Tibial pilon fractures:* Out of 37 patients treated for acute pilon fractures, 32 were men and 5 were women. On average, the patients were operated 3 days after injury. Thirty two fractures were closed and 5 were open. The average age of the patients was 36 years. The average wearing time of the apparatus was 3.5 months. Complete healing was achieved in 33 cases, extended healing in 2 cases, and pseudoarthrosis in 2 cases (later re-operated). Transient infection around the needles of the apparatus occurred in 5 cases, which was treated with antibiotics based on smear findings. We analyzed the functional results (contracture of the ankle, limping, sympathetic dystrophy, pain and immobilization). According to the parameters of the Karlstrom-Olerud functional evaluation, the result was excellent in 26 patients, good in 4, moderate in 4 and poor in 3 cases.

Tibial shaft fractures: Out of 88 fractures and complications at the tibial shaft level, 38 were acute fractures, and most of them were segmental and multi-fragmented. Eight of them were open (3 were of Gustillo - Anderson type I, 3 were type II, and 2 were type III). Most of them, i.e. - 35 (92.1%) healed, whereas healing was prolonged in 3 cases. Pin tract infections were noted in 5 cases. Osteitis, which developed in 2 cases, was treated by radical debridement of the necrotic bone segment. Ten non-unions were treated by the application of the device, and all ten healed. Fourteen pseudoarthroses (7 hypertrophic, 3 normotrophic and 4 atrophic) were successfully treated by the application of the device. In three cases we had septic pseudoarthrosis: in two we performed bone resection and restoration using synchronously bilocal compression-distraction osteosynthesis. Tibial deformities (valgus, varus, antecurvate and recurvate) were noted in 23 cases; most of them were treated by open compression-distraction, mono or bilocal osteosynthesis. *Ankle*

joint: the device was applied in 25 patients. In 2 cases the device was applied primarily for the bimalleolar and trimalleolar fractures. There were 2 cases of acquired deformities of the ankle joint, which were treated by a combination of osteotomy of the foot bones and device application. We also performed ankle joint arthrodesis in 20 patients, because of the previously failed osteosynthesis or conservatively treated pylon fractures. The total number of successful fusions was 18 (90%). Non-union was recorded in 2 (10%) cases. The average time of healing was 23 weeks (ranging from 10 to -58 weeks). Radiographic evaluation of healing was based on evidence of cortical bridging between tibial and talar, or talar and calcaneal surfaces. Criteria for nonunions were the existence of large lucency between articular surfaces, and passive motion at the planned fusion site. Postoperative complications were divided into two groups. As for major complications, there were 2 cases of nonunion, malunion in 1 case and broken pins in 2 cases. Minor complications were pin site infection in 5 cases, and collapse of calcaneus in 1 case. Assessment of the functional results was represented according to AOFAS hindfoot score.

Application of the device on more than one segment: in 13 cases we the device was applied on more than one segment in the same patient due to polytrauma. Most often it was on the lower leg and femur (8 cases), both lower leg (3 cases), lower leg and humerus (1 case) and forearm and humerus (1 case).

Discussion

Many diaphyseal fractures of the humerus heal without surgical intervention [8]. The severity of the initial injury, the transverse pattern of the fracture, distraction of the fracture, soft-tissue interposition or inadequate immobilization can result in nonunion. Alcoholism, obesity and the method of treatment may also be contributing factors [9]. When there are additional complications such as poor soft tissue or infection, treatment by conven-

tional methods of internal fixation becomes very difficult. We will describe our experience using the Ilizarov circular external frame to treat multifragmentary acute open or closed humeral fractures, nonunion of the humerus which persisted after surgical stabilization. The treatment of atrophic nonunions is aimed at restoring osteogenic activity at the fracture site, which can be achieved by the resection of fibrous tissue within the fracture site and implantation of an autograft, and if there is instability, revision of osteosynthesis should be made [10]. Nonunion after conservative management can be successfully treated by various surgical methods. These include open reduction and internal fixation with plates and screws, reamed intramedullary nailing and external fixation. Supplementing fixation with bone graft achieves union reliably [12]. Failure to unite after surgical treatment may be due to poor contact between bone ends, inadequate stabilization, devitalization of bone, osteopenia and bone defects. Satisfactory results with the Ilizarov method of treating acute fractures and nonunion of humerus fractures have been reported previously [13–15]. The intention of our study was specifically to assess its effectiveness in treating nonunion which persisted despite surgical stabilization since such cases are notoriously difficult to treat [13–15]. Further surgery can put vital structures such as the radial nerve at risk. Internal fixation can be difficult because of disuse osteopenia or other bone defects. The quality of the soft tissues may be poor and the presence of infection precludes the use of internal fixation. It is possible to achieve stable fixation with the Ilizarov frame, even in the presence of osteopenia or bone defects. Unless there is infection, surgical exposure of the site of nonunion is often unnecessary except to remove implants. As the wires can be placed away from the site of the fracture, the frame can be applied after excision of the infected nonunion. Union can be achieved without bone grafting. Bone grafts were not used in any of our 17 patients with pseudoarthrosis, and 15 progressed to union. None of our 9 patients with nonunion were treated with bone grafts and they all healed. A further advantage of the method is that it allows both compression and distraction, which may stimulate healing [14, 15]. Of the three patients who presented to us with palsy of the radial nerve two had developed iatrogenic damage to the nerve as a consequence of previous delayed open surgery. There were some complications. We had 3 cases of nerve injury, none of which resulted in a permanent deficit. Pin-site infections were common, but there was no chronic deep infection. Some patients complained that impingement of the frame on the chest caused discomfort and made it difficult to sleep. As some of these problems are unavoidable, it is essential that patients be counseled and monitored closely.

Fresh segmental fractures of the forearm were treated in 6 cases. Union was achieved in 5 patients, and no cases of infection were recorded. Nonunion

in 4 cases was successfully healed. All pseudoarthrosis with or without bone defect here healed successfully as well. Green [16] evaluated two different methods of managing segmental skeletal defects. A total of 15 patients treated with the open bone graft (Papineau) technique were compared with 17 patients treated with the Ilizarov procedure. There were many complications in the bone grafted group such as limited graft availability, donor site morbidity and graft fractures. In the bone transport group, the main problem was the failure of the docking site to unite without the supplementary graft. In the study of Harrington et al. [17] 5 open fractures of the ulna with bone loss of more than 8 cm were treated by bone transport and external fixator. A satisfactory functional result was achieved, demonstrating the efficacy of this technique for difficult forearm reconstruction. Esser [18] reported a case treated with bone transport. Treatment was completed in 10 months and the only complication was transient superficial pin site infection. In this study, the rate of complications was relatively low, although it must be taken into account that patients had undergone 2.3 operations on average (from 1 to 4) before the Ilizarov device was applied.

We treated 5 patients with scaphoid nonunion using the Ilizarov compression/distraction technique without opening the nonunion site and without the use of bone graft. Internal fixation with AO or Herbert screws has been shown to improve union rates when compared with K-wire fixation [29]. A recent systematic review reported union rates of 80% using bone graft without fixation, 85% using bone graft with fixation, and 91% using vascularized bone grafts [19]. The Ilizarov technique performed in this series involved the application of a circular external fixator without the use of bone graft, and thus its main advantage was that it eliminated the need to expose the nonunion site, prevented further soft-tissue damage and avoided the morbidity and technical difficulties of potential bone graft harvesting. Bumbaširević et al. [20] in their retrospective study used the Ilizarov external fixator in a series of 18 patients and they reported the fusion in all cases after 4 month wearing time on average. The results of this study are promising and demonstrate that distraction-compression using the Ilizarov method without the use of bone graft is a safe technique and that in selected cases it may be an effective way of managing scaphoid nonunion.

The primary objective of the Ilizarov technique was to eliminate infection by increasing vascularity of the osteomyelitic centre through biological stimulation of a corticotomy (osteomyelitis burns in the fire of regeneration), but the infection was not always cured. Therefore, thorough debridement before distraction osteogenesis is recommended. Distraction osteogenesis involves mechanical induction of new bone formation between bony surfaces that are gradually pulled apart. After corticotomy, bone transport entails movements of living bone segments to fill an intercalary bone defect. The trailing end regenerates

the bone by intramembranous ossification and the leading end fuses with the target bone surface [21]. The results of conventional treatment of infected nonunion of the femur are poor due to high velocity primary trauma, multiple surgeries, late presentation, bone and soft tissue infection, nonunion, bone loss, osteoporosis, dystrophy, poor vascularity, associated deformities, and shortening. The Ilizarov technique is a salvaging procedure for these difficulties. All our patients had been subjected to several surgeries before they underwent treatment by the Ilizarov technique. Bone healing and functional results as assessed by ASAMI criteria were not well correlated. The functional results, as a rule, were poorer. Stoiljković et al. [22] used internal fixation with a self-dynamisable internal fixator as a re-osteosynthesis method in 6 polytraumatized patients, thereby achieving union in 83% of patients. Kufitryev and Meshkov, according to Paley [23] reported 147 bridgings in 154 bone defects of femoral bone, with a failure rate of 4.5%, and elimination of bone inflammation in 41 out of 45 cases (91%). In our patients, the outcome of bone consolidation was better than the functional results. In our series, cancellous bone grafting was not applied at all. We performed subcutaneous re-corticotomy of the fragment around the docking site. Curettage of the ends of fragments and of the wound base was performed periodically in all cases with open wounds. Shevtsov et al. [24] described the results of a technique associating multiple segment lengthening, automatic high-frequency lengthening, and stimulation of bone regeneration by extemporaneous compression at the end of traction. They reported shorter treatment periods and very satisfactory anatomic and functional outcomes. Although our study showed the efficacy of the Ilizarov method in limb salvation, prospective studies are necessary for further evaluation of this mode of treatment.

Ipsilateral fractures of the femur and tibia (floating knee) are a challenging problem to manage due to a fact that they may include combinations of diaphyseal, metaphyseal, and intra-articular parts of femur and tibia, and are often associated with soft tissue and vascular injuries. Stabilization and early mobilization of the patient produce best clinical outcomes. Surgical treatment is the method of choice in the treatment of these fractures [25]. Internal fixation has the advantage over conservative treatment because it rarely leads to stiffening of the knee and limb shortening, and both hospitalization and absence from work are shorter. Omer et al. [26] treated these fractures conservatively and surgically as well and found that the time required for the splicing was 8 weeks shorter when the fractures were treated surgically. Behr et al. [27] used intramedullary nailing in the treatment of these fractures, with average femur healing time of 10.5 weeks and 18 weeks healing time for the tibia. Ostrum et al. [28] treated their patients with retrograde nailing and achieved healing time of 14.7 weeks for the femur on average and 23 weeks for tibia. Lundy and Johnson [25] claim that the surgical stabilization of these fractures is a prerequisite for early mo-

bilization of patients thus giving the best results. Other authors have also reported similar data for treatment using the Ilizarov apparatus with this injury [29]. Good treatment tactic, stabilization and early mobilization of patients have the best clinical outcomes in treatment of „floating knee“ type of fractures.

Knee arthrodesis may be the only option of treatment in cases of chronic infected total knee arthroplasty with concomitant irreparable extensor mechanism disruption, extensive bone loss or severe systemic morbidities. In many cases it is well tolerated by patients with all the benefits that it carries. The advantages are the stability of the site of tibio-femoral fusion, prevention of varus-valgus deformation and external rotation of the limb and maintenance of constant tibio-femoral angle of flexion. The technique of femoral-tibial fusion with a monoaxial or biaxial external fixator has a success rate that ranges from 68% [30] to 89% [31] and up to 100% [32]. These fixators, especially monoaxial ones, are fairly well tolerated by patients. However, they do not allow significant changes in the axis, and, due to their structural characteristics, they are rigid and not entirely reliable for complete load-bearing [33]. A combination of external fixation and stabilization of the fusion site of the knee joint with two Steinmann pins was shown by Riouallon et al. [34]. In a series of 9 patients, 6 were with signs of septic TKA. Three of them had a single stage and the remaining three two-stage protocol. After 8 years all the arthrodesis displayed signs of fusion (100%). The external fixator was removed after 5.2 months on average, and no recurrent infection was reported. Hybrid fixators were used in knee arthrodesis after septic TKA. Raskolnikov et al. [35] used the Taylor external fixator (TSF) in a series of 7 patients. They reported the fusion in 71% of cases after 8.4-month wearing time on average. The external circular fixation by Ilizarov apparatus gives great results in terms of rate of fusion. The existing literature on knee arthrodesis with an Ilizarov circular external fixator reports success rates that vary in different studies from 64% to 100% [36–38]. In our current series, the union rate was 83.8% as well. Mean time was 5.7 months (3–18) with an average follow-up period of 21 months. Nine patients (29%) underwent one-stage surgery and 22 (71%) had two-stage surgery. Out of 5 nonunions (16.1%) which developed as complications, 3 were septic intra-articular nonunions and in two cases the device was removed due to intolerance. We believe in the importance of carefully assessing the patient's ability to cooperate before treatment. The mean residual limb length discrepancy in our series was 4.7 cm (range 0–8 cm), which is slightly more than in the test series reported by other authors (3.5 cm), [36] - (4.46 cm), [38]. It should be noted that some authors have not presented these data in their observational series [36–38]. We performed lengthening of the extremities in two cases and four patients had bone grafting (two allografts and two autografts). We have not recorded any cases of graft resorption.

The limiting factor of this study is its retrospective nature. The number of respondents is relatively small and we certainly cannot provide information and prognostic factors that would shorten the appliance wearing time. The number of bone grafting (with good results) in our series is too small to draw any conclusion as to what procedure offered the best results (allograft, autograft bone or other substitute). A prospective study would also be desirable.

During the past three decades, the development of new techniques and equipment has changed the approach in the treatment of these injuries toward minimally invasive surgery. The biological and mechanical advantages of the circular external fixator in the treatment of high velocity tibial plafond fractures have been described [39–43]. Current literature data strongly indicate the advantages of the Ilizarov method, such as adequate fixation of tibial bone fragments, low rate of trauma of the surgical procedure, preservation of fragment vascularity, adequate compression (during and after surgery), as well as stable limb fixation and minimizing the risk of posttraumatic osteoarthritis [39–43]. Some studies support two-staged protocol for the treatment of proximal tibia fractures, especially in the cases of high-energy fracture [44]. Irrespective of the fracture pattern, all patients can be operated on without delay, wherein the Ilizarov method has advantages. In this study, the two-staged protocol was not used, so we were able to avoid the disturbance of the healing process with other procedures that can delay the rehabilitation process. Arthroscopy is widely suggested as a treatment option in meniscal lesions, which may occur in tibial plateau fractures, whether performing resection or repair [45]. Our results, obtained during the 18-month follow-up period, demonstrated that the application of transosseous osteosynthesis by the Ilizarov apparatus along with early rehabilitation therapy resulted in improved functional outcome (good according to Karlstrom-Olerud) in the treatment of open and closed multiple intra-articular fractures of the proximal tibia in the majority of patients, which is comparable with similar published studies [39–43].

Transosseous osteosynthesis technique is a good method for tibiootalcalcaneal joint fusion, especially in the case of coexisting joint infections, bone

and joint defects or limb discrepancy. Our results and the results of many authors indicate that the Ilizarov method is an effective alternative means of correcting complex foot deformities, especially in feet that have previously undergone surgery [46].

Comminutive fractures of the tibial pilon are very serious ankle injuries, and therefore a serious problem for the orthopedic surgeon who treats them and have a highly uncertain outcome. Treatment of these injuries even with best surgical technique leaves some impact on the function of the ankle. Transosseous osteosynthesis with the Ilizarov apparatus in our experience and in the experience of most authors has proved to be significantly superior to the traditional methods of osteosynthesis (ORIF), because it reduces the risk of infection, and enables good management with bone fragments [47].

Our results in treatment of acute tibial shaft fractures and deformities caused by complications of treatment with this method in comparison with the observation of other authors who apply the same method also give us the right to claim with certainty that this method can be called “the method of choice” for the treatment of multifragmented open and closed fractures and consequent deformities [48]. A large number of polytraumatized patients were treated and insertion of more than one appliance to the locomotor system in very serious, multiple bone injuries is a definitive mode of treatment [49]. Our results in this type of application are very good.

Conclusion

Although the Ilizarov method carries some inconveniences for patients besides being costly and labor-intensive, it is an effective way of treating complicated nonunion in which previous surgical treatment has failed. The Ilizarov system provides rigid fixation even in the osteoporotic bone and allows early active and passive motion starting from the first postoperative day. The Ilizarov system is superior to other methods of treatment, especially when there is an infection and bone loss as the mechanical stimulations increase local tissue nourishment, and transosseous osteosynthesis restores the function of the injured limb, increases local blood flow and stimulates osteogenesis.

References

1. Schwartzman V, Martin SN, Ronquist RA, et al. Tibial fractures. The Ilizarov alternatives. *Clin Orthop*. 1992;278:207-16.
2. Song HR, Kale A, Park HB, et al. Comparison of internal bone transport and vascularized fibula femoral bone defects. *J Orthop Trauma*. 2003;17(3):203-11.
3. Lawrence B. Management of polytrauma. In: Champan MW, editor. *Operative orthopaedics*. Philadelphia: JB Lippincott Company; 1993. p. 299-304.
4. Iacobellis C, Cacciato F. Aseptic nonunion and delay in consolidation in the tibia: treatment by intramedullary nailing and using the Ilizarov method. *Chir Organi Mov*. 2001;86(3):199-210.
5. Rozbruch SR, Ilizarov S. *Limb lengthening and reconstruction surgery*. New York: Informa Healthcare; 2007.
6. Cierny G 3rd, Cook WG, Mader JT. Ankle arthrodesis in the presence of ongoing sepsis: indications, methods, and results. *Orthop Clin North Am*. 1989;20:709–21.
7. Wiedel JD. Salvage of infected total knee fusion: the last option. *Clin Orthop Relat Res*. 2002;404:139.
8. Lange RH. Fractures of the humeral shaft. In: Levine AM, editor. *Orthopaedic knowledge update: trauma*. Rosemont, Illinois: American Academy of Orthopaedic Surgeons; 1996. p. 25-34.

9. Ranieri L, Olmi R. Nonunion of the humerus after internal fixation: treatment by intramedullary nailing and grafting. *Ital J Orthop Traumatol.* 1976;2:51-5.
10. Gajdobranski ĐR, Živković D. Poremećaji zarastanja pre-loma. *Med Pregl.* 2003;56(3-4):146-51.
11. Healy WL, White GM, Mick CA, Brooker AF, Weiland AJ. Nonunion of the humeral shaft. *Clin Orthop.* 1987;219:206-13.
12. Fattah HA, Halawa EE, Shafy TH. Nonunion of the humeral shaft: a report on 25 cases. *Injury.* 1982;14:255-62.
13. ASAMI group. Nonunions of the humerus. In: Bianchi Maiocchi A, Aronson J, editors. *Operative principles of Ilizarov: fracture treatment – nonunion osteomyelitis-lengthening deformity correction.* Baltimore etc: Williams and Wilkins; 1991. p. 263-72.
14. Catagni MA, Guerreschi F, Probe RA. Treatment of humeral nonunions with the Ilizarov technique. *Bull Hosp Jt Dis Orthop Inst.* 1991;51:74-83.
15. Lammens J, Bauduin G, Driesen R, et al. Treatment of nonunion of the humerus using the Ilizarov external fixator. *Clin Orthop.* 1998;353:223-30.
16. Green A. Skeletal defects. A comparison of bone grafting and bone transport for segmental skeletal defects. *Clin Orthop.* 1994;301:111-7.
17. Harrington K, Saleh M. An open fracture of the ulna with bone loss, treated by bone transport. *Injury.* 1999;30:349-56.
18. Esser D. Treatment of a bone defect of the forearm by bone transport. A case report. *Clin Orthop.* 1996;326:221-4.
19. Munk B, Larsen CF. Bone grafting the scaphoid nonunion: a systematic review of 147 publications including 5,246 cases of scaphoid nonunion. *Acta Orthop Scand.* 2004;75(5):618-29.
20. Bumbaširević M, Tomić S, Lešić A, Bumbaširević V, Ra-kočević Z, Atkinson HD. The treatment of scaphoid nonunion using the Ilizarov fixator without bone graft, a study of 18 cases. *J Orthop Surg Res.* 2011;6:57.
21. Association for the Study and Application of the Method of Ilizarov Group: non-union of the femur. In: Bianchi-Maiocchi A, Aronson J, editors. *Operative principles of Ilizarov. Fracture treatment, non-union, osteomyelitis, lengthening, deformity correction.* Baltimore: Williams and Wilkins; 1991.
22. Stojiljković P, Golubović Z, Mladenović D, Micić I, Kara-lejić S, Stojiljković D. Spoljašnja skeletna fiksacija preloma dijafize butne kosti kod politraumatizovanih pacijenata. *Med Pregl.* 2008;61(9-10):497-502.
23. Paley D. Problems, obstacles, and complications of limb lengthening by the Ilizarov technique. *Clin Orthop.* 1990;(250):81-104.
24. Shevtsov V, Popkov A, Popkov D, Prevot J. Reduction of the period of treatment for leg lengthening. Technique and advantages. *Rev Chir Orthop Reparatrice Appar Mot.* 2001;87:248-56.
25. Lundy W, Johnson D. "Floating knee" injuries: ipsilateral fractures of the femur and tibia. *J Am Acad Orthop Surg.* 2001;9(4):238-45.
26. Omer E, Moll H, Bacon WL. Combined fractures of the femur and tibia in a single extremity: analytical study of cases at Brooke General Hospital from 1961-to1967. *J Trauma.* 1968;8(6):1026-41.
27. Behr T, Apel M, Pinzur S, Dobozi R, Behr J. Flexible intramedullary nails for ipsilateral femoral and tibial fractures. *J Trauma.* 1987;27(12):1354-57.
28. Ostrum RF. Treatment of floating knee injuries through a single percutaneous approach. *Clin Orthop Relat Res.* 2000;375:43-50.
29. Lalic I, Lukic M, Vukajlovic B, Tomic S. Ipsilateral fractures of femur and tibia treated with the Ilizarov apparatus: our results. *HealthMED.* 2013;7(5):1583-7.
30. Bengston S, Knutson K, Lidgren L. Treatment of infected-knee arthroplasty. *Clin Orthop Relat Res.* 1989;245:173-8.
31. Hanssen AD, Trousdale RT, Osmon DR. Patient outcome with reinfection following reimplantation for the infected total knee arthroplasty. *Clin Orthop Relat Res.* 1995;321:55-67.
32. Engh GA, Ammeen DJ. Bone loss with revision total knee arthroplasty: defect classification and alternatives for reconstruction. *Instr Course Lect.* 1999;48:167-75.
33. Paley D. Problems, obstacles and complications of limb lengthening by the Ilizarov technique. *Clin Orthop Relat Res.* 1990;250:81-104.
34. Riouallon G, Molina V, Mansour C, Court C, Nordin JY. An original knee arthrodesis technique combining external fixator with Steinman pins direct fixation. *Orthop Traumatol Surg Res.* 2009;95:272-7.
35. Raskolnikov D, Slover JD, Egol KA. The use of a multi-planar, multi-axis external fixator to achieve knee arthrodesis in a worst case scenario: a case series. *Iowa Orthop J.* 2013;33:19-24.
36. Oostenbroek HJ, van Roermund PM. Arthrodesis of the knee after an infected arthroplasty using the Ilizarov method. *J Bone Joint Surg Br.* 2001;83:50-4.
37. Manzotti A, Pullen C, Deromedis B, Catagni MA. Knee arthrodesis after infected total knee arthroplasty using the Ilizarov method. *Clin Orthop Relat Res.* 2001;389:143-9.
38. David R, Shtarker H, Horesh Z, Tsur A, Soudry M. Arthrodesis with Ilizarov device for failed knee arthroplasty. *Orthopedics.* 2001;24:33-6.
39. Lalić I, Daraboš N, Stanković M, Gojković Z, Obradović M, Marić D. Treatment of complex tibial plateau fractures using Ilizarov technique. *Acta Clin Croat.* 2014;53(4):437-48.
40. Kumar A, Whittle AP. Treatment of complex (Schatzker type VI) fractures of the tibial plateau with circular wire external fixation: retrospective case review. *J Orthop Trauma.* 2000;14:339-44.
41. Ramos T, Ekholm C, Eriksson B, Karlsson J, Nistor L. The Ilizarov external fixator: a useful alternative for the treatment of proximal tibial fractures; a prospective observational study of 30 consecutive patients. *BMC Musculoskelet Disord* [Internet]. 2013 [cited 2014 Jun 19];14:11. Published online 2013 January 7. doi:10.1186/1471-2474-14-11. Available from: <http://www.biomed-central.com/1471-2474/14/11>.
42. El Barbary H, Abdel Gani H, Misbah H, Salem K. Complex tibial plateau fractures treated with Ilizarov external fixator with or without minimal internal fixation. *Int Orthop.* 2005;29:182-5.
43. Dendrinis GK, Kontos S, Katsenis D, Dalas A. Treatment of high-energy tibial plateau fractures by the Ilizarov circular fixator. *J Bone Joint Surg Br.* 1996;78(5):710-7.
44. Egol KA, Tejwani NC, Capla EL, Wolinsky PL, Koval KJ. Staged management of high-energy fractures (OTA types 41): the results of a prospective standardized protocol. *J Orthop Trauma.* 2005;19:448-55.
45. Harhaji V, Subašić S, Ninković S, Lalić I, Salamon T, Ristić V. The impact of combined meniscus tear on quality of life after anterior cruciate ligament reconstruction. *Med Pregl.* 2016;69(5-6):153-9.
46. Katsenis D, Bhave A, Paley D, Herzenberg JE. Treatment of malunion and nonunion at the site of an ankle fusion with the Ilizarov apparatus. *J Bone Joint Surg Am.* 2005;87:302-9.
47. Vasiliadis ES, Grivas TB, Psarakis SA, Evangelos P, Kaspiris A, Triantafyllopoulos G. Advantages of the Ilizarov external fixation in the management of intra-articular fractures of the distal tibia. *J Orthop Surg Res.* 2009;4:35.

48. Spiegelberg B, Parratt T, Dheerendra S, Khan W, Jennings R, Marsh D. Ilizarov principles of deformity correction. *Ann R Coll Surg Engl.* 2010;92(2):101-5.

49. Lalić I, Obradović M, Lukić-Šarkanović M, Đan V. Definite management of bilateral lower leg nonunion fractures by Ilizarov apparatus in polytraumatized patient-case report. *Med Pregl.* 2015;68(3-4):130-5.

Rad je primljen 2. 11. 2016.

Recenziran 10. 12. 2016.

Prihvaćen za štampu 16. 12. 2016.

BIBLID.0025-8105:(2016):LXIX:Suppl 1:23-33.



Ward for Musculoskeletal Infections
Odeljenje za koštano-mišićne infekcije

Clinical Center of Vojvodina, Novi Sad
Department of Orthopedic Surgery and Traumatology¹
University of Novi Sad, Faculty of Medicine²

UDK 616.728.2-089.84
DOI: 10.2298/MPNS16S1035S

ARTHROPLASTY OF THE HIP JOINT

ARTROPLASTIKA KUKA

**Dragan SAVIĆ^{1,2}, Aleksandar LAŽETIĆ¹, Veselin BOJAT¹, Srđan RADIĆ¹, Zoran GOJKOVIĆ^{1,2}
and Vladimir HARHAJI^{1,2}**

Summary

Total hip arthroplasty has completely revolutionized the nature in which the arthritic hip is treated, and it is considered to be one of the most successful orthopedic interventions of its generation. It has been practiced at the Department of Orthopedic Surgery and Traumatology, Clinical Center of Vojvodina, Novi Sad since 1970, and several thousand interventions like this have been performed. A continuous increase in the number of such interventions is noticed, this particularly applies to revision hip arthroplasty procedures by implanting cementless, hybrid and cemented prostheses. In routine clinical practice fresh frozen allotransplants from bone bank are used to fill the bone defect, and 671 revision hip interventions were performed in the last 15 years. A large number of arthroplasty procedures and good postoperative outcome result from long tradition in performing these interventions, and they are achieved by well educated orthopedic surgeons, excellent anesthesiology care and very professional staff assisting in treatment of these patients.

Key words: Arthroplasty, Replacement, Hip, Osteoarthritis; Allografts; Reoperation; Bone Banks; Treatment Outcome; Recovery of Function

Introduction

Degenerative changes to small and large joints of the human organism are the most common diseases of the locomotor system. The prolongation of human life resulted in the fact that almost every human of an older age suffers from ailments related to the locomotor system as a result of degenerative changes. Changes to the joints caused by degeneration can be found throughout the human population to a lesser or greater degree depending on the race, climate and conditions of life [1]. Degenerative joint diseases (arthroses) belong to the group of persistent chronic processes manifested in the progressive deterioration of articular cartilage and tissue support and they are accompanied by proliferative processes on the bone tissue of joints [2]. The incidence of degenerative joint diseases in the human population is very high taking the fourth place among the causes of diseases, i.e. of medical treatment of the human population in western countries, after cardiovascular, cerebrovascular and lung diseases. In 2003, 42.1 million people underwent medical treat-

Sažetak

Totalna artroplastika zgloba kuka u potpunosti je revolucionizovala prirodu tretiranja artritisa kuka i smatra se jednom od najuspešnijih ortopedskih intervencija svoje generacije. Na Klinici za ortopedsku hirurgiju i traumatologiju Kliničkog centra u Novom Sadu primenjuje se od 1970. godine i do sada je urađeno više hiljada ovakvih intervencija. Uočava se kontinuirani porast ovih intervencija što se posebno odnosi na revizione artroplastične procedure na zglobu kuka. Poslednjih 10 godina urađeno je 4 661 artroplastična procedura na zglobu kuka tako što su implantirane bescementne, hibridne i cementne proteze. U rutinskoj kliničkoj praksi se primenjuju sveže zamrznuti alotransplantati iz koštane banke radi popunjavanja koštanog defekta tako da je u poslednjih 15 godina izvršen 671 revizijski zahvat na zglobu kuka. Veliki broj artroplastičnih procedura i dobri postoperativni rezultati bili su mogući zahvaljujući tradiciji u obavljanju ovih zahvata, dobro edukovanim ortopedskim hirurzima, odličnoj anesteziološkoj brizi i veoma stručnom osoblju koje učestvuje u lečenju ovakvih pacijenata.

Ključne reči: artroplastika kuka; osteoarthritis; alografti; revizija; koštane banke; ishod lečenja; funkcionalni oporavak

ment in the US as the result of degenerative diseases, while it is anticipated that the number of patients will considerably increase in 2030 and amount up to 67 million. Medical treatment costs of such a large number of patients are enormous thus significantly burdening health systems of countries throughout the world as well as of our country. In the US alone 233.5 billion dollars were spent in 1997 to treat the patients with degenerative disorders of locomotor system, in 2003 the sum amounted to 321.8 billion dollars, with the tendency of constant growth.

Etiology

Depending on etiological factors arthroses are distinguished as primary and secondary.

Primary arthroses – The actual cause of degenerative changes with no apparent cause, i.e. due to aging, has not been completely clarified until today, that is why they are called essential arthroses. They begin without any known cause and more or less represent the normal process of aging. They usually occur

Abbreviations

THA	– total hip arthroplasty
NAD	– no appreciable disease
PRP	– platelet rich plasma
BMAC	– bone marrow aspiration concentrate
AATB	– American Association of Tissue Banks
EAMST	– European Association of Musculo-Skeletal Transplantation
EATB	– European Association of Tissue banks

after the age of 40 years and their frequency grows by aging. The frequency of degenerative changes is significantly influenced by heredity factor, body composition, they are also more frequent after meno and andropause which is explained by a decrease in secretion of sex hormones. In addition, certain jobs speed up the onset of arthritic changes to joints, especially at places where vibrations and counter-strokes are involved (workers on pneumatic drills, blacksmiths, farmers etc.)

Secondary arthroses – They result from various static disruptions, posttraumatic conditions, inflammatory processes etc. At the beginning a pathological process takes place at the level of articular cartilage and the further development of degenerative changes induces reactive changes on articulated bone ends, which are usually mono or biarticular, having larger significance if they occur in lower extremities.

Traumas of joints and their adjacency such as intraarticular fractures, osteochondritis dissecans, free articulated body and similar, considerably add to an onset of degenerative changes, especially when treatment is inadequate.

Arthritic changes to hip joint result from both congenital and acquired disruption of joint statics, altered dynamic ratio of articular surfaces such as with congenital hip displacement, conditions after Perthes disease and epiphysiolysis and others.

Inflammatory joint diseases - nonspecific arthritis is nowadays relatively rare thanks to efficient antibiotic therapy, but it occurs with certain immunodeficiency disorders. An increase in specific joint inflammations has recently been registered, especially tuberculosis, which is explained by deteriorated life conditions and nutrition, greater number of stressful situations, etc.

In addition, arthritic changes develop to a large extent into rheumatoid arthritis, femur head aseptic necrosis, non treated gout cases, with frequent hemarthrosis with hemophilia, certain internal diseases (Addison, Paget, Gaucher, rachitis and other) etc.

Clinical picture

The reason why patients seek medical help for the first time is pain, which usually occurs in primary arthrosis after certain physical effort such as longer walking (especially on rough ground), running, carrying load, performing heavy physical work, etc. Patients usually deny the existence of trauma or they mention some low-intensity injuries. The pain can be intensified by exposure to a variety of weather factors, such as cold or humidity.

Stiffness is characterized by a limited range of motion in diseased joints, often accompanied by crepitations and popping sounds, which is of a low intensity at the onset of a disease, but it gets worse (contracture) as degenerative changes develop and affect all hip structures in the latest stage.

Deformity - Due to numerous osteophytes, distended bursa and tendon constriction and muscles spasm, large swollen joints are formed, which are difficult to be recognized in the region of the hip.

Degenerative changes to the hip lead to walking abnormalities (limp) caused by pain and constriction of extremities. After a certain period of time, the difficulty to move and pain result in muscular hypotrophy, which additionally contributes to the reduction of movement.

Diagnosis - is made based on anamnestic data in the presence of persistent pain, difficulty in moving and stiffness apart from general symptoms. Laboratory analyses show NAD (no appreciable disease), except of the potential increase in cell number of punctured synovial fluid. In case of primary arthroses X-ray examination shows no significant changes to the affected joints in the early stage of disease. On the contrary, in case of secondary arthroses, i.e. posttraumatic conditions, inflammatory diseases, disruption of joint statics (congenital disruption, Perthes disease etc.) there are deviations from findings usual for the patient's age. As the disease progresses the first changes are found on the cartilage, which result in constriction of joint ends on X-ray. It is necessary to emphasize that radiological changes on bones are not in direct correlation with a subjective discomfort of the patient. In some patients this subjective discomfort is more distinct than in those having significant degenerative changes visible on X-ray.

All previously quoted causes of secondary arthroses, which have differential diagnostic value relative to primary (idiopathic) arthroses, should be taken into consideration (rheumatoid arthritis, inflammatory, specific and nonspecific, joint diseases, metabolic illnesses, some arthropathies, aseptic necroses (especially hip), tumors etc.)

Considering the prevalence of degenerative diseases, no wonder they are the reason for a high number of working days lost, while the medical treatment applied in order to lessen discomfort and increase the functional ability of a patient is also one of the biggest item in total costs allocated to health insurance. The patient's ability to work depends mainly on the process localization, functional overload as well as on subjective discomfort. It depends on working place and way of performing the job, with emphasis on non-physiological body posture (body bending during work, kneeling, seating, crouch, continuous load of spinal column when carrying weight and similar).

Treatment

Generally speaking the aim of treating degenerative changes is to ease pain and muscular spasm, improve the function of diseased part of the human organism,

prevent joint contractions, i.e. encourage patients to resume their daily routine and professional activities. In most cases it is a conservative way of treatment i.e. medicamentous and physical therapy, whereas surgical treatment (orthopedic) is assigned only with exceptionally advanced types of disease when there are distinct destructive changes to musculoskeletal system or in conditions where there is a necessity for static anomalies correction of affected extremities (in certain congenial and posttraumatic conditions).

Conservative treatment depends on the stage of clinical manifestations. Medicamentous treatment includes giving antirheumatics (nonsteroidal), antiflogistics (salicylates) and mionolitics per os or parenterally, whereas local antirheumatic balms or corticosteroid drugs are applied either intraarticularly or locally in combination with anesthetics. Such local intraarticular therapy is not recommended for adolescent patients, because it can cause processes of joint cartilage destruction. Lately, the routine procedure assumes intraarticular application of plasma enhanced by thrombocytes (platelet rich plasma (PRP) or Orthokin) and stem cells taken from the bone marrow aspiration (Bone marrow aspiration concentrate - BMAC). The bone marrow taken from the pelvic crest or tibia upper end has a great potential in healing cartilage and bone flaw as it has a significant number of mesenchymal cells and several growth factors. Platelet rich plasma also contains several growth factors released from thrombocytes which can also stimulate mesenchymal bone marrow cells to multiply and differentiate in other tissues [3-5].

Physical therapy is simultaneously combined with medicamentous treatment and involves kinesitherapy, hydrotherapy, various electrotherapy procedures. The main goal of this therapy is preservation i.e. restoration of joint and spine functions (dynamic balance). It needs to be emphasized that physical treatment is applied only after alleviating the most painful, initial phase of disease.

Surgical (orthopedic) treatment is applied only when a conservative treatment is unable to ease subjective discomfort and amount to improvement of functional abilities of diseased body part. At least six months of persistent physical therapy treatment is necessary,

and if it fails to achieve some subjective improvement, then some of surgical methods are applied.

Arthroplasty - is a surgical procedure during which severely degenerative altered joints, where destruction of articular hip surfaces is present, are replaced with implants. Implantation of mostly total prostheses adds to the disappearance of pain, repairing of joint function which results in the improvement of living and working activities. There are some limiting factors because all implants represent foreign bodies in human organism, so there is the question of biomechanical and biological acceptance of prostheses, as well as of the "survival" length of embedded implants. Recently, technological progress and improvement of prostheses, tolerance period and implant functionality is growing, which is especially true for hip and knee prostheses. Total hip replacement is believed to be one of the most successful orthopedic interventions [6, 7]. In cases when only femoral part of the joint, i.e. the head of the femur is replaced we speak about hemiarthroplasty.

The first prosthesis of femur head made of ivory was implanted in 1891 by Professor Themistocles Glück in Germany, when he replaced the femur head dilapidated due to tuberculous process. In 1925 the American surgeon Marius Smith-Petersen [8] introduced the mould arthroplasty made of glass, and the first who used "metal-on-metal" prostheses was English surgeon George McKee in 1953, with a high survival rate, i.e. the survival rate amounted to 74% after 28 years. The father of modern arthroplasty is an orthopedic surgeon Sir John Charnley who designed his prosthesis in the early sixties of the last century, on whose principles all modern total hip prostheses are based [9].

Technological progress and improvement of implants all over the world, both in developed countries and in our country as well, have led to an enormous increase in the replacement of degenerative altered hips during last thirty years. In the last decade, here as well as throughout developed countries of Europe and America, the number of both primary and revision arthroplasty procedures grew rapidly [10]. The reasons for this lie in the fact that a long period from previous primary arthroplasty procedures has passed up to now; the life span has extended, and the number of local complications such as prostheses luxation, infections, etc also grows with an increase in the number of procedures.

Depending on the loss of bone mass, i.e. defects in the bone continuity, age, living requirements, three basic types of prosthesis are routinely applied nowadays: cemented, where a contact of both components with a bone is accomplished by means of cement; cementless, where there is a contact of metal components directly to the bone, and hybrid, where usually a metal cap is implanted into acetabulum at the same time cementing the femoral part of prosthesis in the femoral canal. It is possible to have a case when polyethylene cap is cemented in the acetabulum and cementless component of the prosthesis is implanted in the femur, i.e. there is a

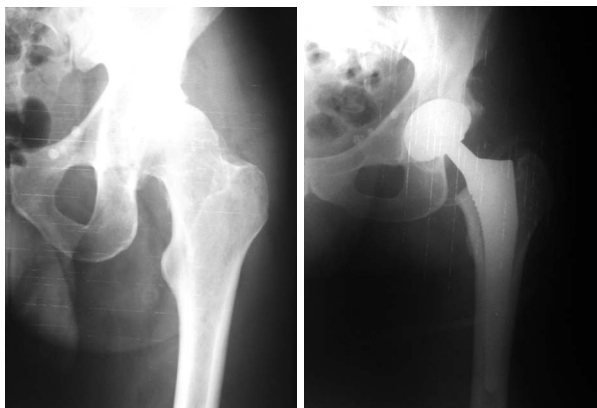

Figure 1. Cementless hip prosthesis
Slika 1. Bescementna proteza kuka

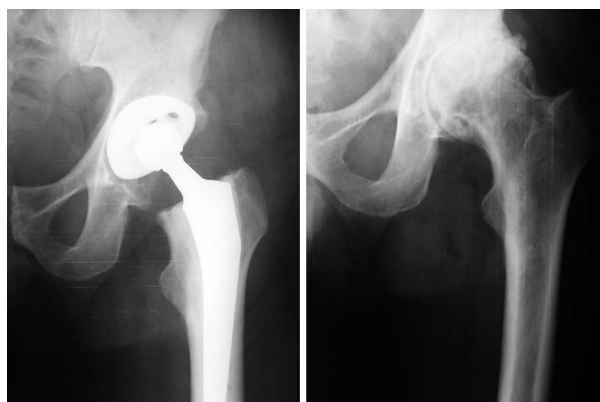


Figure 2. Hybrid hip prosthesis
Slika 2. Hibridna proteza kuka

direct contact between metal-bone when it is called contra-hybrid. Depending on the contact of acetabular and femoral components (femoral head) there are the following types of prostheses: metal-polyethylene, metal - metal, ceramic - ceramic and ceramic-polyethylene [11–14]. Two types of prosthesis are used for hemiarthroplasty of the hip joint: Moore's prosthesis and biarticular prosthesis.

Generally speaking, cementless prostheses are implanted in the patients up to 65 years of age where quality of bone tissue is good according to the Rulebook of Serbian Republic Fund of Health Insurance (**Figure 1**). Hybrid total prostheses are implanted in the patients between the ages of 65 and 75 years, and cemented ones in the patients over the age of 75 years (**Figure 2**). Hemiarthroplasty is applied in cases of elderly patients (over 75 years of age) with fracture of the femoral neck where the expected lifespan is not long.

Prof. Dr. M. Došen performed the first total hip replacement surgery at the *Department of Orthopedic Surgery and Traumatology* in Novi Sad in 1970 and it was among the first in the Socialist Federal Republic of Yugoslavia [15]. Primary and revision arthroplasty procedures are routinely performed on a daily basis, and thousands of cases have been treated ever since. Out of 4,661 arthroplasty procedures performed at this *Department* in the period from 2006 to 2015, 1,516 were cemented prostheses, 1,389 were cementless and 475 were hybrid prostheses. In addition, 470 revision hip arthroplasty procedures were performed and five segmental (tumor) prostheses were implanted. Due to the fracture of the femoral neck 819 hemiarthroplasty procedures were done (765 Moore prostheses and 54 biarticular ones).

It has been possible to perform such a large number of arthroplasty procedures thanks to long tradition in performing these procedures, well-educated and skillful orthopedic surgeons, operating room and ward nurses as well as physiotherapists and the whole staff taking part in the treatment of such patients and high quality of pre-, peri- and post-operative anesthesia. During the majority of arthroplasty procedures, especially the revision ones, cell saver was used because of heavy blood

loss over a certain period of time, and thus most of the patients who underwent arthroplasty procedures at the *Department* did not receive blood transfusion but only their own processed blood [16]. The patients also received multimodal postoperative analgesia together with local application of conductive blocks as a routine which significantly contributed to their fast and efficient recovery [17]. Good peri- and postoperative care by anesthesiologists allows some orthopedic surgeons to apply a concept of fast recovery ("fast tracking") to their patients with total knee and hip replacement, which means early verticalization of the patient, i.e. a few hours after the intervention. Most surgical patients at the *Department* are verticalized and start with early physical treatment a day after surgery.

The *Department of Orthopedic Surgery and Traumatology, Clinical Centre of Vojvodina* in Novi Sad differs from the majority of its counterparts in the Republic of Serbia because we perform arthroplasty procedures, mini invasive surgery and computer-assisted surgery to hip joint, i.e. navigational surgery. Mini invasive surgery technique has been applied as a routine at the *Department* for some time already, and in combination with good peri- and postoperative protocol and forced verticalization it results in a shorter hospitalization and faster recovery after implantation of both total hip joint and knee prostheses. Several computer assisted hip and knee arthroplasty procedures that were performed at the *Department* proved to be a good method, but due to high price of equipment and the length of surgery, they have not become part of routine procedures [18, 19].

During last fifteen years, the number of revision arthroplasty procedures has grown rapidly both here and throughout developed countries of Europe and America. The reason for this lies in the fact that up to now a long period from previous primary arthroplasty procedures has passed, life span has extended, and the higher number of procedures results in the higher number of local complications such as prostheses luxation, infections, etc. [20–22]. Every repeated surgery, especially rearthroplasty procedure, is much more demanding both for a surgeon and for the patient, as it is accompanied with a lot of local and general

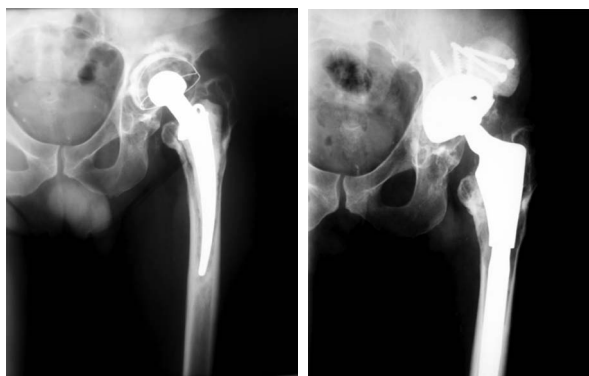

Figure 3. Revision hip replacement
Slika 3. Revizionna proteza kuka

problems. This particularly applies to cases when there is a loss of bone mass no matter whether it is situated on the ilium or on thigh bone. This type of surgery is long-lasting, blood loss is huge and the recovery itself, i.e. hospitalization is longer in comparison to primary hip arthroplasty. Treatment costs for these patients are significantly higher, not only because of hospitalization duration, greater consumption of all drugs, but also because of implants that are twice or four times more expensive in comparison to primary prostheses. Moreover, especially in cases where there is bone mass loss it is essential to have the bone bank.

Depending on the bone mass loss, i.e. defects in the bone continuity, age, living requirements etc. cementless and cemented prostheses or a combination of two i.e. hybrid prostheses (**Figure 3**) are implanted in revision arthroplasty. The basic principle is that only the loose part of the prosthesis is replaced. Usually it is a case of aseptic loosening of prosthetic components, although septic process develops in few cases [23–25]. In most cases it is a low-grade infection which occurs only after some time (a year or more) and it is very rarely manifested as purulent process immediately after surgery [26]. In these cases the replacement of prosthetic components can be performed in two-step or one-step procedure, the former being more frequent. If there is a bone defect, bone allografts of various forms are placed i.e. as massive ones, in the form of tiny grafts (3–5 mm) or ground ones. The number of complications after such surgical procedures is significantly higher than after primary arthroplasty procedures. Verticalization of such patients is slower, the support on the operated extremity is from full to partial, depending on the usage of bone allografts and type of implant. Rearthroplasty procedures to hip joint are a huge health and economic problem as well because of expensive implants, drugs and treatments and long-term incapacity for work.

Transplantation surgery of bone and joint system is still not developed enough in our country, but nevertheless it is applied in revision hip and knee arthroplasty procedures, in reconstructive surgeries on ligaments and tendons (chronic instability of knee and shoulder joint, tendon defects), in tumor and spinal surgery, in joint arthrodeses etc. Non vascularized transplants are often applied routinely, which are associated with problems such as revascularization and remodeling of bone, ligament and tendon tissue since these processes should be synchronous and follow one another. In developed industrialized countries allotransplants from bone banks have been used routinely for more than three decades now.

Immune response of the human body to the bone and tendon transplants is very moderate due to a well-known fact that these tissues are in condition of hypovascularity and have weak antigenic properties. The problem of transplant rejection is therefore manifested to a much lesser extent than in other branches of transplant surgery. Some studies have shown that immunological processes that occur in transplantation of bone tissue are predominantly of cellular type, whereas it is still not clear what causes a blockade of humoral immunity.

Due to weak antigenic properties of tissues during these procedures in routine usage it is not necessary to perform a detailed tissue-typing, or to apply immunosuppressive therapy, but it is enough to determine the blood compatibility. The success of transplant surgery in osteoarticular pathology depends also on the size of transplant itself, while it is a well-known fact that faster revascularization and remodeling are achieved with smaller grafts. On the other hand, larger grafts provide an opportunity of easier implantation and fixation, thus satisfying basic biomechanical conditions, which adds to faster and better physical treatment i.e. postoperative results [27].

Having in mind the growing demand for allografts, the necessity of forming bone banks is imposed. Their main task is to provide sufficient quantities of clinically safe bone and ligamentous allotransplants having adequate biological and biomechanical qualities essential for their clinical implementation [28]. Allotransplants from a bone bank must be free of all potentially harmful, transmissible diseases, but at the same time they must preserve their osteogenic potential and mechanical hardness, necessary for a successful clinical implementation of bone allotransplant [29]. In order to avoid transmission of bacterial or fungal infections from allotransplant donor to a recipient, while working in a bone bank the standard of American Association of Tissue Banks (AATB) or European Association of Musculo-Skeletal Transplantation (EAMST)/European Association of Tissue banks (EATB) must be strictly followed, which means cautious donor selection, compliance with strict rules when taking, storing and implanting allotransplants [30, 31]. There is a prevailing opinion that the application of fresh frozen or frozen lyophilized grafts, together with previous virological and bacteriological examination of donor and graft itself, provides best postoperative results.

The Department of Orthopedic Surgery and Traumatology, Clinical Centre of Vojvodina, Novi Sad, started to apply massive cortico-spongioid allografts in 1992. The entire project of the bone bank, with the permission of Ethics committee at the time, was conducted by Prof. Dr Aleksandar Jovanović with his assistants Dr. M. Milankov and Dr. D. Savić. The bone bank was established in 2008 at the Department of Orthopedic Surgery and Traumatology by providing a deep freezer with temperature of -80°C and all necessary equipment, when transplant program came into operation at the Clinical Centre of Vojvodina in Novi Sad. By establishing the bone bank, bone and ligamentous allotransplants, both from cadaver donors (within transplant program) and alive donors (head of the femur after arthroplasty procedures to hip joint), have been applied for the last 8 years. During the last 15 years, 671 revision hip arthroplasty procedures have been performed at the Department, mainly due to loosening of prosthesis components and in cases of bone mass loss. The demand for allografts has constantly been on the rise so there is a need to incorporate more people in organ donation and to improve the transplant program in the country.

References

1. Yoshimura N, Muraki S, Nakamura K, Tanaka S. Epidemiology of the locomotive syndrome: The Research on Osteoarthritis/ Osteoporosis Against Disability study 2005-2015. *JAMA Pediatr.* 2016;170(10):979-86.
2. Martel-Pelletier J, Barr AJ, Cicuttini FM, Conaghan PG, Cooper C, Goldring MB, et al. Osteoarthritis. *Nat Rev Dis Primers.* 2016;2:16072.
3. Smyth NA, Murawski CD, Haleem AM, Hannon CP, Savage-Elliott I, Kennedy JG. Establishing proof of concept: platelet-rich plasma and bone marrow aspirate concentrate may improve cartilage repair following surgical treatment for osteochondral lesions of the talus. *World J Orthop.* 2012;3(7):101-8.
4. Zhong W, Sumita Y, Ohba S, Kawasaki T, Nagai K, Ma G, Asahina I. In vivo comparison of the bone regeneration capability of human bone marrow concentrates vs. platelet-rich plasma. *PLoS One.* 2012;7(7):e40833.
5. Lee DH, Ryu KJ, Kim JW, Kang KC, Choi YR. Bone marrow aspirate concentrate and platelet-rich plasma enhanced bone healing in distraction osteogenesis of the tibia. *Clin Orthop Relat Res.* 2014;472(12):3789-97.
6. Callaghan JJ, Albright JC, Goetz DD, et al. Charnley total hip arthroplasty with cement. Minimum twenty-five-year follow-up. *J Bone Joint Surg Am.* 2000;82:487-97.
7. Learmonth ID, Young C, Rorabeck C. The operation of the century: total hip replacement. *Lancet.* 2007;370:1508-19.
8. Smith-Petersen MN. The classic: evolution of mould arthroplasty of the hip joint. *J Bone Joint Surg.* 30B:L:59, 1948. *Clin Orthop Relat Res.* 1978;(134):5-11.
9. Charnley J. Arthroplasty of the hip: a new operation. *Lancet.* 1961;1:1129-32.
10. Havelin LI, Engesaeter LB, Espehaug B, et al. The Norwegian Arthroplasty Register: 11 years and 73,000 arthroplasties. *Acta Orthop Scand.* 2000;71:337-53.
11. Ni GX, Lu WW, Chiu KY, Fong DYT. Review article: cemented or uncemented femoral component in primary total hip replacement? A review from a clinical and radiological perspective. *J Orthop Surg.* 2005;13:96-105.
12. Sandhu HS, Middleton RG. Controversial topics in orthopaedics: ceramic-on-ceramic. *Ann R Coll Surg Engl.* 2005;87:415-6.
13. Cuckler JM. The rationale for metal-on-metal total hip arthroplasty. *Clin Orthop Relat Res.* 2005;441:132-6.
14. Bierbaum BE, Nairus J, Kuesis D, et al. Ceramic-on-ceramic bearings in total hip arthroplasty. *Clin Orthop Relat Res.* 2002;405:158-63.
15. Mikić Ž. Razvoj ortopedije i osnivanje Klinike za ortopedsku hirurgiju i traumatologiju u Novom Sadu. *Med Pregl.* 1998;51(9-10):457-68.
16. Lukić Šarkanović M, Gvozdrenović Lj, Savić D, Ilić MP, Jovanović G. Autologous blood transfusion in total knee replacement surgery. *Vojno Sanit Pregl.* 2013;70(3):274-8.
17. Lukić Šarkanović M, Lazetić A, Lalić I, Gvozdrenović Lj, Savić D. Multimodalni perioperativni tretman aloartroplastike kuka i kolena. I Kongres ortopeda i traumatologa Bosne i Hercegovine sa međunarodnim ucescem. 2014 Sep 18-21; Jahorina, BiH.
18. Reininga IH, Zijlstra W, Wagenmakers R, et al. Minimally invasive and computer-navigated total hip arthroplasty: a qualitative and systematic review of the literature. *BMC Musculoskelet Disord.* 2010;11:92-92.
19. Callaghan J. Skeptical perspectives on minimally invasive total hip arthroplasty. *J Bone Joint Surg Am.* 2006;85:2242-3.
20. Bozic K, Kurtz S, Lau E, Ong K, Chiu V, Vail T, et al. The Epidemiology of revision total knee arthroplasty in the United States. *Clin Orthop Relat Res.* 2010;468(1):45-51.
21. Archibeck MJ, Jacobs JJ, Roebuck KA, Glant TT. The basic science of periprosthetic osteolysis. *Instr Course Lect.* 2001;50:185-95.
22. Dale H, Hallan G, Espehaug B, Havelin L, Engesaeter L. Increasing risk of revision due to deep infection after hip arthroplasty: a study on 97,344 primary total hip replacements in the Norwegian Arthroplasty Register from 1987 to 2007. *Acta Orthop.* 2009;80(6):639-45.
23. Briant-Evans T, Veeramootoo D, Tsiridis E, Hubble M. Cement-in-cement stem revision for Vancouver type B periprosthetic femoral fractures after total hip arthroplasty: a 3-year follow-up of 23 cases. *Acta Orthop.* 2009;80(5):548-52.
24. Egmond N, De Kam D, Gardeniers J, Schreurs W. Revisions of extensive acetabular defects with impaction grafting and a cement cup. *Clin Orthop Relat Res.* 2011;469(2):562-73.
25. Huo M, Friedlaender E, Salvati E. Bone graft and total hip arthroplasty. A review. *J Arthroplasty.* 1992;7(2):109-20.
26. Tomford W, Starkweather J, Goldman H. A study of the clinical incidence of infection in the use of banked allograft bone. *J Bone Joint Surg Am.* 1981;63(2):244-8.
27. Miljković N, Ercegan G, Harhaji V. Complications of revision hip arthroplasty using fresh bone allografts. *Med Pregl.* 2007;60(9-10):457-63.
28. Friedlaender E. Bone banking. In support of reconstructive surgery of the hip. *Clin Orthop.* 1987;225:17-21.
29. Tomford W. Current concepts review: transmission of disease through transplantation of musculoskeletal allografts. *J Bone Joint Surg Am.* 1995;77(11):1742-54.
30. American Association of Tissue Banks (AATB). Standards for tissue banking. McLean, VA: AATB; 1991.
31. European Association of Musculo-Skeletal Transplantation (EAMST)/European Association of Tissue Banks (EATB). Vienna: Common standards for musculoskeletal tissue banking; 1997.

Rad je primljen 2. 11. 2016.

Recenziran 10. 12. 2016.

Prihvaćen za štampu 16. 12. 2016.

BIBLID.0025-8105:(2016):LXIX:Suppl 1:35-40.

Clinical Center of Vojvodina, Novi Sad, Department of Orthopedics and Traumatology¹ UDK 616.728.3-002-089
 Department of Anesthesiology and Intensive Therapy² DOI: 10.2298/MPNS16S1041L
 University of Novi Sad, Faculty of Medicine³

KNEE OSTEOARTHRITIS AND ARTHROPLASTY OF THE KNEE JOINT

OSTEOARTHRITIS KOLENA I ARTROPLASTIKA KOLENA

Aleksandar LAŽETIĆ¹, Mirka LUKIĆ ŠARKANOVIĆ², Dragan SAVIĆ^{1,3},
 Oliver DULIĆ¹, Srđan RADIĆ¹ and Mirko OBRADOVIĆ^{1,3}

Summary

According to the Public Health Institute of Vojvodina one of the main causes of morbidity, invalidity and absence from work in Vojvodina are musculoskeletal diseases. Osteoarthritis is a multifactorial joint disease, with catabolism and inflammation in its background. For radiological classification of knee osteoarthritis stage Kellgren-Lawrence scale is used. It consists of five levels, from stage "0" to stage "4". The goal of osteoarthritis treatment is to reduce pain and muscle spasms, improve limb function, prevent joint contractures and train patients to function in everyday life and professional activities. The therapy is divided into conservative (medical and physical) and surgical. Arthroplasty is a surgical procedure that involves destruction of articular surfaces and replacement of degenerative joints with endoprostheses, which result in increased general and working ability. Modern endoprostheses enable a high success rate of the procedure. At the Department of Orthopedics and Traumatology, Clinical Center of Vojvodina in Novi Sad, the first knee aloarthroplasty was performed in 1989. Since then, more than 3000 knee aloarthroplasties have been done. Clinical patient evaluation was obtained through subjective status, functional evaluation and use of scoring systems. More than 80% of patients had a good or a great score.

Key words: Osteoarthritis, Knee; Knee Joint; Arthroplasty, Replacement, Knee; Treatment Outcome; Disability Evaluation; Recovery of Function

Sažetak

Iz podataka Instituta za javno zdravlje Vojvodine, jedan od glavnih uzroka morbiditeta, invaliditeta i odsustvovanja sa radnog mesta u Vojvodini jesu bolesti koštano-zglobnog sistema. Osteoartrza je bolest zglobova više uzroka, povezanih sa kaskadom kataboličkih i inflamatornih procesa. Za radiološku klasifikaciju stadijuma osteoartritisa kolena koristi se Kelgrin-Lorens (*Kellgren-Lawrence*) skala koja ima pet nivoa, od stadijuma 0 do stadijuma 4. Cilj lečenja osteoartrza je smanjenje bola i mišićnog spazma; poboljšanje funkcije ekstremiteta, sprečavanje kontraktura zglobova i osposobljavanje bolesnika. Terapija se deli na nehiruršku (medikamentnu i fizikalnu) i hiruršku. Aloarthroplastika je operativni zahvat pri kome se zglobovi, sa destrukcijom zglobnih površina, zamenjuju endoprotezama, što rezultira poboljšanjem životne i radne sposobnosti bolesnika. Savremene endoproteze omogućuju izuzetno visok procenat uspešnosti procedure. Na Klinici za ortopedsku hirurgiju i traumatologiju, Kliničkog centra Vojvodine u Novom Sadu, prva aloarthroplastična ugradnja totalne proteze kolena urađena je 1989. godine i do 2016. godine operisano je preko 3 000 artroplastika kolena. Klinička evaluacija pacijenata dobijena je na osnovu subjektivnog statusa, funkcionalnog nalaza i korišćenjem bodovnih sistema. Obradom navedenih podataka, iznad 80% pacijenata imalo je dobar i odličan rezultat.

Ključne reči: osteoartritis kolena; zglob kolena; artroplastika kolena; ishod lečenja; procena nesposobnosti

Introduction

According to the data taken from the report "Analysis of the health status of the population of Vojvodina" of the Public Health Institute of Vojvodina, one of the major causes of morbidity, disability and absence from work in Vojvodina are musculoskeletal system diseases (10.1%), primarily degenerative diseases.

Degenerative joint disease, osteoarthritis, belongs to a group of chronic processes, which are characterized by progressive deterioration of cartilage and supportive tissues and are accompanied by proliferative processes in the bone tissue of joints. Degradation process in the articular cartilage often leads to the occurrence of chronic inflammatory process of the synovial membrane.

These changes are most common in large joints, such as the hip joint and the knee joint. Due to its high incidence, osteoarthritis takes the third place in the world [1].

The real cause of degenerative changes is not fully understood. They can be divided into primary and secondary ones depending on the etiological factors.

The cause of primary arthrosis is called essential arthritis, which practically represents physiological process of aging. The impact of genetic factors, body composition and sex on more frequent occurrence of degenerative changes is considerable.

Secondary arthritis results from different static disorders, post-traumatic conditions, inflammatory processes and many other factors. Cartilage damage happens due to a change in the static-dynamic relationship between articular surfaces.

Abbreviations

HSS	– Hospital for Special Surgery
KCV	– Clinical Center of Vojvodina
KL	– Kellgren-Lawrence scale
KSS	– Knee Society Score
NRS	– Numeric Ratio Scale
NSAID	– Nonsteroidal Anti-Inflammatory Drug

Inflammation of the joints also contributes to the development of later osteoarthritic changes. Non-specific arthritis is relatively rare today, due to effective antibiotic therapy, but it may occur in certain immunodeficiency states. In recent years, there has been an increase in specific inflammation of the joints, which is explained by the deterioration of living conditions, nutrition and stress.

Besides, rheumatoid arthritis can often lead to serious osteoarthritic changes, which require long-term treatment. Untreated cases of gout, some hematological and other internal diseases may also be a cause of osteoarthritis.

Osteoarthritis is a disease of the joints whose occurrence is not related to a single factor but a combination of several causes associated with the cascade of catabolic and inflammatory processes due to the injury of articular cartilage. The changes are due to increased activity of lysosomal proteolytic enzymes, and/or reduction of the synthetic activity of chondrocytes. As the process progresses, the articular cartilage degenerates which results in fissures, erosion and loss of articular cartilage. Cysts are formed, there is destruction of the subchondral bone and the formation of new bone in the form of osteocytes. In addition, there is a release of inflammatory mediators resulting in the destruction of the joint, which is most often irreversible [2].

The main symptom in degenerative joint disease is pain. It usually occurs after a certain amount of physical exertion and can be intensified by weather changes and after exposure to cold and moisture.

The diagnosis of osteoarthritis is made based on medical history and physical examination, which is dominated by pain, joint stiffness, and difficulty in movement, in the absence of general symptoms.

Laboratory findings of patients are normal, apart from a possible increase in the number of cells in the synovial fluid. Radiological diagnostic procedures are performed in order to visualize joint changes and are not directly correlated with subjective complaints. Computed tomography and magnetic resonance imaging of the diseased joint is of great significance [3, 4].

The goal of osteoarthritis treatment is to reduce pain and muscle spasms, improve limb function, prevent joint contractures and train patients to function in everyday life and professional activities.

The therapy is divided into conservative (medical and physical) and surgical. Primarily, the patients are recommended to change their behavior and lifestyle.

One of the priorities in the prevention of osteoarthritis is to reduce body weight thus reducing burden on the affected joint. The risk of osteoarthritis in the

obese people is 4 to 7 times higher compared to the population with normal body weight.

Obesity is a major epidemiological problem of population of Vojvodina, as shown by the results of the research of the Institute of Public Health of Vojvodina.

Medical treatment involves the use of antirheumatic, antiinflammatory and myolytic drugs, administered parenterally, orally, intra-articularly and locally. Preparations of hyaluronic acid and corticosteroids can also be applied intra-articularly, but their application is not recommended in younger patients, because they can accelerate the process of destruction of articular cartilage [5, 6].

Physical therapy is carried out simultaneously with medication and includes kinesiotherapy, hydrotherapy, and a range of electrical and electromagnetic therapeutic procedures.

Surgical treatment is conducted if conservative treatment does not result in alleviation of subjective symptoms and improvement of functional ability of the affected limb.

Arthroplasty is a surgical procedure that involves destruction of articular surfaces and replacement of degenerative joints with endoprosthesis. Total joint replacement contributes to analgesia and improvement of joint functionality, which results in an improvement of working ability of patients [7, 8].

Since the beginning of the 21st century, there has been an increasing number of hip and knee arthroplasty carried out every year. According to estimates, the number of joint replacement procedures will be significantly higher in the coming decades [9].

There is almost no country in the world that does not have long waiting lists when it comes to solving advanced osteoarthritis of the joints. The goal of each joint replacement procedure is to achieve mechanical stability of the prosthetic components, biomechanical reconstruction of the joint and its functions [10].

The knee joint (*articulatio genu*) is the biggest joint in the human body with a complex structure. The stability of the knee joint is the result of the geometry of articular surfaces, menisci, ligaments, joint capsules, muscles and gravity, which allow complex movements of this joint.

Knee osteoarthritis causes the working and living disability in the elderly population, as much as heart and lung diseases combined [1]. Kellgren-Lawrence (KL) scale is used to work out radiological classification of knee osteoarthritis stage. It consists of five levels, from stage "0" to stage "4" [1].

Indications for arthroplasty of the knee include over a hundred different conditions which disrupt the normal function of a joint, because of pain, movement limitation or contractures, when all conservative methods are exhausted. Total knee joint arthroplasty is indicated in all cases of painful joints with altered function, where non-surgical treatment has not given a satisfactory result. Arthroplasty procedures should relieve pain in the knee, correct deformity, resume normal joint function and restore patient's daily activities.

An increasing number of knee arthroplasty is performed every year. The increase in the number of these procedures is far greater than in the number of hip arthroplasty. The number of knee arthroplasty procedures is expected to increase 2.5 times in the next twenty years. It is significant that the patients are female in 60% of cases of knee arthroplasty [12, 13].

There are certain differences in the structure and shape of the bone elements of the knee joint in relation to sex, which are recognized by implant manufacturers. Knee prostheses intended for female population are specially designed to adapt better to the structure and shape of the bone in order to achieve better functional results.

Contemporary endoprotheses, with proper installation, provide an extremely high success rate of the procedure, both in short-term and long-term studies. The components of total prosthesis must endure years of cyclic loading, which is at least three to five times increased in relation to the weight of the body and can occasionally be increased 10 to 12 times [14, 15].

The aim of arthroplasty is to achieve normal value of mechanical leg axis and to equalize tensions of medial and lateral joint structures. The position and orientation of the elements of the prosthesis should enable the smooth performance of the movements of flexion and extension of the knee [16].

The biomechanics of the knee joint can be reconstructed by restoring the anatomical axis, by achieving functional stability and good fixation of the implant, as well as by reconstructing the joint line. The appropriate clinical and functional result is obtained by achieving stability of the knee in flexion and extension [17].

The challenge of knee arthroplasty is a functional outcome, when a great range of motion is achieved, while preserving the kinematics of the joint, with appropriate radiographic findings. Preoperative planning results in a lower perioperative morbidity and complication rate [18].

Over time, the standards of the profession in relation to the functional results of arthroplasty have become increasingly higher, and the expectations of patients in later stages of knee osteoarthritis are getting bigger [19].

There are constant requirements for more and more efficient operating procedures in knee arthroplasty [20]. Thanks to the Internet access and availability of information, patients are better informed about the possibilities of modern arthroplasty.

There are more patients with degenerative changes who require knee arthroplasty at younger age, as well as patients in the ninth decade of life. Therefore, surgical techniques must be adapted to each patient [9].

Material and Methods

There are numerous scoring systems for clinical and radiological evaluation of the results after im-

plantation of total knee prostheses, including HSS (Hospital for Special Surgery) and KSS (Knee Society Score) scoring system or scoring system of the Knee Association of American Academy of Orthopedic Surgeons based on radiographic evaluation of the results after implantation of total knee prosthesis [21, 22].

All systems for the evaluation of the clinical results are scored on the basis of subjective and clinical status as well as functional findings by the protocol [23].

At the Department of Orthopedics and Traumatology, Clinical Center of Vojvodina (KCV) in Novi Sad, the first modern type total condylar knee prosthesis was implanted in 1989. Since then until 2016 more than 3,000 knee arthroplasty procedures were performed, including very complicated and demanding revision procedures with a complex revision endoprosthesis implantation and tumor endoprosthesis used in case of ligamentous deficit and massive bone defects. The average age of patients was 68 years and more than 60% of the patients were females.

Results

Clinical evaluation of the patients was done by means of HSS (Hospital for Special Surgery) scoring system, based on a subjective status and functional findings with the average HSS score. Preoperative and postoperative points, being 43/100 (43 of 100) and 90/100 respectively indicate a high success rate of operative treatment of knee osteoarthritis. According to the obtained data, over 80% of patients had a good or a great score.

Discussion

The concept of accelerated treatment (Fast Track, Rapid Recovery) has been increasingly implemented at the Department of Orthopedic Surgery and Traumatology of KCV in recent years in order to satisfy the requirements of the modern age for even more efficient operating procedures in knee arthroplasty. Such a concept has been used at numerous well-known orthopedic departments for about two decades [24].

A multidisciplinary approach, which also includes preoperative education and motivation of patients, while recognizing the individual characteristics of patients, enables optimal treatment and prevention of complications [20].

The role of the anesthesiologist is very important in the preoperative selection of the optimal protocol and premedication of the patients in accordance with their general condition and comorbidities [25].

The preconditions that would enable mobilization and verticalization of patients within several hours of surgery, thus reducing the length of hospital stay can be created by applying adequate, minimally invasive surgical technique, prevention of perioperative discomfort, adequate hydration of

patients, with a reduction in blood transfusion, adequate multimodal analgesia, early enteral nutrition and activation of patients, as well as prevention of thromboembolic complications [19, 26, 27].

The patient is instructed to continue treatment at home within three postoperative days. Prior to discharge, the patient is further advised regarding recovery at home to prevent readmission [25].

Such a treatment results in higher patient's satisfaction, better functional results and a lower percentage of perioperative complications. All the above mentioned reduces the overall cost of treatment and represents the best option for most patients. In addition, it contributes to reducing waiting lists for total knee replacement surgery [28].

This rapid recovery treatment has been implemented in approximately 400 patients who underwent knee arthroplasty thus far. The average age of patients was 64.5 years, 70% of the patients were women, and 69.9% were given regional (spinal) anesthesia. During surgery tranexamic acid (an antifibrinolytic) was used, consequently only 10.45% of patients received allogenic blood transfusion [27].

Postoperative analgesia was carried out by a combination of nonsteroidal anti-inflammatory drugs (NSAIDs), acetaminophen and opioid analgesics.

Adequate hydration and anti-emetics have also been provided. The intensity of postoperative pain was determined by means of the NRS (Numeric Ratio Scale).

The patients had their first postoperative meal about 6 hours after surgery, they were active (sitting, standing beside their bed and walking) 6 to 8 hours after surgery and the average length of hospital stay was 2.20 days.

Conclusion

The conclusion is based on the evaluation of subjective status and functional findings that over 80% of patients had a good and a great result, which suggests that knee arthroplasty as a method of operative treatment of knee osteoarthritis has a high success rate.

The concept of accelerated treatment (Fast Track or Rapid Recovery) is the best treatment option for most patients owing to a multidisciplinary approach, especially cooperation between the anesthesiologist and orthopedic surgeon, along with tailor-made treatment for each patient.

There is ample evidence about the benefits of accelerated treatment (Fast Track or Rapid Recovery).

References

1. Guccione AA, Felson DT, Anderson JJ, Anthony JM, Zhang Y, Wilson PW, et al. The effects of specific medical conditions on the functional limitations of elders in the Framingham Study. *Am J Public Health*. 1994;84(3):351–8.
2. Felson DT. Osteoarthritis of the knee. *N Engl J Med*. 2006;354(8):841–8.
3. Emrani PS, Katz JN, Kessler CL, Reichmann WM, Wright EA, McAlindon TE, et al. Joint space narrowing and Kellgren-Lawrence progression in knee osteoarthritis: an analytic literature synthesis. *Osteoarthritis Cartilage* 2008;16(8):873–82.
4. Njagalj V, Kovačev N, Rašović P, Semnic R, Milankov M. Magnetic resonance imaging comparison of lateral collateral ligament and patellar tendon length. *Med Pregl*. 2014;67(7-8):197–201.
5. Taylor N. Nonsurgical management of osteoarthritis knee pain in the older adult. *Clin Geriatr Med*. 2017;33(1):41–51
6. Jacobs JJ, Jevsevar DS, Brown GA, Cummins DS. AAOS osteoarthritis guideline: Transparency and credibility. *Arthroscopy*. 2014;30(6):656–8.
7. Attfield SF, Wilton TJ, Pratt DJ, Sambatakakis A. Soft-tissue balance and recovery of proprioception after total knee replacement. *J Bone Joint Surg Br*. 1996;78:540–5.
8. Gojković Z. Implantation of the knee joint endoprosthesis. *Med Pregl*. 2015;68(11-12):367–9.
9. Robertsson O, Dunbar MJ, Knutson K, Lidgren L. Past incidence and future demand for knee arthroplasty in Sweden: a report from the Swedish Knee Arthroplasty Register regarding the effect of past and future population changes on the number of arthroplasties performed. *Acta Orthop Scand*. 2000;71(4):376–80.
10. Wells VM, Hearn TC, McCaul KA, Anderton SM, Wigg AER, Graves SE. Changing incidence of primary total hip arthroplasty and total knee arthroplasty for primary osteoarthritis. *J Arthroplasty*. 2002;17(3):267–73.
11. Kellgren JH, Lawrence JS. Radiological assessment of osteo-arthrosis. *Ann Rheum Dis*. 1957;16(4):494–502.
12. Mehrotra C, Remington PL, Naimi TS, Washington W, Miller R. Trends in total knee replacement surgeries and implications for public health, 1990–2000. *Public Health Rep*. 2005;120(3):278–82.
13. Kurtz S, Mowat F, Ong K, Chan N, Lau E, Halpern M. Prevalence of primary and revision total hip and knee arthroplasty in the United States from 1990 through 2002. *J Bone Joint Surg Am*. 2005;87(7):1487–97.
14. Vince KG, Insall JN. Long-term results of cemented total knee arthroplasty. *Orthop Clin North Am*. 1988;19(3):575–80.
15. Ranawat CS, Flynn WF Jr, Saddler S, Hansrai KK, Maynard MJ. Long-term results of the total condylar knee arthroplasty: a 15-year survivorship study. *Clin Orthop Relat Res*. 1993;286:94–102.
16. Scuderi GR, Insall JN. Total knee arthroplasty. *Clin Orthop*. 1992;276:26.
17. Dorr LD, Boiardo RA. Technical considerations in total knee arthroplasty. *Clin Orthop Relat Res*. 1986;205:5–11.
18. Dennis DA, Berry DJ, Engh G, Fehring T, MacDonald SJ, Rosenberg AG, et al. Revision total knee arthroplasty. *J Am Acad Orthop Surg*. 2008;16(8):442–54.
19. Kehlet H, Søballe K. Fast-track hip and knee replacement: what are the issues? *Acta Orthop*. 2010;81(3):271–2.
20. Kehlet H, Thienpont E. Fast-track knee arthroplasty: status and future challenges. *Knee*. 2013;20 Suppl 1:S29–33.
21. Bach CM, Nogler M, Steingruber IE, Ogon M, Wimmer C, Göbel G, et al. Scoring systems in total knee arthroplasty. *Clin Orthop Relat Res*. 2002;(399):184–96.

22. Frederick C, Ewald MD, on behalf of The Knee Society. The Knee Society Total Knee Arthroplasty Roentgenographic Evaluation and Scoring System (Used with permission by Lippincott Williams & Wilkins. This article originally appeared in *Clin Orthop*. 1989;(248):9-12).

23. Harhai V, Subašić S, Ninković S, Lalić I, Salamon T, Ristić V. The impact of combined meniscus tear on quality of life after anterior cruciate ligament reconstruction. *Med Pregl*. 2016;69(5-6):153-9.

24. Larsen K, Hansen T, Søballe K, Kehlet H. Patient-reported outcome after fast-track knee arthroplasty. *Knee Surg Sports Traumatol Arthrosc*. 2012;20(6):1128-35.

25. Husted H. Fast-track hip and knee arthroplasty: clinical and organizational aspects. *Acta Orthop Suppl*. 2012;83(346):1-39.

Rad je primljen 2. 11. 2016.

Recenziran 10. 12. 2016.

Prihvaćen za štampu 16. 12. 2016.

BIBLID.0025-8105:(2016):LXIX:Suppl 1:41-45.

26. Bāthis H, Perlick L, Blum C, Lüring C, Perlick C, Grikka J. Midvastus approach in total knee arthroplasty: a randomized, double-blinded study on early rehabilitation. *Knee Surg Sports Traumatol Arthrosc*. 2005;13:545-50.

27. Nielsen CS, Jans Ø, Ørsnes T, Foss NB, Troelsen A, Husted H. Combined intra-articular and intravenous tranexamic acid reduces blood loss in total knee arthroplasty: a randomized, double-blind, placebo-controlled trial. *J Bone Joint Surg Am*. 2016;98(10):835-41.

28. Tešić I, Sekulić J, Arbutinov V, Popov D, Velisavljev D. Autologous blood transfusion in patients undergoing hip replacement surgery. *Med Pregl*. 2014;67(3-4):101-7.



Ward A of the Department of Orthopedic Surgery and Traumatology
A Odeljenje Klinike za ortopedsku hirurgiju i traumatologiju

Clinical Center of Vojvodina, Novi Sad
Department of Orthopedics and Traumatology¹
University of Novi Sad, Faculty of Medicine²

UDK 616.727.2-089.84
DOI: 10.2298/MPNS16S1047N

THE USE OF PARTIAL PROSTHESIS IN SHOULDER SURGERY

PRIMENA PARCIJALNIH PROTEZA U HIRURGIJI RAMENA

Srđan NINKOVIĆ^{1,2}, Slađana RADOSAVLJEVIĆ², Vladimir HARHAJI^{1,2}, Ivica LALIĆ^{1,2},
Nataša JANJIĆ^{1,2} and Mirko OBRADOVIĆ^{1,2}

Summary

Introduction. Indications for the use of partial shoulder prosthesis are dislocated four-part fractures and multi-part and four-part fractures-dislocations, impressive fractures of the humeral head (including involvement of more than 40% of the articular surface) and “head splitting” fractures of humerus. The aim of this study was to present the results of the application of partial shoulder prosthesis at the Department of Orthopedic Surgery and Traumatology, Clinical Center of Vojvodina in Novi Sad and identify risk groups among the participants. **Material and Methods.** The study, which was retrospective, included 22 patients who had undergone the partial shoulder arthroplasty in the period from 2005 to 2015 at the Department of Orthopedic Surgery and Traumatology, Clinical Center of Vojvodina. The functional results were evaluated on the basis of the Constant Shoulder Score. **Results.** The study sample consisted of 15 women and 7 men, whose mean age was 64.9 ± 9.1 years. The average time from the injury to surgery was 13.3 days. According to the Constant scoring scale, the result was excellent in 6 (27%) patients, good in 3 (14%), fair in 7 (32%), and poor in 6 (27%) participants. 75% of participants said they were satisfied with the results of the operation. **Conclusion.** Partial shoulder prosthesis gives good functional results and allows resumption of activities of daily living. Better results were obtained within the subjective segments (pain, daily activities, vitality), which points out a greater subjective patient’s satisfaction in relation to the measured functional outcome.

Key words: Shoulder Joint; Dislocations; Arthroplasty, Replacement; Prostheses and Implants; Range of Motion, Articular; Treatment Outcome; Recovery of Function; Patient Satisfaction; Pain Measurement

Introduction

Prosthesis is an artificial shoulder joint which partially or completely replaces the diseased or injured joint. The first written data on the application of prosthesis in the human population dates back to 1893, when Jules Émile Péan [1] used an implant of platinum and rubber by a Parisian dentist Porter Michaelsdesign [2]. The largest contribution to the development of shoulder prosthesis was given by Neer [3]. He designed the partial Neer prosthesis in 1973, which is still applied but with certain modifications [3]. Indications for the use of partial shoulder prosthesis are dislocated four-

Sažetak

Uvod. Indikacije za primenu parcijalnih proteza ramena su četvorodelni dislokovani prelomi i četvorodelni i višedelni prelomi – iščašenja, impresivni prelomi glave nadlaktatne kosti (sa zahvaćenošću više od 40% zglobne površine) i *head splitting* prelomi gornjeg okrajka nadlaktice. Cilj rada bio je da se prikažu rezultati primene parcijalnih proteza ramena na Klinici za ortopedsku hirurgiju i traumatologiju Kliničkog centra Vojvodine u Novom Sadu i utvrde grupe s rizikom među ispitanicima. **Materijal i metode.** Studija je bila retrospektivna. Ispitivana su 22 pacijenta kojima je primenjena parcijalna proteza ramena u periodu 2005–2015. godine na Klinici za ortopedsku hirurgiju i traumatologiju Kliničkog centra Vojvodine. Funkcionalni rezultati su procenjavani na osnovu Konstatovog skora. **Rezultati.** Među ispitanicima se nalazilo 15 žena i sedam muškaraca. Prosečna starost ispitanika bila je $64,9 \pm 9,1$ godina. Prosečno vreme od povrede do operacije je 13,3 dana. Prema Konstantovoj bodovnoj skali šest (27%) ispitanika imalo je odličan rezultat, dobar rezultat tri (14%), zadovoljavajući sedam (32%), a loš rezultat Konstantove skale imalo je šest (27%) ispitanika. Da je zadovoljno rezultatima operacije izjavilo je 75% ispitanika. **Zaključak.** Parcijalne proteze ramenog zgloba daju dobre funkcionalne rezultate i omogućavaju vraćanje aktivnostima dnevnog života. Bolji rezultati dobijeni su u okviru subjektivnih segmenata (bol, svakodnevne aktivnosti, vitalnost) što govori o većem subjektivnom zadovoljstvu pacijenata u odnosu na izmereni funkcionalni rezultat.

Glavne reči: rameni zglob; dislokacije; artroplastika; proteze i implantati; opseg pokreta zgloba; ishod lečenja; zadovoljstvo pacijenta; merenje bola

part fractures and multi-part and four-part fractures-dislocations, impressive fractures of the humeral head (including involvement of more than 40% of the articular surface) and “head splitting” fractures of humerus [3].

Results of partial shoulder prosthesis depend on the precise surgical technique, condition of the rotator cuff musculature, adequate soft tissue tension, rehabilitation and motivation of patients [4]. Delaying surgery for more than 14 days leads to the initial occurrence of scar, contracture of muscles, osteoporosis and increased risk of infection.

Abbreviations

CT – computed tomography
 BMI – Body mass index

This study was aimed at identifying the risk groups among the participants and functional assessment of results of partial prosthesis in shoulder surgery.

Material and Methods

The study was approved by the Ethics Committee of the Faculty of Medicine, University of Novi Sad and the Ethics Committee of the Clinical Center of Vojvodina in Novi Sad. The study participants gave their consent to participate in the study after the detailed explanation of the planned procedure.

Out of 26 patients who had the partial shoulder prosthesis implanted at the Department of Orthopedic Surgery and Traumatology, Clinical Center of Vojvodina in the period from 2005 to 2015, 22 agreed to be included in the study sample. Average follow-up time was 38.8 months. Fracture of the proximal humerus was the indication for the use of partial prosthesis in all cases, of which 19 were “head splitting” and 3 were four-part fractures-luxation (**Figures 1 and 2**). The diagnosis was based on clinical examination, a series of x-rays and computed tomography (CT). The deltoid pectoral approach was used in all patients and the partial prosthesis was implanted to all of them (Lima Corporate, SMR system). After surgery, the patients were immobilized in a neutral position, placing the upper arm in the 45° abduction and 90° flexion during 6 weeks. Antibiotic prophylaxis was applied for a period of 48 hours by parenteral administration of the first generation cephalosporins. Control radiograph (**Figure 3**) recordings were made 10 days, 3 weeks, 6 weeks, 3 months and 6 months after surgery. Rehabilitation program, which was individual for each patient, was initiated immediately after surgical treatment.

The Constant shoulder score was used to assess the results of operations. The range of motion was measured by means of goniometer, while the force of withdrawal was measured according to the criteria based on the number of kilograms that the participant may hold in the position with the upper arm at 90° abduction (the shoulder of a 25-year old healthy man can withstand 12.5 kilograms without

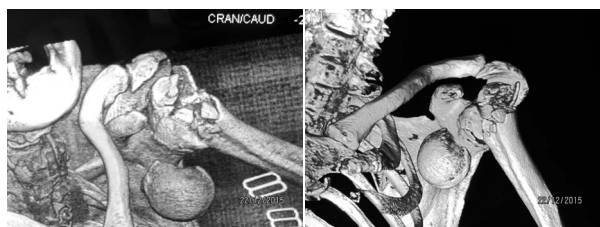major difficulties; this value is taken as the highest and carries 25 points). The Constant shoulder score consists of four parts: the presence and intensity of pain, activity level, range of motion and power of abduction. The maximum score for the presence and intensity of pain is 15 points, 20 points for the activity level, 40 points for the range of motion and 25 points for the strength of abduction. The difference in the Constant shoulder score between the healthy and operated limb represents a Constant's result which can be excellent (<11), good (12-20), fair (21-30) and poor (> 31).

The obtained data were analyzed by means of statistical program SPSS for Windows ver. 20. The average values and standard deviation were calculated, and χ^2 and t tests were used to determine the statistical significance.

Results

The study sample consisted of 15 (68.2%) women and 7 (31.8%) men, whose mean age was 64.9 ± 9.1 years. The oldest and the youngest participant were 75 and 40 years old, respectively. The participants between the ages 50 and 70 years made up 63.6% of the sample. Body mass index (BMI) was 28.3 ± 5.1 , placing the sample in the group of overweight.

The injury resulted from a fall in 16 (72.7%) cases, traffic accidents in 5 (22.7%) cases, and in

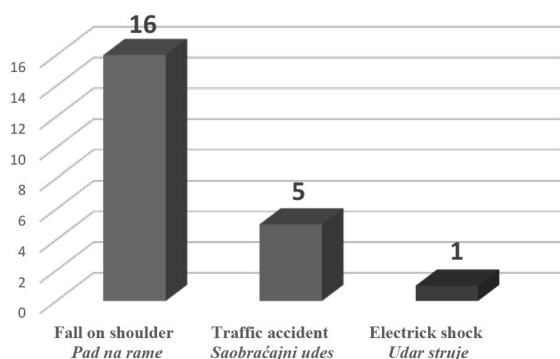


Figures 1 and 2. Multi-part fracture-dislocation of proximal humerus

Sljike 1 i 2. Višedelni prelom – iščašenje proksimalnog humerusa

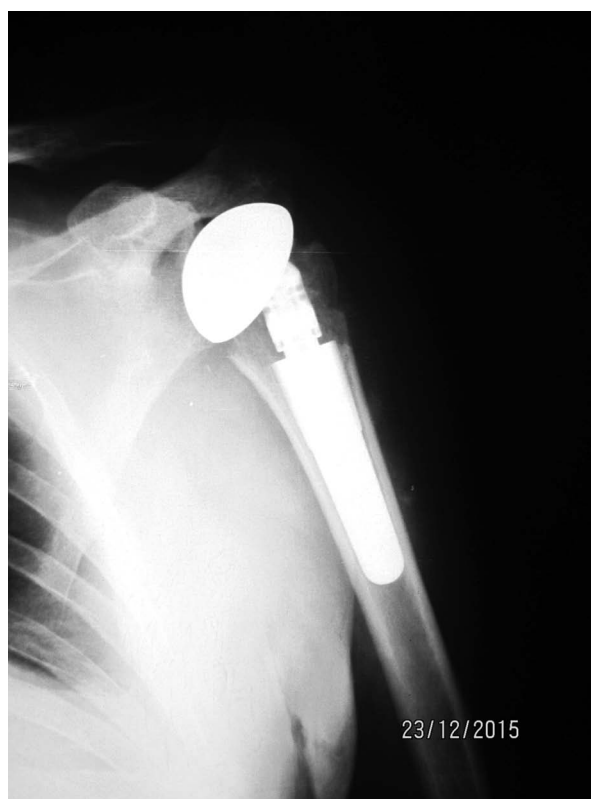

Figure 3. Postoperative X-ray
Sljika 3. Postoperativni RTG



Graph 1. Mechanism of injury
Grafikon 1. Mehanizam povrede

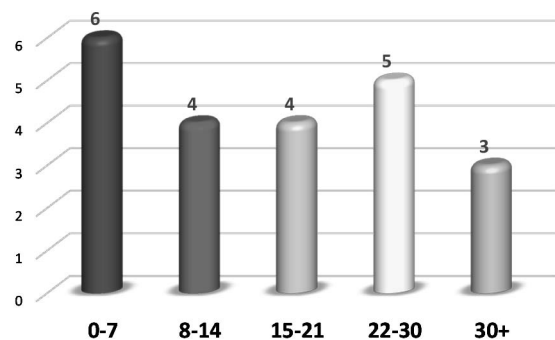
one patient it was a result of electric shock (4.6%). (Graph 1).

The time period between the injury and surgery was less than 7 days in 6 (27.3%) patients, 7 to 14 days in 4 (18.2%) patients, 15 to 21 days in 4 (18.2%) patients, 22 to 30 days in 5 (22.7%), and over 30 days in 3 (13.6%) patients (Graph 2).

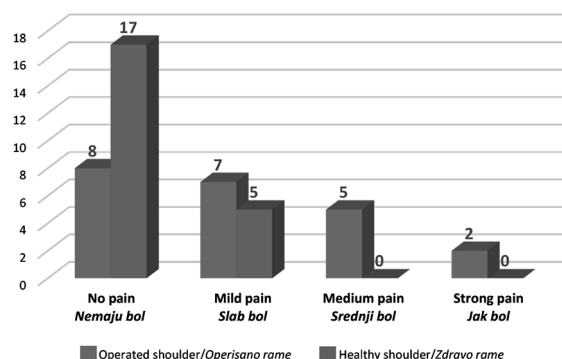
The dominant hand was affected in 60% of patients. Eight participants said that they felt no pain in the operated shoulder, 7 and 5 participants had mild pain and medium strength pain, respectively while 2 participants said that they felt strong pain. (Graph 3) 77.3% of participants said that there was no pain in healthy shoulder, while 22.7% of them felt mild pain.

After surgery 9 patients could perform all activities of daily living, 6 participants occasionally had limitations, and 7 had a permanent restriction in their daily activities. According to the Constant scoring scale, the result was excellent in 6 (27%) patients, good in 3 (14%), fair in 7 (32%), and poor in 6 (27%).

We compared the sum of Constant's scoring scale of the operated shoulder with the results of the opposite healthy shoulder, and the range of motion of the external and internal rotation of the operated and healthy shoulder. There was a statistically significant difference ($p < 0.05$) in all compared parameters. By



Graph 2. Time passed (days) between injury and surgery
Grafikon 2. Vreme protекlo (dani) između povrede i operacije



Graph 3. Shoulder pain – operated and opposite healthy one
Grafikon 3. Bol u ramenu – operisano i suprotno zdravo

comparing the range of abduction between the operated and the opposite healthy shoulder, a statistically significant difference ($p < 0.05$) was found. The range of flexion between the operated and the healthy shoulder showed a statistically significant difference ($p < 0.05$). Medium Constant's score was 65.3 ± 18.8 and 88.2 ± 9.5 for the operated shoulder and the opposite healthy shoulder, respectively. The average value of the range of motion in external rotation was $54.25^\circ \pm 21.61^\circ$ and $85.25^\circ \pm 4.72^\circ$ for the operated shoulder, and the opposite shoulder, respectively. In internal rotation, the average value of the range of motion for the operated shoulder was $58^\circ \pm 15.84^\circ$ and $78^\circ \pm 6.56^\circ$ for opposite healthy shoulder.

75% of participants said they were satisfied with the results of the operation.

Discussion

The design of shoulder prosthesis has undergone numerous changes during its development. A partial type of prosthesis was first created, which was intended for the treatment of fractures of the proximal humerus. Nowadays, there is a considerably expanded range of indications, resulting in an annual increase in the application of shoulder arthroplasty [5].

There were more female than male patients in our study sample. Such a difference in gender representation is due to the decreased bone density in women over the age of 50 years, with a consequent increase in the incidence of fractures of the proximal humerus [6, 7].

In the age structure of the participants of our study, we noticed that 63.6% of them were between the ages of 50 and 70 years. These data coincide with the literature, where the fracture of the proximal humerus usually affects the age group of 50 to 70 years, and goes up with each successive decade [8, 9]. The average age of the patients in our study was 65 years. Diklić et al. [10] reported that the average age of the patients in their two-year study was 69 years. The similarity in the age structure can be explained by the partial shoulder prosthesis applied in both cases for the treatment of multi-fragmental

fractures of the proximal humerus. Chu et al. [11] have identified gender, age, obesity, osteoporosis, epilepsy, diabetes, depression, left-handed people, bad eyesight, use of alcohol and psychoactive substances as risk factors for fracture of the proximal humerus. The risk factors present in our study were gender, age and increased BMI, while other factors were excluded by anamnesis.

Since the measured body mass index (BMI) of patients was 28.3 ± 5.1 in our study, they were classified as being overweight. No data were found in research that directly compared the measured BMI in both genders with the incidence of fractures of the proximal humerus. Prieto-Alhambra et al. [12] reported in their study that overweight and obese women in menopause were 30% more prone to fractures of the proximal humerus compared to normal weight women. The mechanisms by which preobese stage and obesity lead to the development of musculoskeletal symptoms are increasing work demands and damage to blood vessels which reduces the ability to regenerate cartilage and consequent further damage [13].

In our study, the dominant hand was affected more frequently (60%). These data coincide with the observations of Diklić et al. [10] whose research showed that the dominant hand was affected in 62% of 29 patients, as well as with other literature data where a fracture of the proximal humerus frequently occurs in the dominant hand [9,14]. LeBlanc et al. [15] in their work wondered whether there was a difference in the treatment outcome of fractures of the proximal humeral treated with hemiarthroplasty in relation to whether the dominant or non-dominant arm was affected. Their study included 61 patients with a multifragmented fracture of the proximal humerus. Based on the results, the group of patients with the injured dominant arm had significantly lower objective and subjective outcomes of treatment.

The most common cause of injury in our study was fall on the shoulders. Lind et al. [16] have shown that the mechanism of injury in most cases is the result of indirect effects of force on the shoulder, which occurs as a result of the fall in 79% of cases, traffic accidents in 14% or in the course of various sports and recreational activities in 7% of cases.

One of our patients suffered a fracture of the proximal humerus as a result of electric shock. Zbucheć [17] in his case report mentions the same example. Although they are often described as the result of electroconvulsive therapy, skeletal injuries as a result of accidental electrocution are very rare. Fractures as a result of electrocution occur in places with significant and powerful muscles, such as the spine, hip and shoulder. Fracture occurs as a result of tetanic muscle contraction [17].

The patients were operated 13.3 days after the injury on average, which is consistent with data from the literature, according to which it is necessary to perform hemiarthroplasty of proximal humeral fractures within the first 14 days after injury in order to achieve the best results.

In our study, the average value of the Constant's scoring scale was 65.3. Robinson et al. [18] in their study included 138 patients who had undergone hemiarthroplasty. They calculated that the average value of Constant's scoring scale for the operated shoulder was 64, which is worse than the result of our research. Esen et al. [6] in their retrospective study involving 42 patients who had undergone hemiarthroplasty found that average value of external rotation of the treated shoulder was $73.59^\circ \pm 17.95^\circ$, while the average value of flexion was $121.30^\circ \pm 42.99^\circ$. In our study, the average flexion was 122.5° which is consistent with the results obtained by Esen et al. [19], while the average value of external rotation was 54.25° which is worse than in their research.

75% of participants said they were satisfied with the results of the operation. The difference between objective and subjective evaluations of the results of shoulder hemiarthroplasty is explained by the fact that the resulting range of motion after surgery is sufficient for normal activities of daily living because the majority of the activities are carried out at the level of scapula with the abduction of 80 to 90° and external rotation, while the smallest number of activities is performed at maximum abduction and flexion (180°) [20].

The ability to perform everyday activities combined with the loss of pain makes the patient satisfied with the results of treatment.

References

1. Lugi T. Artificial shoulder joint by Pean (1893): the facts of an exceptional intervention and the prosthetic method. *Clin Orthop Relat Res.* 1978;133:215–8.
2. Williams GR Jr, Yamaguchi K, Ramsey ML, Galatz LM, editors. *Shoulder and elbow arthroplasty*. 1st ed. Philadelphia: Lippincott Williams and Wilkins; 2005. p. 3-10.
3. Harhaji V, Ercegan G, Miljković N. Parcijalne proteze zglobova ramena- naše iskustvo. *Acta Chir Jugosl.* 2005;52(2):77-9.
4. Boileau P, Sinnerton RJ, Chuinard C, Walch G. Arthroplasty of shoulder. *J Bone Joint Surg Br.* 2006;88(5):562-75.
5. Day JS, Lau E, Ong KL, Williams GR, Ramsey ML, Kurtz SM. Prevalence and projections of total shoulder and elbow arthroplasty in the United States to 2015. *J Shoulder Elbow Surg.* 2010;19(8):1115-20.
6. Iannotti PJ, Williams GR, editors. *Disorders of the Shoulder: Diagnosis and Management*. Philadelphia: Lippincott Williams & Wilkins; 2007. p. 794-975.
7. Allen K, Golightly Y. Epidemiology of osteoarthritis: state of the evidence. 2015;27(3):276–83.
8. Frankle MA. Proximal Humerus Fractures Treatment & Management. *Medscape* [internet] 2015 May [cited 2016 Oct 15]. Available from: <http://www.//emedicine.medscape.com/article/1261320-treatment#showall>.
9. Levine WN, Marra G. *Fractures of the Shoulder Girdle*. New York: CRC Press; 2003; p. 1-29.

10. Diklić ID, Ganić ZD, Stevanović VB, Crnobarić AS, Glišić M, Blagojević ZB. Fiksacija tuberkuluma kod višedeljnih preloma proksimalnog humerusa lečenih hemiartroplastikom. *Acta Chir Jugosl.* 2010;57(1):31-4.
 11. Chu SP, Kelsey JL, Keegan TH, Sternfeld B, Prill M, Quesenberry CP, et al. Risk factors for proximal humerus fracture. *Am J Epidemiol.* 2004;160(4):360-7.
 12. Prieto-Alhambra D, Premaor MO, Fina Avilés F, Hermsilla E, Martínez-Laguna D, Carbonell-Abella C, et al. The association between fracture and obesity is site-dependent: a population-based study in postmenopausal women. *J Bone Miner Res.* 2012;27(2):294-300.
 13. Viester L, Verhagen E, Hengel K, Koppes L, Beek A, Bongers P. The relation between body mass index and musculoskeletal symptoms in the working population. *BMC Musculoskelet Disord.* 2013;14:238.
 14. Canale ST, Beate JH. *Campbell's operative orthopaedics.* 12th ed. Philadelphia: Mosby; 2012. p. 2838-50.
 15. LeBlanc JE, MacDermid JC, Faber KJ, Drosdowech DS, Athwal GS. Outcomes after hemiarthroplasty for proximal humerus fracture are significantly affected by hand dominance. *J Orthop Trauma.* 2015;29(8):379-83.
 16. Lind T, et al. The epidemiology of Fractures of the Proximal Humerus. *Arch Ortop Trauma Surg.* 1989;108:285-7.
 17. Zbucnea A. Humeral neck fracture after electrocution: case report and literature review. *Chirurgia.* 2015;110:491-3
 18. Robinson CM, Page RS, Hill RM, Sanders DL, Court-Brown CM, Wakefield AE. Primary hemiarthroplasty for treatment of proximal humeral fractures. *J Bone Joint Surg Am.* 2003;85:1215-23.
 19. Esen E, Dođramaci Y, Gültekin S, Deveci MA, Suluova F, Kanatli U, et al. Factors affecting results of patients with humeral proximal end fractures undergoing primary hemiarthroplasty: a retrospective study in 42 patients. *Injury.* 2009;40:1336-41.
 20. Ninković S, Simjanovski M, Harhaji V, Kovacev N, Janjić N, Obradović M. Surgical treatment of shoulder rotator cuff injuries. *Med Pregl.* 2014;67(7-8):239-45.
- Rad je primljen 2. 11. 2016.
Recenziran 10. 12. 2016.
Prihvaćen za štampu 16. 12. 2016.
BIBLID.0025-8105:(2016):LXIX:Suppl 1:47-51.



Ward C of the Department of Orthopedic Surgery and Traumatology
C Odeljenje Klinike za ortopedsku hirurgiju I traumatologiju

Clinical Center of Vojvodina, Novi Sad
Department of Orthopedic Surgery and Traumatology¹
University of Novi Sad, Faculty of Medicine²

UDK 616.728.3:616.758
DOI: 10.2298/MPNS16S1053V

MORPHOMETRIC CHARACTERISTICS OF THE PATELLAR TENDON

MORFOMETRIJSKE KARAKTERISTIKE LIGAMENTA ČAŠICE

Milodrag VRANJEŠ^{1,2}, Ivan VUKAŠINOVIĆ², Mirko OBRADOVIĆ^{1,2}, Mile BJELOBRK¹,
Zlatko BUDINSKI¹ and Miroslav MILANKOV^{1,2}

Summary

Introduction. The most common injuries of the knee joint are injuries of the anterior cruciate ligament. The golden standard in reconstruction of this ligament is graft bone – patellar tendon – bone. Knowing the morphometric characteristics of these ligaments is crucial for anterior cruciate ligament reconstruction. This study was aimed at determining morphometric characteristics of the patellar tendon *in vivo*, measured intraoperatively, and at defining the correlation between the obtained values and body weight, height, gender and sport activity among different groups of athletes. **Material and Methods.** This study included 184 patients suffering from anterior cruciate ligament injuries who were admitted to the Clinical Center of Vojvodina, Department of Orthopedics and Traumatology. **Results.** The patellar tendon width ranged from 28 mm to 43 mm, averaging at 32.02 mm. The length of the patellar tendon ranged from 35 mm to 62 mm, averaging at 46.34 mm. The thickness of the patellar tendon ranged from 3 mm to 6 mm, averaging at 3.78 mm. The measured results were positively and statistically relevant with the body mass, height and body mass index. **Discussion and Conclusion.** The patellar tendon was thicker, longer and wider in persons with higher values of body weight and height. Men have statistically longer, thicker and wider patellar tendon than women. There was no statistically significant difference between morphometric characteristics of the patellar tendon among professional athletes and recreational athletes, neither was there one in the obtained geometric data of the patellar tendon among tested groups of professional athletes.

Keywords: Patella; Patellar Ligament; Bone-Patellar Tendon-Bone Grafts; Morphological and Microscopic Findings; Athletes; Body Mass Index; Sex Factors; Body Weight; Body Height

Introduction

Ruptures of anterior cruciate ligament (ACL) are a significant epidemiological problem, especially because they usually occur to young people who are sport and work active [1]. The use of patellar tendon autografts for anterior cruciate ligament reconstruction is widespread and is considered to render good, reproducible clinical results [2]. The patellar tendon is the final connection of the extensor mechanism, connecting the inferior pole of the patella and the tibial tubercle. Technically, it is a ligament (connecting bone

Sažetak

Uvod. Povrede ligamenata kolenog zgloba su među najzastupljenijima u traumatologiji. Najčešće su povrede prednjeg ukrštenog ligamenta. Zlatni standard u rekonstrukciji ovog ligamenta predstavlja čašična veza sa svojim koštanim pripojima. Poznavanje morfoloških karakteristika ove veze neophodno je za adekvatno planiranje i izvođenje rekonstrukcije prednjeg ukrštenog ligamenta. Cilj istraživanja bio je utvrditi morfološke karakteristike *in vivo* ligamenta čašice, merene intraoperativno i utvrđivanje korelacije dobijenih vrednosti sa antropometrijskim merama, sportskom aktivnošću i među pojedinim grupama sportista. **Materijal i metode.** Ispitivanu grupu činila su 184 pacijenta sa povredom prednjeg ukrštenog ligamenta, koji su hospitalizovani na Klinici za ortopedsku hirurgiju i traumatologiju Kliničkog centra Vojvodine. **Rezultati.** Širina ligamenta čašice bila je od 28 mm do 43 mm, dok je prosečno 32,02 mm; dužina ligamenta čašice od 35 mm do 62 mm, prosečno 46,34 mm. Debljina ligamenta čašice bila je od 3 mm do 6 mm, prosečno 3,78 mm. Dužina, širina i debljina ligamenta čašice pozitivno su i statistički značajno povezane sa telesnom masom, visinom i BMI. **Diskusija i zaključak.** Postoji statistički značajna povezanost između dimenzija ligamenta čašice i telesne težine, visine i pola. Što osoba ima veću telesnu masu i visinu, to joj je ligament čašice deblji, duži i širi. Muškarci imaju značajno duži, deblji i širi ligament čašice od žena. Ne postoji statistički značajna razlika u morfološkim karakteristikama ligamenta čašice kod profesionalnih sportista i rekreativaca. Ne postoji statistički značajna razlika u izmerenim vrednostima dimenzija ligamenta čašice kod ispitivanih grupa profesionalnih sportista.

KLjučne reči: patela; patelarna tetiva; BTB graftovi; morfološki i mikroskopski nalazi; sportisti; indeks telesne mase; polni faktori; telesna težina; telesna visina

to bone), but it has historically been referred to as a tendon because the patella is a sesamoid bone. A bone-patellar tendon-bone (BTB) graft is the strongest of all biological substitutes; it achieves strong initial graft fixation using interference screws, allows bone-bone direct healing and offers rapid bony integration at the fixation points of the reconstruction [3, 4]. The disadvantage is graft-tunnel mismatch [5–9], a smaller cross-section area [10] and incompletely filling of the tunnel compared to the graft of the hamstring tendon [11–13]. The ACL has a “band-like” shape and does not have the same dimensions along its length [14]. The

Abbreviations

ACL	– anterior cruciate ligament
BTB	– bone-patellar tendon-bone
BMI	– body mass index


reconstructed ACL size is determined by the harvested graft size, not by the size of the native ACL insertion site [15–17]. It is important to know the geometric characteristics of the patellar tendon including the length, width, thickness, and cross-section area in order to determine the mechanical properties and achieve optimal ACL reconstruction.

The use of patellar tendon autografts for ACL reconstruction is widespread and the goal of this study was to determine morphometric characteristics of the patellar tendon (PL) *in vivo*, measured intraoperatively, and to define the correlation between the obtained values and the body weight, height, gender and sport activity among different groups of athletes.

Material and Methods


Having been given the permission by the Ethics Committee of Clinical Center a prospective study was conducted at the Department of Orthopedic Surgery and Traumatology. It included 184 patients with a torn ACL who agreed to participate in the study. The patellar tendon width, length and thickness were measured intraoperatively with a ruler.

Data were collected from the medical record, registry of patients operated at the Department of Orthopedic Surgery and Traumatology and ACL injury questionnaire. There were 154 men and 30 women (between the ages of 15 and 46 years), the average weight of the whole group was 80 kilograms (50-110 kilograms) and the average height was 181.26 cm (155-204 cm). The average body mass index (BMI) was 24.46 (from 17.72 to 32.77) (SD = 3.04). Half of the participants, i.e. 98 patients (53.3%) suffered an ACL injury while playing soccer and 25 of them (13.6%) when playing handball. According to the level of sports activity, all participants were graded to recreational athletes - 102 (55.4%), 77 (41.8%) were professional athletes and 5 were non-athletes (2.7%). The study excluded the patients already having a BTB graft, those who had an injury of the extensor mechanism of the knee (patellar fracture, rupture



Graph. 1. The width of the patellar tendon in relation to gender

Grafikon 1. Širina ligamenta čašice u odnosu na pol



Graph. 2. The length of the patellar tendon in relation to gender

Grafikon 2. Dužina ligamenta čašice u odnosu na pol

patellar tendon), a “jumper” knee and Osgood Schlatter’s disease in childhood.

The Statistical Package for the Social Sciences (SPSS) version 20.0 for Windows was used in the analysis. The results are presented in tables expressed as mean values and standard deviations. In all comparisons, $p < 0.05$ was considered a statistically significant difference.


Results

The mean patellar tendon width was 32.02 mm (28-43 mm) (SD = 2.77 mm), while the average length of patellar tendon was 46.34 mm (35-62 mm) (SD = 5.71 mm). The patellar tendon thickness ranged from 3 mm to 6 mm, averaging at 3.78 mm (SD = 0.64 mm).

The patellar tendon width was significantly and positively associated with the body weight ($r = 0.36$, $p < 0.001$) and the body height ($r = 0.52$, $p < 0.001$), the thickness of patellar tendon ($r = 0.24$, $p < 0.01$) and the length of patellar tendon ($r = 0.29$ and $p < 0.001$). The width of the patellar tendon increased with its length and the height and weight of the person.

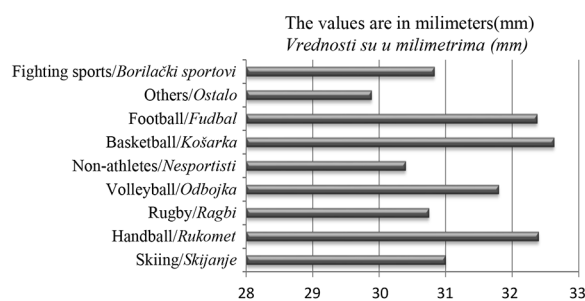
The patellar tendon thickness was significantly and positively associated with the body weight ($r = 0.23$, $p < 0.01$) and the body height ($r = 0.33$; $p < 0.001$), as well as with the width and length of the patellar tendon ($r = 0.24$, $p < 0.01$) ($r = 0.16$, $p < 0.05$), respectively. The thickness of the patellar tendon increased with its length and the height and weight of the person.

The patellar tendon length was associated with the body weight ($r = 0.23$, $p < 0.01$) and the body



Graph. 3. The thickness of patellar tendon in relation to gender

Grafikon 3. Debljina ligamenta čašice u odnosu na pol



Graph. 4. The width of the patellar tendon in relation to the sports activity

Grafikon 4. Širina ligamenta čašice u odnosu na sport-sku aktivnost

height ($r = 0.31$ and $p < 0.001$), the width ($r = 0.29$ and $p < 0.001$) and the thickness ($r = 0.16$, $p < 0.05$) of patellar tendon. All correlations were positive. The length of the patellar tendon increased with its thickness and the height and weight of the person.

The mean patellar tendon width in men and in women was 32.42 mm (SD = 2.65 mm) and 30 mm (SD = 2.53 mm), respectively. Men had significantly wider PL than women (test T 4.60; $p < 0.001$). The mean patellar tendon length in men and in women was 46.96 mm (SD = 5.6 mm) and 43.13 mm (SD = 4.24 mm), respectively. Men had a statistically significantly longer patellar tendon than women (3.462 T test $p < 0.01$). Men had a significantly thicker tendon than women. The mean patellar tendon thickness in men and in women was 3.85 mm (SD = 0.63 mm) and 3.43 mm (SD = 0.63 mm), respectively (3.35 T test $p < 0.01$) (**Graphs 1, 2 and 3**).

Although professional athletes had thicker (3.81 mm), wider (32.45 mm) and longer (46.49 mm) PL than recreational athletes (whose average PL thickness, width and length are 3.75 mm, 31.71 mm, and 45.85 mm, respectively), the obtained results were not statistically significant. In correlation to the length and width of the patellar tendon there was no statistically significant difference between the different groups of sportsmen. Handball players and football players had significantly different thickness of the patellar tendon. Handball players were found to have thicker patellar tendon. This difference was examined by T test for independent samples. The value of a T-test was 2.146, a significance level of $p < 0.05$ (**Graphs 4, 5 and 6**).

Discussion

Anterior cruciate ligament injuries are injuries that are commonly found in athlete population. In Vojvodina, which has about two million people, about 400 reconstructions of the ACL (2 reconstructions per 10,000 residents) are performed per year. As for the European countries, the most accurate data are those from Denmark, where three injuries happen to 10,000 residents per a year, the frequency of occurrence being higher among athletes [18]. These data are very similar to the data from the United States,

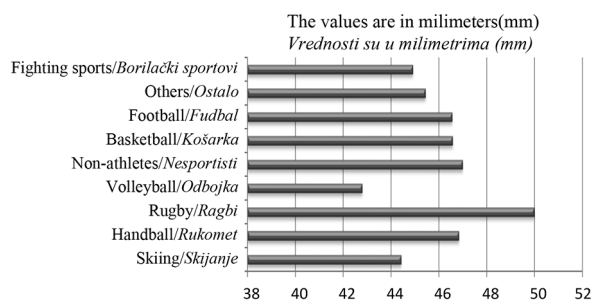
where it is estimated that injuries occur in one out of every 3,000 people in the general population [19]. The reason for this epidemiological situation certainly lies in the fact that the number of participants in sports is constantly growing on the global level. Sports activities are becoming an important part of modern life and more and more people spend their free time in recreation and entertainment.

The group at the highest risk for ACL injury is young, sports active population. The male population prevailed in this study sample (83.7% men, 16.3% women), as in many other studies dealing with the same issue [1]. Women are at 2-10 times greater risk of ACL rupture in comparison to men, depending on the type of sport [20]. The reasons for epidemic appearance of ACL injuries among women in the world lie in the anatomic differences between genders, such as the size of Q angle, increased valgus of knee joint, narrow intercondylar notch, wider pelvis, impact of estrogen hormone on ligaments during menstruation cycle, general laxity of ligaments and different time of contractions between anterior and posterior groups of thigh muscles [1].

The average age of the patients included in this study was 25 years (15–46). Nearly half (46%) of the participants belonged to the age group between 21 and 30 years since the knee injury most commonly occurs in the third decade of life [21]. Body height, weight and body mass index were evaluated in several studies. Current views suggest that higher levels of body mass index may pose a potential risk factor for non-contact injuries. Kowalchuk et al. [22] in their study found that patients with a BMI > 30 kg/m² had less successful results after ACL reconstruction than patients with a BMI in the normal range (BMI = 18.5–24.9 kg/m²).

In our study, BMI values of the participants were between 17.72 m/kg² and 32.77 m/kg². In the study Hashemi et al. [23], BMI was between 19.2 m/kg² and 44.4 m/kg². All the subjects in our study were from the territory of the Republic of Serbia and the height of the participants ranged between 155 and 204 cm (the average being 181.26 cm), as opposed to the study done by Hashemi et al. [23] which included data received from the Chinese people and they ranged from 152.4 to 182.8 (the average was 171.4 cm). These data correlate with the data from the literature stating that Europeans are generally higher than the Chinese people [24, 25].


The length of patellar tendon is observed as the distance from the top of the patella continued to the tibial tuberosity. Studies have shown the rate of BTB graft tunnel mismatch to be between 10 and 26% [6, 26, 27]. This occurs when the relative length of the bone-tendon-bone (BTB) construct exceeds the combined length of the intra-articular ACL distance and tibial tunnel length resulting in an intraoperative problem leading to extrusion or protrusion of the tibial plug graft and insecure tibial tunnel fixation with screw interference [28, 29]. According to Navali and, ACL reconstruction may be more problematic where the femoral tunnel is placed low on the lateral wall



Graph. 5. The patellar tendon length in relation to the sports activity

Grafikon 5. Dužina ligamenta čašice u odnosu na sportsku aktivnost

of the femoral notch, reducing the intra-articular graft length relative to non-anatomic vertical graft configurations. To accommodate the graft-tunnel mismatch and enable rigid fixation using interference screws, several methods have been proposed including: recession of the femoral bone plug [9], tibial tunnel bone grafting [30, 31], flipping the tibial bone plug [32, 33], graft twisting [5], changing the angle of drilling and drilling a longer tibial tunnel [8, 10]. The average length of the patellar tendon in our study was 46.34 mm (35–62 mm), and there was a significant correlation between the patellar tendon length and the patient's gender. Denti et al. [7] measured the patellar tendon length intraoperatively and reported the mean patellar tendon length of 46 mm. In an intraoperative study done by Navali and Jafarabadi [30] the patellar tendon length was between 32–61 mm, which also showed a wide range of values. Shaffer et al. [6], who also measured the patellar length intraoperatively in 34 patients, and La Prade [34], who measured patellar tendon length in 50 cadavers, described the mean patellar tendon length of 48 mm (40–63). Although MC Alister et al. [35] recommended lateral radiographs to determine the patellar tendon length, MRI is the most frequently used method. The study Hashemi et al. [23] presented the average PL length of 50.93 mm and the studies that have measured the same value in the cadaver indicate lower values of the PL length [23, 36]. This can be explained by the assumption that ligaments are subject to dehydration in cadavers, thus their length is reduced. Yoo et al. [37] measured patellar tendons using MRI in 172 knees and reported the mean patellar tendon length of 40 mm (31–52). Luk et al. [31] measured intraoperatively the length of the patellar tendon in 120 Chinese patients and reported that its mean value was 42 mm (30–54). In the study of Goldstein et al. [32] the mean patellar tendon length was 46 mm, and there was a correlation between the patient's height, gender and patellar tendon length. On the other hand, Brown et al. [38] measured the PL length in 414 knees and reported no correlation between the patient's height and patellar tendon length. The MRI study of 32 patients done by Tuncyurek et al. [39] showed that the average width of the patellar tendon was 4.5 mm and that PL length was 53 mm. Preoperative assessment of patellar tendon dimensi-



Graph. 6. The thickness of patellar tendon in relation to the sports activity

Grafikon 6. Debljina ligamenta čašice u odnosu na sportsku aktivnost

ons, especially of the length and width of PL, is significant. Chang et al. [40] made the following mathematical equation to estimate the width based on the patient's height: tendon width at middle portion (mm) = $0.202 \times \text{patient's height (cm)} - 5.07$. Lairungruang et al. [41] compared the ultimate load bearing capabilities of the normal patellar tendon (4365.59 N) to the patellar tendon after its central third was removed (2226.58 N) and concluded that taking out the central third of the patellar tendon reduced both its cross-section area and ultimate load to one half.

The width and thickness of the harvested graft affect the cross-section area of the graft [42]. If a wider graft is harvested it can lead to a weakening of the remaining part of the tendon and its subsequent rupture [42, 43].

If a BTB graft has thickness of 3 mm, the width of 10 mm and the cross-section area (CSA) of 30 mm², it is still significantly less than the cross-section area of the native ACL and/or 8 mm diameter hamstring tendon graft (with 50 mm² of cross-section area) [43]. For the average thickness of the patellar tendon graft (3–5 mm) [29, 44] and 10 mm width, the CSA will be 30–50 mm².

The width of the patellar tendon is measured in the middle of the distance from the attachment on the patella to the tibia protuberance. A patellar tendon is wider proximally than distally because the fascicles tend to converge toward the midline [45, 46]. Yoo et al. [38] measured the width of proximal and distal part, and they found it to be 30 mm and 24 mm, respectively. The mean width of patellar tendon in the middle part in our patient was 33 mm (28–43).

The central third of the patellar tendon is significantly thicker than the medial and lateral thirds [44], and may be affected by long-term sports activity [47]. On the MRI [38, 48], cadaveric [44, 45] and in our study the average thickness of the patellar tendon was found to be between 3–5 mm.

The obtained value of the width of the patellar tendon was 32.04 mm on average (ranging from 28 to 43 mm), whereas in the study Lairungruang W. [42] the average width was significantly lower, 26.75 mm, as well as the results of the study Yoo et al. (30.3 mm) [38]. Andrikoula et al. [37] reported the average value of the width of the patellar tendon to be 31.9 mm whi-

ch corresponds to our data. The patellar tendon width below 27 mm is a contraindication for the use of BTB autograft for ACL reconstruction. None of our participants had the patellar tendon under 28 mm in width.

According to the presented results, the patellar tendon length, width and thickness were significantly correlated with the dimensions of the body observed in our study (body weight, height and BMI). The correlation was the highest with the body height. There was also a statistically significant difference between the genders in favor of men for all parameters. These data are in contrast with the results of Wang [49] and Brown et al. [39] stating that the length of the ligament is not related to body weight, height and gender.

In relation to the level of the sports activities of the participants, slightly more than a half of them (56.4%) were recreational athletes, 41.8% were professional athletes, while 2.7% of participants identified themselves as non-athletes. The differences in the observed parameters of the patellar tendon and level of sporting activity have been obtained, but they were not statistically significant.

Depending on the type of sport that the participants went in for, there was the difference between the length, width and thickness of the patellar tendon, but this difference was not shown to be statistically significant except for the thickness of patellar tendon in football and handball, in favor of the football players (T test = 2.15, $p < 0.05$). Those results can be explained by the fact that this examination included a low number of

basketball players, only 19 of them, in relation to the 98 football players who participated in this study. Besides, the height of our participants was slightly below the average for the sport. Therefore, research on a larger sample might show a statistically significant difference in the dimensions of patellar tendon in different groups of athletes.

There are clearly some limitations to this study. The main limitation was the disproportionate percentage of men relative to women (83.7% man, 16.3% women). It should also be mentioned that women are less active in sport activities and consequently the number of their injuries of the ligaments relatively low. The second limitation is that the measuring with a ruler is subjectivity of the one who measures.

Conclusion

Knowing the morphometric characteristics of patellar tendon is crucial for anterior cruciate ligament reconstruction. The patellar tendon was thicker, longer and wider among persons with higher values of body weight and height. Men have the statistically longer, thicker and wider patellar tendon than women. There was no statistically significant difference between morphometric characteristics of the patellar tendon among professional athletes and recreational athletes, neither was there any between the obtained geometric data of the patellar tendon among tested groups of professional athletes (football, basketball, handball, rugby, skiing).

References

1. Ristić V, Ninković S, Harhaji V, Milankov M. Causes of anterior cruciate ligament injuries. *Med Pregl*. 2010;63(7-8):541-5.
2. Ninković S, Avramov S, Harhaji V, Obradović M, Vranješ M, Milankov M. Influence of different levels of sports activities on the quality of life after the reconstruction of anterior cruciate ligament. *Med Pregl*. 2015;68:116-21.
3. Reinhardt KR, Hetsroni I, Marx RG. Graft selection for anterior cruciate ligament reconstruction: a level I systematic review comparing failure rates and functional outcomes. *Orthop Clin North Am*. 2010;41:249-62.
4. Duquin TR, Wind WM, Fineberg MS, et al. Current trends in anterior cruciate ligament reconstruction. *J Knee Surg*. 2009;22:7-12.
5. Auge WK 2nd, Yifan K. A technique for resolution of graft-tunnel length mismatch in central third bone-patellar tendonbone anterior cruciate ligament reconstruction. *Arthroscopy*. 1999;15:877-81.
6. Shaffer B, Gow W, Tibone JE. Graft-tunnel mismatch in endoscopic anterior cruciate ligament reconstruction: a new technique of intraarticular measurement and modified graft harvesting. *Arthroscopy*. 1993;9(6):633-46.
7. Denti M, Bigoni M, Randelli P, Monteleone M, Cevenini A, Ghezzi A, et al. Graft-tunnel mismatch in endoscopic anterior cruciate ligament reconstruction intraoperative and cadaver measurement of the intra-articular graft length and the length of the patellar tendon. *Knee Surg Sports Traumatol Arthrosc*. 1998;6(3):165-8.
8. Olszewski AD, Miller MD, Ritchie JR. Ideal tibial tunnel length for endoscopic anterior cruciate ligament reconstruction. *Arthroscopy*. 1998;14(1):9-14.
9. Taylor DE, Dervin GF, Keene GC. Femoral bone plug recession in endoscopic anterior cruciate ligament reconstruction. *Arthroscopy*. 1996;12(4):513-5.
10. Milankov M, Obradović M, Vranješ M, Budinski Z. Bone-patellar tendon-bone graft preparation technique to increase cross-sectional area of the graft in anterior cruciate ligament reconstruction. *Med Pregl*. 2015;68:371-5.
11. Toritsuka Y, Horibe S, Mitsuoka T, Nakamura N, Hamada M, Shino K. Comparison between the cross-sectional area of bone-patellar tendon-bone grafts and multistranded hamstring tendon grafts obtained from the same patients *Knee Surg Sports Traumatol Arthrosc*. 2003;11:81-4.
12. Iriuchishima T, Shirakura K, Yorifuji H, Aizawa S, Fu FH. Size comparison of ACL footprint and reconstructed auto graft. *Knee Surg Sports Traumatol Arthrosc*. 2013;21:797-803.
13. Noyes FR, Butler DL, Grood ES, Zernicke RF, Hefzy MS. Biomechanical analysis of human ligament grafts used in knee-ligament repairs and reconstructions. *J Bone Joint Surg Am*. 1984;66(3):344-52.
14. Triantafyllidi E, Paschos NK, Goussia A, Barkoula NM, Exarchos DA, Matikas TE, et al. The shape and the thickness of the anterior cruciate ligament along its length in relation to the posterior cruciate ligament: a cadaveric study. *Arthroscopy*. 2013;29:1963-73.
15. Niki Y, Matsumoto H, Hakozaiki A, Kanagawa H, Toyama Y, Suda Y. Anatomic double-bundle anterior cruciate ligament reconstruction using bone-patellar tendon-bone and gracilis tendon graft: a comparative study with 2-year follow-up results of semitendinosus tendon grafts alone or semitendinosus-gracilis tendon grafts. *Arthroscopy*. 2011;27:1242-51.

16. Romanini E, D'Angelo F, De Masi S, et al. Graft selection in arthroscopic anterior cruciate ligament reconstruction. *J Orthop Traumatol.* 2010;11:211–19.
17. Shino K, Nakata K, Nakamura N, et al. Rectangular tunnel double-bundle anterior cruciate ligament reconstruction with bone-patellar tendon-bone graft to mimic natural fiber arrangement. *Arthroscopy.* 2008;24:1178–83.
18. Kvist J. Rehabilitation following anterior cruciate ligament injury: current recommendations for sports participations. *Sports Med.* 2004;34(4):269–80.
19. Silvers HJ, Mandelbaum BR. Prevention of anterior cruciate ligament injury in the female athlete. *Br J Sports Med.* 2007;41:52–9.
20. Powell J. Incidence of injury associated with playing surfaces in the National Football League 1980–1985. *Athl Training.* 1987;22:202–6.
21. Majewski M, Habelt S, Steinbrück K. Epidemiology of athletic knee injuries: a 10-year study. *Knee.* 2006;13:184–8.
22. Kowalchuk DA, et al. Prediction of patient-reported outcome after single-bundle ACL reconstruction. *Arthroscopy.* 2009;25:457–63.
23. Hashemi J, Chandrashekar N, Slauterbeck J. The mechanical properties of the human patellar tendon are correlated to its mass density and are independent of sex. *Clin Biomech (Bristol, Avon).* 2005;20:645–52.
24. Yang XG, Li YP, Ma GS, Hu XQ, Wang JZ, Cui ZH, et al. Study on weight and height of the Chinese people and the differences between 1992 and 2002. *Zhonghua Liu Xing Bing Xue Za Zhi.* 2005;26(7):489–93.
25. Popovic S, Bjelica D, Molnar S, Jaksic D, Akpinar S. Body height and its estimation utilizing arm span measurements in Serbian adults. *Int J Morphol.* 2013;31(1):271–9.
26. Spindler K, Bergfeld J, Andriš J. Intraoperative complications of ACL surgery: avoidance and management. *Orthopedics.* 1993;16(4):425–30.
27. Verma NN, Dennis MG, Carreira DS, Bojchuk J, Hayden JK, Bach BR Jr. Preliminary clinical results of two techniques for addressing graft tunnel mismatch in endoscopic anterior cruciate ligament reconstruction. *J Knee Surg.* 2005;18(3):183–91.
28. Luk KMS, Wong NM, Cheng JCK. Anthropometry of the patellar tendon in Chinese. *J Orthop Surg (Hong Kong).* 2008;16:39–42.
29. Goldstein JL, Verma N, McNickle AG, Zelazny A, Ghodadra N, Bach BR. Avoiding mismatch in allograft anterior cruciate ligament reconstruction: correlation between patient height and patellar tendon length. *Arthroscopy.* 2010;26(5):643–50.
30. Navali AM, Jafarabadi MA. Is there any correlation between patient height and patellar tendon length? *Arch Bone J Surg.* 2015;3(2):99–103.
31. Fowler BL, DiStefano VJ. Tibial tunnel bone grafting: a new technique for dealing with graft-tunnel mismatch in endoscopic anterior cruciate ligament reconstruction. *Arthroscopy.* 1998;14:224–8.
32. Mariani PP, Calvisi V, Margheritini F. A modified bone-tendon-bone harvesting technique for avoiding tibial tunnel-graft mismatch in anterior cruciate ligament reconstruction. *Arthroscopy.* 2003;19(1):3.
33. Morgan CD, Kalman VR, Grawl DM. Isometry testing for anterior cruciate ligament reconstruction revisited. *Arthroscopy.* 1995;11:647–59.
34. Barber FA. Flipped patellar tendon autograft anterior cruciate ligament reconstruction. *Arthroscopy.* 2000;16:483–90.
35. LaPrade RF. The anatomy of the deep infrapatellar bursa of the knee. *Am J Sports Med.* 1998;26:129–32.
36. McAllister DR, Bergfeld JA, Parker RD, Grooff PN, Valdevit ADC. Cruciate ligament reconstruction a comparison of pre-operative imaging techniques for predicting patellar tendon graft length before cruciate ligament reconstruction. *Am J Sports Med.* 2001;461–5.
37. Andrikoula S, Tokis A, Vasiliadis HS, Georgoulis A. The extensor mechanism of the knee joint: an anatomical study. *Knee Surg Sports Traumatol Arthrosc.* 2006;14:214–20.
38. Yoo JH, Yi SR, Kim JH. The geometry of patella and patellar tendon measured on Knee MRI. *Surg Radiol Anat.* 2007;29:623–8.
39. Brown JA, Brophy RH, Franco J, Marquand A, Solomon TC, Watanabe D, et al. Avoiding allograft length mismatch during anterior cruciate ligament reconstruction. *Am J Sports Med.* 2007;35:986–9.
40. Tuncyurek O, Ozkol M, Ozic U, Pabuscu Y. The role of patellar tendon morphometry on anterior knee pain. *Surg Radiol Anat.* 2010;32:539–43.
41. Chang CB, Seong SC, Kim TK. Preoperative magnetic resonance assessment of patellar tendon dimensions for graft selection in anterior cruciate ligament reconstruction. *Am J Sports Med.* 2009;37(2):376–82.
42. Lairungruang W, Kuptniratsaikul S, Itiravivong P. The remained patellar tendon strength after central one third removal: a biomechanical study. *J Med Assoc Thai.* 2003;86 (12):1101–5.
43. Beard D, Anderson J, Davies S, Price A, Dodd C. Hamstring vs. patella tendon for ACL reconstruction: a randomised controlled trial. *Knee.* 2001;8:45–50.
44. Yanke AB, Bell R, Lee AS, Shewman E, Wang VM, Bach BR Jr. Characteristics compared with hemi-patellar tendon grafts central-third bone-patellar tendon-bone allografts demonstrate superior biomechanical failure. *Am J Sports Med.* 2013;41:2521–6.
45. Iriuchishima T, Yorifuji H, Aizawa S, Tajika Y, Murakami T, Fu FH. Evaluation of ACL mid-substance cross-sectional area for reconstructed autograft selection. *Knee Surg Sports Traumatol Arthrosc.* 2014;22:207–13.
46. Basso O, Johnson DP, Amis AA. The anatomy of the patellar tendon. *Knee Surg Sports Traumatol Arthrosc.* 2001;9:2–5.
47. Toumi H, Higashiyama I, Suzuki D, et al. Regional variations in human patellar trabecular architecture and the structure of the proximal patellar tendon enthesis. *J Anat.* 2006;208:47–57.
48. Kongsgaard M, Reitelsheder S, Pedersen TG, Holm L, Aagaard P, Kjaer M, et al. Region specific patellar tendon hypertrophy in humans following resistance training. *Acta Physiol.* 2007;191:111–21.
49. Wang H, Hua C, Cui H, Li Y, Qin H, Han D, et al. Measurement of normal patellar ligament and anterior cruciate ligament by MRI and data analysis. *Exp Ther Med.* 2013;5:917–21.

Rad je primljen 2. 11. 2016.

Recenziran 10. 12. 2016.

Prihvaćen za štampu 16. 12. 2016.

BIBLID.0025-8105:(2016):LXIX:Suppl 1:53-58.

Clinical Center of Vojvodina, Novi Sad
 Department of Orthopedic Surgery and Traumatology¹
 University of Novi Sad, Faculty of Medicine²

UDK 616.728.3:616.718.5]-089
 DOI: 10.2298/MPNS16S1059J

FUNCTIONAL PERFORMANCE TEST AFTER ANTERIOR CRUCIATE LIGAMENT RECONSTRUCTION WITH HYBRID TIBIAL FIXATION

FUNKCIONALNI REZULTATI NAKON REKONSTRUKCIJE PREDNJEG UKRŠTENOG LIGAMENTA TEHNIKOM HIBRIDNE FIKSACIJE

Nataša J. JANJIĆ^{1,2}, Oliver DULIĆ¹, Srđan NINKOVIĆ^{1,2}, Vladimir HARHAJI^{1,2}, Zoran GOJKOVIĆ^{1,2}
 and Miroslav MILANKOV^{1,2}

Summary

Introduction. Anterior cruciate ligament rupture is one of the most common injuries in team sports and its fixation at the tibial site is the weakest link in the femur-hamstring-tibia structure in anterior cruciate ligament reconstruction. The aim of this research was to compare the results of knee stability, knee motion and activity after anterior cruciate ligament reconstruction with single bundle hamstring tendon graft versus bone hamstring tendon bone graft placed with different techniques. **Material and Methods.** Ninety patients who underwent anterior cruciate ligament reconstruction were randomly divided into three groups; group I patients were treated with standard single bundle hamstring tendon graft and standard operative technique, group II patients had modified single bundle hamstring tendon graft with bone attachments on both ends which was fixed with standard method, while group III patients were operated with hybrid fixation technique at the tibial site and modified graft was used as neoligament. **Results.** All surgically treated patients had a statistically significant improvement postoperatively in comparison with their condition before the treatment according to the Lachman scale and International Knee Documentation Committee standard. However, the patients of group III have achieved statistically significant better postoperative results on Tegner scale and Lysholm score when compared to group I and II patients. It took the third group athletes a significantly shorter time to participate in the first competition after surgery than the athletes from the other two groups. **Conclusion.** Hybrid operative technique increased strength and stability of the graft at the tibial site which accelerated healing process and reduced knee laxity.

Key words: Anterior Cruciate Ligament Reconstruction; Tibia; Tendons; Range of Motion, Articular; Joint Instability; Treatment Outcome; Lysholm Knee Score

Introduction

Anterior cruciate ligament (ACL) injury has a low rate of prevalence among general population, but it is a common athletic injury and one of the most commonly treated conditions of the knee [1]. The aim

Sažetak

Uvod. Ruptura prednjeg ukrštenog ligamenta jedna je od najčešćih povreda u ekipnim sportovima, a fiksacija u golenjači je najslabija karika u strukturi butna kost-hamstring-kolenjača kod rekonstrukcije prednjeg ukrštenog ligamenta. Cilj ovog istraživanja bio je da se uporede rezultati stabilnosti kolena, pokretljivosti i aktivnosti kolena nakon rekonstrukcije prednjeg ukrštenog ligamenta kalemom od tetiva hamstringa (jednostruki snop) u odnosu na kalem kost-tetiva hamstringa-kost, fiksirani različitim tehnikama. **Materijal i metode.** Devedeset pacijenata kojima je urađena rekonstrukcija prednjeg ukrštenog ligamenta, metodom slučajnog izbora, raspoređeni su u tri grupe: u prvoj grupi bili su pacijenti kod kojih je primenjen standardni kalem od tetiva hamstringa-jednostruki snop i standardna operativna tehnika; u drugoj grupi bili su pacijenti sa modifikovanim kalemom od tetiva hamstringa sa koštanim ojačanjem na oba kraja, fiksiran standardnom operativnom metodom, dok je kod pacijenata iz treće grupe primenjena hibridna tehnika fiksacije na strani golenjače i modifikovani kalem je korišćen kao neoligament. **Rezultati.** Svi hirurški tretirani pacijenti su imali statistički značajno postoperativno poboljšanje u odnosu na njihovo stanje pre operacije prema Lahmanovoj skali i standardu *International Knee Documentation Committee*. Međutim, kod pacijenata iz treće grupe postignuti su statistički značajno bolji postoperativni rezultati prema Tegnerovoj skali i Lišolmovom skoru u poređenju sa rezultatima postignutim kod pacijenata iz prve i druge grupe. Vreme koje je sportistima iz treće grupe bilo potrebno da bi učestvovali na prvom takmičenju posle operacije statistički značajno je bilo kraće od vremena koje je bilo potrebno sportistima iz preostale dve grupe pre nego su mogli da se takmiče posle operacije. **Zaključak.** Hibridna operativna tehnika je povećala čvrstinu i stabilnost kalema na strani golenjače što je ubrzalo proces zarastanja i smanjilo labavost kolena.

Gljučne reči: rekonstrukcija prednjeg ukrštenog ligamenta; tibija; tetive; opseg pokreta zgloba; nestabilnost zgloba; ishod lečenja; Lisholmov skor

of ACL reconstruction is to reproduce the mechanical and biological properties of the original ligament. It should restore the knee stability, maintain the range of movement and thereby minimize injury to both the chondral surfaces and the menisci [2]. Autografts are usually used for reconstruction of ACL since they

Abbreviations

ACL	– anterior cruciate ligament
BHB	– bone-hamstring-bone
BMI	– body mass index
IKDC	– International Knee Documentation Committee
RCI	– round cannulated interference screw
SD	– standard deviation
WHO	– World Health Organization

guarantee a low risk of adverse inflammatory reaction and virtually no risk of disease transmission [3]. Bone-patellar tendon-bone and hamstring tendon graft are used as neoligaments; hamstring grafts, when compared with bone-patellar tendon-bone autografts, offer potential advantages including decreased extensor mechanism morbidity and favorable biomechanical properties [4].

However, ACL reconstruction with hamstring tendon graft has clinically significant laxity in 10–30% of knees [5, 6]. Namely, slow healing of the soft tendon tissue in the bone tunnel, followed by graft motion within the tunnel and finally tunnel enlargement which leads to knee laxity are clinically important problems after ACL reconstruction with hamstring tendon graft [7].

Graft fixation is another important factor in cruciate ligament reconstruction. The tibial fixation is the weakest point of a femur-graft-tibia construct after hamstring graft ACL reconstruction [8–10]. ACL reconstruction demands optimal fixation properties since accelerated rehabilitation after surgery is required. The requests for optimal graft fixation include stability and strength to withstand early post-operative forces until graft-to-tunnel healing has occurred, anatomical insertion at the site of the ligament, facilitated graft-tunnel healing and production of normal histological transition zone between the host bone and the neoligament [4, 11, 12]. ACL reconstruction cannot restore the exact mechanical properties of the injured ligament as they used to be before the injury, but current neoligaments as well as fixation techniques can be improved. Our previous study dealt with hybrid hamstring graft tibial fixation technique after being performed in about 200 patients without intra or postoperative complications [13]. The aim of this paper is to compare the objective results of knee stability as well as subjective grades of knee motion and activity after ACL reconstruction with single bundle hamstring tendon graft versus bone hamstring tendon bone graft placed with standard technique or hybrid fixation technique.

Material and Methods

Patients

The study was a randomized retrospective-prospective one. The research was performed at the Department of Orthopedic Surgery and Traumatology of the Clinical Center of Vojvodina with the approval of the Ethical Committee of Clinical Center of Vojvodina.

The study inclusion criteria were the ages of 18 to 45 years and ACL rupture diagnosis. Therefore, the

patients under the age of 18 and over the age of 45 years, those with injuries of other ligaments or with comorbidities which may complicate the surgical procedure were not included in the study.

The exclusion criteria were surgical complications and patients who were operated 60 months after ACL had been injured.

Out of 92 patients included in the study, 90 patients finished it. Two patients were excluded from the study since they underwent ACL reconstruction 60 months after the ACL rupture.

Grafts

Two types of grafts were prepared for ACL reconstruction:

– Single bundle hamstring tendon graft prepared from *m. semitendinosus* and *m. gracilis tendons*. The tendons with its periosteal attachments were harvested through a small incision. Single bundle technique was used and grafts whose diameter was 8 or 9 mm.

– Single bundle hamstring tendon graft prepared from *m. semitendinosus* and *m. gracilis tendons* strengthened with fresh bone autotransplant (compressed spongy bone) on the graft end. Two 2-cm long bone cylinders of 8 mm in diameter were harvested and tied on both ends of the tendon with sutures. The bone ends were pressed, so the diameter of the prepared grafts was 8 or 9 mm.

Operative technique

The tendon grafts were fixed with standard operative procedure or with hybrid graft tibial fixation.

– The standard graft tibial fixation was fixed with interference screws in the previously prepared femoral and tibial tunnel.

– The hybrid graft tibial fixation was prepared at the Department of Orthopedic Surgery and Traumatology of the Clinical Center of Vojvodina, Faculty of Medicine, Novi Sad. The grafts were placed in the previously prepared femoral and tibial tunnels. The grafts were fixed with round cannulated interference screws, RCI (Grujić & Грјујић, Novi Sad, Serbia). When the graft was fixed in the femoral tunnel, the knee was in full flexion, at 110–120° and when it was fixed in the tibial tunnel, the knee was under the angle of 15–20°. The graft was tensioned using 80 N (Karl Storz, Tuttingen, Germany). After being fixed with round cannulated interference screws, additional fixation was performed. Bi-cortical 4.5-mm-diameter custom-made screws with modified head were placed below the tibial tunnel opening. First, the screw was tightened completely and afterwards it was loosened for half a circle. Three additional knots were tied in to provide improved graft fixation and knee stability. Finally, the screw was retightened for a quarter of a circle. For more details see reference [13].

Rehabilitation

After surgery the operated knee was fixed with the elastic immobilizer for fourteen days. Shelbour-

Table 1. Age and BMI (average \pm standard deviation, SD) of patients with ACL reconstruction among groups treated with different surgical techniques and with different grafts**Tabela 1.** Starost i BMI (prosek \pm standardna devijacija, SD) pacijenata sa rekonstrukcijom ACL između grupa tretiranih različitim operativnim tehnikama i sa različitim kalemima

	Group I/Grupa I	Group II/Grupa II	Group III/Grupa III
Age, years/Uzrast, god	24.05 \pm 7.31	27.77 \pm 6.12	29.22 \pm 8.51
BMI/BMI	24.08 \pm 2.47	25.05 \pm 3.43	23.49 \pm 2.90

BMI - indeks telesne mase

ne rehabilitation protocol was applied modified [14]. From day one after surgery the patients were subjected to continuous passive mobilization of the operated knee with Kinetic Performa. Two weeks after the ACL reconstruction they were able to reach 90° flexion and partial weight bearing (as tolerated), while the complete weight bearing was allowed six weeks later. The rehabilitation program consisted of series of exercises designed to restore the muscle strength.

Groups

The patients were randomly divided into three groups:

Group I – Single bundle hamstring tendon graft prepared from *m. semitendinosus* and *m. gracilis tendons*, fixed with standard operative procedure (30 patients);

Group II – Single bundle hamstring tendon graft prepared from *m. semitendinosus* and *m. gracilis tendons* with bone autotransplant on the graft end (bone-hamstring-bone, BHB), fixed with standard operative procedure (30 patients);

Group III – Single bundle hamstring tendon graft prepared from *m. semitendinosus* and *m. gracilis tendons* with bone autotransplant on the graft end (BHB) fixed with hybrid tibial fixation procedure (30 patients).

Evaluation and Rating Scales

The following tests were used for objective determination of the knee function before and after ACL reconstruction:

– Lachman test – a reliable and sensitive test to diagnose ACL injury and knee laxity as mild: 0 to 5 mm, moderate: 6 to 10 mm laxity and severe: 11 to 15 mm. Following ACL reconstruction, laxity should be less than 3 mm compared to healthy knee results [15].

– Tegner activity grading scale (from 0 to 10) - a system for evaluating the degree of impairment, disability, and handicap of the patient with an ACL injury including functional score, activity grading, stability testing, and measurements of performance and strength, where 0 indicates retirement, while 10 allows professional sport activities [16].

– Lysholm scoring scale (to max 100) for knee ligament surgery follow-up emphasizes evaluation of symptoms of instability [17, 18]. The score is considered to be poor if it is below 66, fair if ranging from 66 to 81, good for values between 82 and 92 and excellent if it is above 93.

– International Knee Documentation Committee (IKDC) objective grade. A grade (A for normal, B for nearly normal, C for abnormal, and D for severely abnormal) was given on the basis of the findings of the individual physical examination pertinent to knee instability [19].

Statistical Analysis

The differences between the groups were compared with unpaired t-test. A P value below 0.05 was considered statistically significant.

Results

Demographic

Ninety-two patients were enrolled in the study and two patients were excluded since the interval between the ACL injury and ACL reconstruction was over 60 months. Out of 90 patients who finished the study, 71% were men and 29% were women. The patients were between the ages of 18 and 45 years, the average age being 27.16 \pm 7.46 years. **Table 1** gives the average age and the average body mass index (BMI) of the patients who underwent ACL reconstruction.

There was a statistically significant difference in age among the patients treated with standard operative technique and standard graft (group I) and those with hamstring graft tendon and standard operative technique (group II), as well as between group I patients and those with bone-hamstring tendon-bone graft and hybrid operative method (group III patients) presented as $t=1.9695$ and $p=0.0545$ and $t=2.1544$ and $p=0.0372$, respectively. No statistically significant difference was recorded between the ages of the patients who underwent ACL reconstruction with hamstring graft tendon, regardless of the operative technique i.e. between group II and group III patients ($t=0.7216$, $p=0.4738$).

Most of the patients had normal BMI. None of the women was obese and only 11% of men were obese according to the WHO classification. The patients' weight was in range from 47 to 105 kg, while the height ranged from 157 to 200 cm. Body mass index of the patients did not differ significantly among the groups.

Out of 79 treated patients who went in for sports, 65% played it professionally and 35% for recreation. The cause for ACL rupture was landing in 35%, direction change in 30% and direct hit with other player in 25% of the cases. Hyperextension and deceleration were responsible for ACL rupture in only

Table 2. The results of the Lachman test before and after surgery
Tabela 2. Rezultati Lahmanovog testa pre i posle operacije

		Healthy knee laxity [mm]/ Labavost zdravog kolena [mm]		Injured knee laxity/Labavost po- vređenog kolena [mm]	
		Interval Interval	Average ± SD/ Sred. vred. ± SD	Interval/ Interval	Average ± SD/ Sred. vred. ± SD
Group I Grupa I	Before surgery/Pre operacije	1.0-4.5	2.1 ± 1.1	11.4-23.5	14.6 ± 3.6
	After surgery/Posle operacije	1.0-4.5	1.9 ± 1.1	2.0-7.0	4.2 ± 1.2
Group II Grupa II	Before surgery/Pre operacije	1.0-8.0	3.2 ± 1.5	12.1-29.7	19.0 ± 3.5
	After surgery/Posle operacije	1.0-8.3	3.3 ± 1.4	1.0-6.0	3.8 ± 1.2
Group III Grupa III	Before surgery/Pre operacije	1.0-5.0	2.9 ± 1.5	11.2-22.5	16.9 ± 3.1
	After surgery/Posle operacije	1.0-6.0	2.8 ± 1.0	1.0-10.5	3.0 ± 2.2

10% of the examined cases. Out of the study sample, 49% of the operated patients got injured while playing football, 23% handball, 15% basketball, 6% volleyball and 7% all other sports.

The patients underwent surgical treatment up to 60 months after the ACL injury. Surgery was performed in 81% of the patients within 12 months after the injury and in 52% within 4 months after the rupture was diagnosed. The first and the second injury was treated surgically in 38% and 27% of the patients, respectively and the remaining patients underwent operation after three or more injuries of the ligament.

Lachman test results

There was no significant difference in Lachman test before and after surgery for the healthy knee in any study group, nor was there a difference between the healthy knee and injured knee results after ACL reconstruction. However, in each operated group there were statistically significant differences between the pre and postoperative results of the injured knee as following: $t=12.37$, $p<0.001$ for group I, $t=22.45$, $p<0.001$ for group II and $t=16.65$, $p<0.001$ for group III, neither were differences of statistical significance recorded among the groups after surgery for the operated knee when Lachman test results were compared although different grafts were placed and different operative techniques were applied. The statistical results are presented below:

– Differences between group I and II $t=-1.0881$, $p=0.2819$

– Differences between group II and III $t=-0.3148$, $p=0.7541$

– Differences between group I and III $t=-0.9338$, $p=0.355$

The details of the Lachman test are presented in **Table 2.**

Tegner activity scale results

According to Tegner activity scale there was a statistically significant difference ($t=23.90$, $p<0.001$) before (1.94 ± 0.89) and after the surgery (7.70 ± 1.69) in the patients of the observed sample. Most of the athletes (89%) returned to trainings and competition and moreover, 22% of players achieved level 10 of the Tegner activity scale while 20% and 18% of them achieved level 9 and 8, respectively. **Table 3** presents Tegner activity scale results of patients in different groups depending on the graft and fixation method type.

There were no statistically significant differences in the postoperative results between the group I and group II patients ($t=0.6196$, $p=0.3582$) according to the Tegner scale. However, the patients from group III who had been operated with hybrid fixation technique and bone-hamstring tendon-bone graft achieved better results on the Tegner activity scale when compared to the group I patients who had had standard tendon graft fixed with standard technique ($t=3.6753$, $p<0.001$) and in comparison with the group II patients who had had the same bone-hamstring tendon-bone graft placed but with standard operative procedure ($t=3.609$, $p<0.001$).

The Lysholm grading scale results

The Lysholm scale results suggested a statistically significant postoperative improvement of knee stability

Table 3. The results of Tegner activity scale of patients in differently treated groups
Tabela 3. Rezultati Tegnerove skale aktivnosti pacijenata različitih operativnih grupa

		Interval/Interval	Average ± SD/Sred. vr ± SD
Group I/Grupa I	Before surgery/Pre operacije	1-2	1.62 ± 0.49
	After surgery/Posle operacije	3-10	7.13 ± 1.90
Group II/Grupa II	Before surgery/Pre operacije	1-6	2.03 ± 0.51
	After surgery/Posle operacije	4-10	7.43 ± 1.53
Group III/Grupa III	Before surgery/Pre operacije	1-4	2.13 ± 0.74
	After surgery/Posle operacije	7-10	8.8 ± 0.87

Table 4. The results of the Lyshom scale before and after surgery in different groups**Tabela 4.** Rezultati pacijenata različitih grupa dobijenih na osnovu Lišolmove skale pre i posle operacije

		Interval/Interval	Average \pm SD/Sred. vr \pm SD
Group I/Grupa I	Before surgery/Pre operacije	32-95	42.33 \pm 6.34
	After surgery/Posle operacije	95-98	96.66 \pm 1.27
Group II/Grupa II	Before surgery/Pre operacije	27-89	59 \pm 3.96
	After surgery/Posle operacije	72-100	96.33 \pm 4.27
Group III/ Grupa III	Before surgery/Pre operacije	27-96	58.12 \pm 4.38
	After surgery/Posle operacije	90-100	97.92 \pm 2.54

Table 5. Grades according to IKDC scale before and after ACL reconstruction**Tabela 5.** Ocene prema IKDC skali pre i posle rekonstrukcije prednje ukrštene veze

		Grade A/Ocena A		Grade B/Ocena B		Grade C/Ocena C		Grade D/Ocena D	
		n	%	n	%	n	%	n	%
Group I/Grupa I	Before surgery					14	46.6	16	53.4
	After surgery								
Group II/Grupa II	Before surgery					22	73.3	8	26.7
	After surgery								
Group III/Grupa III	Before surgery					24	80	6	20
	After surgery								
Posle operacije		21	70.0	7	23.4	2	6.6		
Posle operacije		22	73.3	5	16.6	3	10		
Posle operacije		26	86.6	3	10	1	3.3		

when compared with preoperative results ($t=21.86$, $p<0.001$). According to the Lysholm scale, the results were excellent in 39.50%, good in 20.25%, fair in 12.15% and poor 8.10% of the patients after ACL reconstruction. **Table 4** shows the Lysholm scale results achieved by patients who had undergone different surgeries.

No statistical significance was recorded in the postoperative results of the Lysholm scale between the group I and group II patients, nor between the group II and group III patients, $t=-0.2447$, $p=0.8077$ and $t=1.1595$, $p=0.2517$ respectively. Introducing different operative techniques and different graft type simultaneously resulted in a statistically significant increment in the knee stability in the group III patients according to the Lysholm scale in comparison with the postoperative knee stability in the group I patients, $t=2.0259$, $p=0.492$.

IKDC scale grades

Table 5 summarizes the IKDC scale grades before and after ACL reconstruction in each observed group.

Recovery time of athletes after ACL reconstruction

There was no statistically significant difference in time it took athletes to resume training after ACL reconstruction between groups; however, it took 79 operated athletes from the group III patients significantly shorter time to participate in the first game when compared with the group II ($t=-2.3692$, $p=0.0225$) and group I patients ($t=2.9798$, $p=0.044$).

Discussion

ACL injuries are common in team sports. Football (soccer) is the most popular sport worldwide with more than 270 million active players (www.fifa.com) and based on data from a sampling of college men's football teams, there were an estimated 69 ACL injuries nationwide in a single season [20] or incidence rates of ACL injury ranged from 0.15% to 3.67% in soccer players of various age and competition levels per year [21]. These findings correspond with 49% injuries in football players compared to all other athletes in our sample.

Graft fixation, function, and integration ultimately determine the outcome of ACL reconstruction [22, 23]. The knee stability improved after ACL reconstruction in the 90 observed patients regardless of the graft type and surgical technique performed. The comparison of the pre and postoperative results of the Lachman test confirmed the postoperative improvement of knee laxity. There were no differences in the knee laxity after surgery between groups. When the operated knee has been compared with the healthy knee the results are considered excellent if the arthrometric measurement of knee laxity is between 0 and 3 mm and good if it is up to 5 mm [24]. The obtained results in this study can be considered good/excellent. Freedman and al. [25] have analyzed 34 studies of ACL reconstruction, 21 with patellar tendon graft and 13 with hamstring tendon graft in over 1,300 patients. The literature data are in accordance with our study since 73.8% of the obta-

ined results after hamstring tendon graft placement according to the Lachman test were excellent (<3 mm) and 19.4% were classified as good (3-5 mm), while 79% were excellent and 15.4% were good when patellar tendon graft was used for reconstruction. In the review study of Lewis and al. [26], in which 1024 single-bundle anterior cruciate ligament reconstructions were analyzed from 11 studies, it was found that the results were good/excellent (<5 mm) according to Lachman test in 86%. Hence, when the Lachman test results after ACL reconstruction in this study are adequately interpreted, they are comparable to literature data.

Furthermore, the results of the Tegner activity scale and Lysholm scoring scale define more precisely the postoperative quality of life of the patients with ACL reconstruction. Both Tegner scale and Lysholm scale confirm a significant improvement of the possibility for everyday and professional sport activity in our patients after surgery as expected [27–29]. The average values for Tegner scale were improved from 1.94 after the injury to 7.70 after ACL reconstruction. Moreover, the Lysholm scale confirmed these findings, so the preoperative values ranged from 27 to 89, the average value being 54.03, and they were improved to as much as 72 to 100, the average postoperative value being 96.9. However, more careful observation of the results of both Tegner and Lysholm scale suggest that postoperative activity of the patients is affected by the operative method and the graft type applied. The statistically significant difference in the postoperative Tegner activity scale results of the group III compared with the postoperative results of the group II and group I indicates the more pronounced knee stability in the group III patients and greater possibility for unimpeded and painless physical activity after surgery. The postoperative results obtained with the Lysholm grading scale confirm the statistically significant differences in knee stability and its influence on the patients' quality of life after surgery between the group I and group III patients. However, no statistically significant differences were recorded in the postoperative results of the Lysholm scale between the group II and group III patients. The postoperative results of the Tegner activity scale and of the Lysholm grading scale presented in this paper for the group I and II patients correspond to the results reported in the literature, no matter whether hamstring tendon graft with single bundle or double bundle technique was performed [30], quadrupled hamstring graft was placed [31] or quadruple-stranded semitendinosus tendon was used [32] for ACL reconstruction or whether interference screw or a press-fit fixation

was applied [33]. When Tegner and Lysholm scales were applied, the results obtained after operative treatment in the group III patients (hamstring graft tendon with bone attachment fixed with hybrid surgical technique) are even more favorable compared to the literature data [30–33].

Most of the players (89%) who were followed up after surgery have returned to their professional sport activities. There was a difference in time, although not statistically significant, it took the athletes from group I and group III to resume training and it depended on the operative technique and graft type (it took the group III athletes the least time from surgery to their first training). It took the operated athletes from group III statistically significantly less time to enter the first sport competition when compared with the group II and group I patients, which further corroborates these statements. Normally, there are no sites in the human body where tendon enters the bone tunnel, while in the fixation process the tendinous portion of the hamstring graft usually extends into the upper part of the tibial tunnel [34]. The bone attached to both sides of the tendon graft (in group II) reduces the healing time when compared to group I in which standard single bundle hamstring graft was placed, while hybrid fixation which was performed in group III reduced slippage of the soft tissue and additionally decreased the time required for recovery.

The IKDC scale reported in this paper showed grade A/B (normal/nearly normal) after the surgery in 93.4% patients from group I, 89.9% from group II and 96.6% from group III compared to 0% before the ACL reconstruction. Normal/nearly normal (A/B) grade usually ranges between 78 and 92% after surgical treatment of ACL rupture [30, 35–38], hence the obtained results in this study can be considered quite satisfactory.

Conclusion

The surgical treatment of anterior cruciate ligament rupture improves subjective experience of knee motility and objective stability of the treated knee. Placing bone-hamstring tendon-bone graft allows a biological approach since no artificial fixation devices, i.e. implants, are utilized and it diminishes the risk of postoperative bone tunnel enlargement because tibial tunnel diameter is filled with the tibial bone cylinder and hence reduced. Finally, additional fixation guarantees the knee stability, increases the graft fixation strength and secures the improvement of life quality which includes not only everyday activity but professional sport trainings and competition.

References

1. Lyman S, Koulouvaris P, Sherman S, Do H, Mandl LA, Marx RG. Epidemiology of anterior cruciate ligament reconstruction: trends, readmissions, and subsequent knee surgery. *J Bone Joint Surg Am.* 2009;91(10):2321-8.
2. Deehan DJ, Cawston TE. The biology of integration of the anterior cruciate ligament. *J Bone Joint Surg Br.* 2005;87(7):889-95.
3. Fu FH, Bennett CH, Lattermann C, Ma CB. Current trends in anterior cruciate ligament reconstruction. Part I: Biology and biomechanics of reconstruction. *Am J Sports Med.* 1999;27(6):821-30.
4. Marx RG, Spock CR. Complications following hamstring anterior cruciate ligament reconstruction with femoral cross-pin fixation. *Arthroscopy.* 2005;21(6):762.
5. Lopez MJ, Borne A, Monroe WT, Bommala P, Kelly L, Zhang N. Novel anterior cruciate ligament graft fixation device reduces slippage. *Med Devices (Auckl).* 2013;6:59-68.
6. Grover D, Thompson D, Hull ML, Howell SM. Empirical relationship between lengthening an anterior cruciate ligament graft and increases in knee anterior laxity: a human cadaveric study. *J Biomech Eng.* 2006;128(6):969-72.
7. Brand J, Weiler A, Caborn D, Brown C, Johnson D. Current concepts: graft fixation in cruciate ligament surgery. *Am J Sports Med.* 2000;28(5):761-74.
8. Kousa P, Järvinen TL, Vihavainen M, Kannus P, Järvinen M. The fixation strength of six hamstring tendon graft fixation devices in anterior cruciate ligament reconstruction. Part I: femoral site. *Am J Sports Med.* 2003;31(2):174-81.
9. Roos PJ, Hull ML, Howell SM. Lengthening of double-looped tendon graft constructs in three regions after cyclic loading: a study using Roentgen stereophotogrammetric analysis. *J Orthop Res.* 2004;22(4):839-46.
10. Khan R, Konyves A, Rama KR, Thomas R, Amis AA. RSA can measure ACL graft stretching and migration: development of a new method. *Clin Orthop Relat Res.* 2006;448:139-45.
11. Harvey A, Thomas NP, Amis AA. Fixation of the graft in reconstruction of the anterior cruciate ligament. *J Bone Joint Surg Br.* 2005;87(5):593-603.
12. Kousa P, Järvinen TL, Vihavainen M, Kannus P, Järvinen M. The fixation strength of six hamstring tendon graft fixation devices in anterior cruciate ligament reconstruction. Part II: tibial site. *Am J Sports Med.* 2003;31(2):182-8.
13. Milankov MZ, Miljkovic N, Janjic N. Hybrid hamstring graft tibial fixation in anterior cruciate ligament reconstruction. *Arch Orthop Trauma Surg.* 2010;130:1033-6.
14. Shelburne KD, Gray T. Minimum 10-year results after anterior cruciate ligament reconstruction: how the loss of normal knee motion compounds other factors related to the development of osteoarthritis after surgery. *Am J Sports Med.* 2009;37(3):471-80.
15. van Eck CF, van den Bekerom MP, Fu FH, Poolman RW, Kerkhoffs GM. Methods to diagnose acute anterior cruciate ligament rupture: a meta-analysis of physical examinations with and without anaesthesia. *Knee Surg Sports Traumatol Arthrosc.* 2013;21(8):1895-903.
16. Tegner Y, Lysholm J, Odensten M, Gillquist J. Evaluation of cruciate ligament injuries. A review. *Acta Orthop Scand.* 1988;59(3):336-41.
17. Lysholm J, Gillquist J. Evaluation of knee ligament surgery results with special emphasis on use of a scoring scale. *Am J Sports Med.* 1982;10(3):150-4.
18. Kong DH, Yang SJ, Ha JK, Jang SH, Seo JG, Kim JG. Validation of functional performance tests after anterior cruciate ligament reconstruction. *Knee Surg Relat Res.* 2012;24(1):40-5.
19. Collins NJ, Misra D, Felson DT, Crossley KM, Roos EM. Measures of knee function: International Knee Documentation Committee (IKDC) Subjective Knee Evaluation Form, Knee Injury and Osteoarthritis Outcome Score (KOOS), Knee Injury and Osteoarthritis Outcome Score Physical Function Short Form (KOOS-PS), Knee Outcome Survey Activities of Daily Living Scale (KOS-ADL), Lysholm Knee Scoring Scale, Oxford Knee Score (OKS), Western Ontario and McMaster Universities Osteoarthritis Index (WOMAC), Activity Rating Scale (ARS), and Tegner Activity Score (TAS). *Arthritis Care Res (Hoboken).* 2011;63(11):S208-28.
20. Mihata LC, Beutler AI, Boden BP. Comparing the incidence of anterior cruciate ligament injury in collegiate lacrosse, soccer, and basketball players: implications for anterior cruciate ligament mechanism and prevention. *Am J Sports Med.* 2006;34(6):899-904.
21. Dai B, Mao D, Garrett W, Yu B. Anterior cruciate ligament injuries in soccer: loading mechanisms, risk factors, and prevention programs. *J Sport Health Sci.* 2014; 3(4):299-306.
22. Lopez MJ, Spencer N, Casey JP, Monroe WT. Biomechanical characteristics of an implant used to secure semitendinosus-gracilis tendon grafts in a canine model of extra-articular anterior cruciate ligament reconstruction. *Vet Surg.* 2007;36(6):599-604.
23. Monaco E, Labianca L, Speranza A, Agrò AM, Camilleri G, D'Arrigo C, et al. Biomechanical evaluation of different anterior cruciate ligament fixation techniques for hamstring graft. *J Orthop Sci.* 2010;15(1):125-31.
24. Jagodzinski M, Geiges B, von Falck C, Knobloch K, Haasper C, Brand J, et al. Biodegradable screw versus a press-fit bone plug fixation for hamstring anterior cruciate ligament reconstruction: a prospective randomized study. *Am J Sports Med.* 2010;38(3):501-8.
25. Freedman KB, D'Amato MJ, Nedeff DD, Kaz A, Bach BR Jr. Arthroscopic anterior cruciate ligament reconstruction: a metaanalysis comparing patellar tendon and hamstring tendon autografts. *Am J Sports Med.* 2003;31(1):2-11.
26. Lewis PB, Parameswaran AD, Rue JP, Bach BR Jr. Systematic review of single-bundle anterior cruciate ligament reconstruction outcomes: a baseline assessment for consideration of double-bundle techniques. *Am J Sports Med.* 2008;36(10):2028-36.
27. Briggs KK, Steadman JR, Hay CJ, Hines SL. Lysholm score and Tegner activity level in individuals with normal knees. *Am J Sports Med.* 2009;37(5):898-901.
28. Herrington L, Wrapson C, Matthews M, Matthews H. Anterior cruciate ligament reconstruction, hamstring versus bone-patella tendon-bone grafts: a systematic literature review of outcome from surgery. *Knee.* 2005;12(1):41-50.
29. Briggs KK, Lysholm J, Tegner Y, Rodkey WG, Kocher MS, Steadman JR. The reliability, validity, and responsiveness of the Lysholm score and Tegner activity scale for anterior cru-

ciate ligament injuries of the knee: 25 years later. *Am J Sports Med.* 2009;37:890-7.

30. Streich NA, Friedrich K, Gotterbarm T, Schmitt H. Reconstruction of the ACL with a semitendinosus tendon graft: a prospective randomized single blinded comparison of double-bundle versus single-bundle technique in male athletes. *Knee Surg Sports Traumatol Arthrosc.* 2008;16(3):232-8.

31. Hamer A, Roy S, Metcalfe A. 4-strand hamstring reconstruction using bio-intrafix and rigidfix: a retrospective review. *J Bone Joint Surg Br.* 2012;94:117.

32. Zhao J, Peng X, He Y, Wang J. Two-bundle anterior cruciate ligament reconstruction with eight-stranded hamstring tendons: four-tunnel technique. *Knee.* 2006;13(1):36-41.

33. Jagodzinski M, Geiges B, von Falck C, Knobloch K, Haasper C, Brand J, et al. Biodegradable screw versus a press-fit bone plug fixation for hamstring anterior cruciate ligament reconstruction: a prospective randomized study. *Am J Sports Med.* 2010;38(3):501-8.

34. Shelbourne KD, Davis TJ. Evaluation of knee stability before and after participation in a functional sports agility pro-

gramme during rehabilitation after anterior cruciate ligament reconstruction. *Am J Sports Med.* 1999;27:156-61.

35. Moisala AS, Järvelä T, Honkonen S, Paakkala A, Kannus P, Järvinen M. Arthroscopic anterior cruciate ligament reconstruction using a hamstring graft with interference screw fixation. *Scand J Surg.* 2007;96(1):83-7.

36. Pinczewski LA, Lyman J, Salmon LJ, Russell VJ, Roe J, Linklater J. A 10-year comparison of anterior cruciate ligament reconstructions with hamstring tendon and patellar tendon autograft: a controlled, prospective trial. *Am J Sports Med.* 2007;35(4):564-74.

37. Pinczewski LA, Deehan DJ, Salmon LKJ, Russel VJ, Clingeleffer A. A five-year comparison of patellar tendon versus four-strand hamstring tendon autograft for arthroscopic reconstruction of the anterior cruciate ligament. *Am J Sports Med.* 2002;30:523-36.

38. Beynon BD, Johnson RJ, Fleming BC, Kannus P, Kaplan M, Samani J, et al. Anterior cruciate ligament replacement: comparison of bone-patellar tendon-bone grafts with two-strand hamstring grafts. A prospective, randomized study. *J Bone Joint Surg Am.* 2002;84-A(9):1503-13.

Rad je primljen 2. 11. 2016.

Recenziran 10. 12. 2016.

Prihvaćen za štampu 16. 12. 2016.

BIBLID.0025-8105:(2016):LXIX:Suppl 1:59-66.

Clinical Center of Vojvodina, Novi Sad
 Department of Orthopedic Surgery and Traumatology¹
 University of Novi Sad, Faculty of Medicine²
 Clinical Center of Vojvodina, Novi Sad, Department of Plastic and Reconstructive Surgery³

UDK 616.728.3-089.163/168
 DOI: 10.2298/MPNS16S1067R

CORRELATION BETWEEN GRAFT CONTAMINATION INCIDENCE AND LENGTH OF SURGERY PERFORMED TO RECONSTRUCT ANTERIOR CRUCIATE LIGAMENT

UTICAJ DUŽINE TRAJANJA OPERATIVNOG ZAHVATA NA INCIDENCIJU KONTAMINACIJE KALEMA TOKOM REKONSTRUKCIJE PREDNJEG UKRŠTENOG LIGAMENTA KOLENA

Predrag RAŠOVIĆ^{1,2}, Vladimir HARHAJI^{1,2}, Srđan NINKOVIĆ^{1,2}, Ivica LALIĆ^{1,2},
 Marija MARINKOVIĆ^{1,3} and Miroslav MILANKOV^{1,2}

Summary

Introduction. Anterior cruciate ligament reconstruction is one of the most performed procedures in orthopedic surgery. Due to the increasing number of population and their better access to health care, as well as the ever faster pace of modern living, this procedure is likely to become the most performed surgical procedure in orthopedics generally. One of the most common complications after this procedure is septic arthritis of the knee. The concept of intraoperative contamination of the graft during the procedure as one of the possible causes of the development of postoperative infection was mentioned as late as at the end of last and the beginning of this century and it has become the subject of much controversy among orthopedic surgeons. **Material and Methods.** This study was conducted at the Department of Orthopedic Surgery and Traumatology, Clinical Center of Vojvodina in Novi Sad and included 200 patients who had undergone primary anterior cruciate ligament reconstruction. Graft swabs were taken during the reconstruction intraoperatively, immediately before its implantation. The follow-up period was 24 months. **Results.** Of the 200 samples taken intraoperatively, 33 swabs were positive. The most common cause of intraoperative contamination was *coagulase-negative Staphylococcus* (in 72.7%). Average duration of surgery was 55.15 minutes, being 66.82 minutes in the group of patients with isolated positive swabs and 52.84 minutes in the group with negative swabs. **Conclusion.** The results of the study clearly show that prolonged duration of surgery significantly influences the incidence of graft intraoperative contamination.

Key words: Anterior Cruciate Ligament Reconstruction; Reoperation; Intraoperative Complications; Equipment Contamination; Orthopedic Procedures; Arthritis, Infectious; Risk Factors.

Introduction

The reconstruction of anterior cruciate ligament (ACL) is a very popular surgery in the world. This procedure is performed more than 200,000 times per year in the United States of America only, while in Vojvodina we perform around 300 reconstructions annually [1].

Sažetak

Uvod. Rekonstrukcija prednjeg ukrštenog ligamenta kolena predstavlja jednu od najizvođenijih procedura u ortopedskoj hirurgiji. Porastom broja populacije i dostupnosti zdravstvene zaštite, kao i ubrzanim načinom savremenog života, smatra se da će sredinom ovog veka ova procedura biti najizvođenija operativna procedura u ortopediji. Jedna od najčešćih i ujedno najnepoželjnih komplikacija nakon ove procedure je septični artritis kolena. Pojam intraoperativne kontaminacije kalema tokom ove procedure, kao jedan od mogućih uzročnika razvika postoperativne infekcije, pominje se tek krajem prošlog i početkom ovog veka i predmet je mnogih kontroverzi među ortopedskim hirurzima. **Materijal i metode.** Ova studija je sprovedena na Klinici za ortopedsku hirurgiju i traumatologiju KCV u Novom Sadu i obuhvatala je 200 ispitanika koji su podvrgnuti primarnoj rekonstrukciji prednjeg ukrštenog ligamenta kolena, a kojima je intraoperativno, neposredno pre implantacije, uziman bris kalema. Period praćenja iznosio je 24 meseca. **Rezultati.** Od 200 intraoperativno uzetih briseva, 33 brisa su bili pozitivni. Najčešći uzročnik intraoperativne kontaminacije je koagulaza-negativni *Staphylococcus* (72,7%). Prosečno vreme trajanja operativne procedure je iznosilo 55,15 minuta. U grupi pacijenata kod kojih je izolovan pozitivan bris, prosečno vreme trajanja operacije iznosilo je 66,82 minuta, a kod grupe sa negativnim brisom 52,84 minuta. **Zaključak.** Rezultati studije nedvosmisleno pokazuju da produženo trajanje operacije bitno utiče na incidenciju intraoperativne kontaminacije kalema.

Cljučne reči: rekonstrukcija prednjeg ukrštenog ligamenta; revizija; intraoperativne komplikacije; kontaminacija opreme; ortopedske procedure; septični artritis; faktori rizika

Today it is known that this procedure is safe with a high success rate (70–95%) [2]. The increase in the number of anterior cruciate ligament reconstruction causes the proportional increases in the number of revision surgery caused by complications which are incurred during and after primary ACL reconstruction. The necessity for ACL revision arises from inadequate preoperative preparation of patients, surgical

Table 1. Graft contamination incidence in relation to the type of ACL reconstruction
Tabela 1. Incidencija kontaminacije kalema u zavisnosti od tipa rekonstrukcije

Graft type Tip kalema		Graft culture/Bris kalema					
		Negative/Negativan		Positive/Pozitivan		Total/Ukupno	
		N	%	N	%	N	%
BTB/kost-tetiva-kost Hamstring/grupa mišića Total/Ukupno	BTB/kost-tetiva-kost	142	85,0%	27	81,8%	169	84,5%
	Hamstring/grupa mišića	25	15,0%	6	18,2%	31	15,5%
	Total/Ukupno	167	100,0%	33	100,0%	200	100,0%

technique mistakes which include graft incorporation mistakes and infections, and postoperative complication [3, 4].

Intraoperative graft contamination during the reconstruction of the anterior cruciate ligament is a phenomenon which every surgeon can encounter during the surgical procedure. This phenomenon is not so common, but it is a potential threat to the outcome of surgical treatment which makes surgeons doubtful regarding its further treatment [5–7]. The sharp increase in interest in the appearance of intraoperative graft contamination occurred at the turn of this century when a graft accidentally fell on the operating room floor during the surgical procedure after it had been harvested [8]. As many as 25% of the surgeons who have performed ACL reconstruction admit that they have had this type of accident in their practice and 75% of them chose graft decontamination as a treatment during ACL reconstruction, 18% chose graft harvesting and contralateral graft preparation, which can often result in a functional disability of the patient, whereas only 7% of the surgeons used allograft in that situation [9]. This intraoperative accident is a demanding and challenging issue, which is primarily related to the occurrence of postoperative infection, and the possibility of intraoperative graft contamination treatment within its prevention [10].

It has been shown that intraoperative contamination can be caused by pathogens from the nose or on the skin of the patient breaking through the barrier of aseptic surgical field as well as by airborne pathogens in the operating room, by the people present during surgery and their movement. It can also be induced by surgical smoke created during electrocautery and laser ablation of tissue by means of ultra-

sonic knives as well [11, 12]. The risk for intraoperative contamination is increased by inadequate manipulation during the preparation of the operative field, especially if surgical instruments at this point are unpacked and prepared on the operating table [13, 14]. This is a sufficient indicator for the necessity of intraoperative treatment of contamination.

The aim of this study was to determine the possible existence of intraoperative graft contamination and to correlate it with the duration of surgery, as one of the possible factors of influence on its incidence. The hypothesis was that the extension of the duration of the surgical procedure increases the incidence of contamination.

Material and Methods

This research was conducted as a prospective-retrospective study at the Department of Orthopedic Surgery and Traumatology, Clinical Center of Vojvodina in Novi Sad during the period of two years (from January 1st 2014 to December 31st 2015). The study sample consisted of 200 male and female patients, between the ages of 18 and 45, who had unilateral complete rupture of the anterior cruciate ligament of the left right knee. The diagnosis was confirmed by clinical examination and/or nuclear magnetic resonance (NMR). The reconstruction of the anterior cruciate ligament was done with either of two types of grafts: bone-tendon-bone (BTB) or hamstring graft. The surgery was performed in operating room with a protocol of cleaning before each procedure, which was validated by the local committee of hygiene. The skin preparation was performed using 4% povidone-iodine solution. Regardless of the type of the ACL reconstruction, the same proto-

Table 2. Duration of surgery in the two different groups
Tabela 2. Dužina trajanja operacije po grupama

Culture Bris	N	Duration average in minutes Trajanje operacije u minutima	SD	95% CI		Minimum Minimum	Maximum Maksimum
				Lower limit Donja granica	Upper limit Gornja granica		
Negative Negativan	167	52.84	12.253	50.97	54.72	20	150
Positive Pozitivan	33	66.82	17.085	60.76	72.88	45	120
Total Ukupno	200	55.15	14.115	53.18	57.12	20	150

col for antibiotic prophylaxis was used, i.e. second-generation cephalosporins. Every single graft after the harvesting was adequately designed, and then left on the operating table until the moment of its implantation. Immediately prior to its implantation, the swab of every graft was taken, and then cultured on blood agar. After 24 hours of incubation, the results were read. Furthermore, the duration of surgery was measured from the moment of skin incision to the moment of setting up the last skin suture.

Results

One of the two operating techniques was used for primary unilateral reconstruction of the anterior cruciate ligament of the knee in all patients (200) included in this research.

BTB graft was used for the reconstruction of the torn anterior cruciate ligament in 169 (84.5%) out of 200 patients, while only 31 (15.5%) patients underwent reconstruction of ACL with the hamstring tendon graft. During the surgical procedures, the swab of every graft was taken. In 33 cases the cultures were positive, and the incidence of graft contamination was 16.5%. Out of 33 patients with positive findings, 27 had ACL reconstruction done with BTB graft, while the rest 6 reconstructions were done with a hamstring tendon graft. Proportionally, graft contamination was approximately equally distributed in these groups: BTB 27/169 and hamstrings 6/31.

The most common cause of contamination in positive swabs was *coagulase-negative Staphylococcus*, isolated in 24 (72.7%) patients, whereas *Staphylococcus aureus* was isolated in swabs of 6 patients (18.2%). *Acinetobacter* was found in 2 swabs (6.1%) and one patient was found to have *Staphylococcus viridians* (3%).

In the group of patients who underwent BTB technique, average time from the moment of graft harvesting to the moment of its implementation was 17.26 minutes. Graft exposure time in the patients who underwent ACL reconstruction with hamstring tendons was 19.21 minutes. The average graft exposure time, regardless of the surgical technique used, was 18.91 minutes. In patients with BTB graft, graft exposure time was significantly shorter than in those patients with hamstring surgery. This result was

expected since longer time is required for preparing hamstring graft compared to BTB graft.

The average duration of surgery in our sample (n=200) amounted to 55.15 minutes. However, the operating time in the group of patients with positive swabs was 66.82 minutes, but only 52.84 minutes in the group of patients with negative swabs. When we compared the operating times between these two groups, we found a statistically significant difference ($p < 0.5$), meaning that duration of surgery was significantly longer in the group of patients with positive swabs.

The prolonged duration of the surgery in most cases related to the execution of ligamentoplasty combined with meniscectomy of one meniscus, or the existence of associated injuries of the anterior cruciate ligament and one of the menisci. An associated meniscal injury was present in half of the patients. In the group of patients with positive cultures, 23 (71.9%) required ligamentoplasty associated with one of the meniscectomy. In contrast, in the group with negative cultures, ACL reconstruction associated with meniscectomy was performed in 46.1% of cases, while in the remaining 53.9% only ligamentoplasty was required.

Discussion

There is no clear consensus about graft contamination incidence. According to data found in literature, it ranges between 10 and 50%. In our study, graft contamination was registered in 15.5% of patients, which is similar to the results reported by Hantes et al. [6]. They found that the average incidence of intraoperative graft contamination was 12%. Furthermore, they showed that contamination was greater in the grafts obtained from the hamstring tendons because of the longer time required for graft preparation. According to their data, contamination of the BTB grafts was only 10%. Badran et al. [15] reported the incidence of contamination to be 16.7%, while it was as much as 23% according to Plante et al. [16].

Gavrilidis et al. [17] who investigated the possible causative agents of septic arthritis after the reconstruction of anterior cruciate ligament with the hamstring tendon graft, used the similar method. They took graft swabs immediately prior to its implementation. Graft contamination on their sample was 10%.

Table 3. Graft contamination incidence according to types of operation

Tabela 3. Incidencija kontaminacije kalema u zavisnosti od tipa operacije

Type of surgery Vrsta operacije	Culture/Bris					
	Negative/Negativan		Positive/Pozitivan		Total/Ukupno	
	N	%	N	%	N	%
Ligamentoplasty/Ligamentoplastika	90	53.9	9	28.1	99	49.7
Ligamentoplasty and meniscectomy Ligamentoplastika i meniscektomija	77	46.1	23	71.9	100	50.3
Total/Ukupno	167	100	32	100	199	100

Vertullo et al. [18] published that *coagulase negative Staphylococcus* was the main cause of contamination in 75% of cases. Barrios et al. [19] recognized that Gram-negative pathogens were responsible for the occurrence of contamination in 80% of cases during the examination of bone allograft contamination in 987 patients. We also showed that the same pathogen was responsible for graft contamination. *Staphylococcus spp* coagulase negative was isolated in 24 cases (72.7%), *Staphylococcus aureus* in 6 cases (18.2%), *Acinetobacter* in 2 (6.1%) and *Staphylococcus viridans* in 1 case (3%). A high incidence of isolated coagulase-negative *Staphylococci* was reported not only in our study but Sajovic et al. [20] also showed that *Staphylococcus spp.* coagulase negative was the main cause of contamination in 93% of their cases.

The duration of surgery in our study proved to be a vital factor that may cause the graft contamination. Babcock et al. [21] examined the reasons of postoperative infection following knee arthroscopy and they concluded that meniscectomy combined with ligamentoplasty prolonged duration of the surgery and increased possibility of graft contamination incidence. Prolonged duration of surgery causes greater graft exposure to the air, and greater graft contamination incidence. In this study, the patients with positive swabs had a longer duration of surgery. In most cases (71.9%), those were the patients who had ACL and meniscal injury together, and they underwent ACL reconstruction and one of the meniscectomy as well. Hantes et al. [6] analyzed the degree of contamination of the graft, depending on its type. They proved that the average contamination of BTB auto-grafts,

due to less exposure to the air during processing, was 10%, while the contamination of the hamstring tendons graft was a bit more frequent and amounted to 13%, which was directly associated with a prolonged exposure to the air.

Although the time of BTB graft preparation is significantly shorter than the time needed for hamstring tendons graft preparation, the time elapsed from the moment of the beginning of the graft preparation to its implantation was not significantly different between these two groups. There was no statistically significant difference in the incidence of contamination in relation to the type of graft.

Statistical differences are related to the time required for the graft preparation. They concluded that the time from the start of graft preparation to its implantation is a key factor for the occurrence of contamination.

Conclusion

According to the results of this study, statistically significant difference was found between the duration of operation with bone-tendon-bone graft compared to the hamstring tendon graft. Furthermore, a statistically significant difference in graft contamination was found between the bone-tendon-bone and hamstring group. The results of the study clearly show that the incidence of graft contamination is significantly higher in case of prolonged duration of the surgery. This is primarily related to the association of ligamentoplasty and meniscectomy within the same procedure, which is related with prolonged duration of the surgery as well as prolonged graft exposure to the air.

References

1. Busam ML, Provencher MT, Bach BR. Complications of anterior cruciate ligament reconstruction with bone-patellar tendon-bone constructs. *Am J Sports Med.* 2008;36:379.
2. Ristić V, Ninković S, Harhaji V, Stanković M, Savić D, Milankov M. Reconstruction of ACL by using two different techniques. *Med Pregl.* 2010;63(11-12):845-50.
3. Milankov M, Miličić A, Savić D, Stanković M, Ninković S, Matijević R, et al. Revision anterior cruciate ligament reconstruction due to knee instability. *Med Pregl.* 2007;60(11-12):587-92.
4. Kamath GV, Redfern JC, Greis PE, Burks RT. Revision anterior cruciate ligament reconstruction. *Am j Sport Med.* 2011;39(1):199-217.
5. Graf B, Uhr F. Complications of intra-articular anterior cruciate reconstruction. *Clin Sport Med.* 1988;7(4):835-48.
6. Hantes ME, Basdekis GK, Varitimidis SE, Giotikas D, Petinaki E, Malizos KN. Autograft contamination during preparation for anterior cruciate ligament reconstruction. *J Bone Joint Surg.* 2008;90(4):760-4.
7. Cooper DE, Arnoczky SP, Warren RF. Contaminated patellar tendon grafts: Incidence of positive cultures and efficacy of an antibiotic solution soak: an in vitro study. *Arthroscopy.* 1991;7:272-4.
8. Molina ME, Nonweiller DE, Evans JA, Delee JC. Contaminated anterior cruciate ligament grafts: the efficacy of 3 sterilization agents. *Arthroscopy.* 2000;16:373-8.
9. Alomar AZ, Somily AM, Alraiyes TM, Bin Nasser AS, Aljassir FF. Quantification analysis of the intraoperative bacterial contamination rate and level in osteochondral autografts. *Am J Sports Med.* 2016;44(3):761-6.
10. Izquierdo R Jr, Cadet ER, Bauer R, Stanwood W, Levine WN, Ahmad CS. A survey of sports medicine specialists investigating the preferred management of contaminated anterior cruciate ligament grafts. *Arthroscopy.* 2005;21:1348-53.
11. Gavriilidis I, Pakos EE, Wipfler B, Benetos IS, Paessler HH. Intra-operative hamstring tendon graft contamination in anterior cruciate ligament reconstruction. *Knee Surg Sports Traumatol.* 2002;17(9):1043-7.
12. Whyte W, Hodgson R, Tinkler J. The importance of airborne bacterial contamination of wounds. *J Hosp Infect.* 1982;3(2):123-35.
13. Alp E, Bijl D, Bleichrodt RP, Hansson B, Voss A. Surgical smoke and infection control. *J Hosp Infect.* 2006;62(1):1-5.
14. Brown AR, Taylor GJS, Gregg PJ. Air contamination during skin preparation and draping in joint replacement surgery. *J Bone Joint Surg Br.* 1996;78(1):92-4.
15. Badran MA, Moemen DM. Hamstring graft bacterial contamination during anterior cruciate ligament reconstruction: clinical and microbiological study. *Int Orthop.* 2016;40(9):1899-903.
16. Plante MJ, Li X, Scully G, Brown MA, Busconi BD, DeAngelis NA. Evaluation of sterilization methods following

contamination of hamstring autograft during anterior cruciate ligament reconstruction. *Knee Surg Sports Traumatol.* 2013;21(3):696-701.

17. Gavriilidis I, Pakos EE, Wipfler B, Benetos IS, Paessler HH. Intra-operative hamstring tendon graft contamination in anterior cruciate ligament reconstruction. *Knee Surg Sports Traumatol.* 2002;17(9):1043-7.

18. Vertullo CJ, Quick M, Jones A, Grayson JE. A surgical technique using presoaked vancomycin hamstring grafts to

decrease the risk of infection after anterior cruciate ligament reconstruction. *Arthroscopy.* 2011;28(3):337-42.

19. Barrios RH, Leyes M, Amillo S, Oteiza C. Bacterial contamination of allografts. *Acta Orthop Belg.* 1994;60(2):152-4.

20. Sajovic M, Lesnicar G, Dernovsek MZ. Septic arthritis of the knee following anterior cruciate ligament reconstruction. *Orthop Rev (Pavia).* 2009;1(1):e3.

21. Babcock HM, Carroll C, Matava M, L'Ecuyer P, Fraser V. Surgical site infections after arthroscopy: outbreak investigation and case control study. *Arthroscopy.* 2003;19(2):172-81.

Rad je primljen 2. 11. 2016.

Recenziran 10. 12. 2016.

Prihvaćen za štampu 16. 12. 2016.

BIBLID.0025-8105:(2016):LXIX:Suppl 1:67-71.



Ward D of the Department of Orthopedic Surgery and Traumatology
D Odeljenje Klinike za ortopedsku hirurgiju i traumatologiju

Clinical Center of Vojvodina, Novi Sad
Department of Orthopedic Surgery and Traumatology¹
University of Novi Sad, Faculty of Medicine²

UDK 616.728.4-072.1
DOI: 10.2298/MPNS16S1073K

ANKLE ARTHROSCOPY

ARTROSKOPIJA SKOČNOG ZGLOBA

Vaso KECOJEVIĆ¹, Ivica LALIĆ^{1,2}, Vladimir HARHAJI^{1,2}, Predrag RAŠOVIĆ^{1,2},
Miodrag VRANJEŠ^{1,2} and Mirko OBRADOVIĆ^{1,2}

Summary

Introduction. Ankle arthroscopy provides better visualization, less tissue trauma, faster recovery, shorter hospitalization and reduced treatment costs. Complication rates are lower in relation to the classic open approach. This study was aimed at presenting the surgical technique, its advantages and limitations, complications as well as our experience. **Material and Methods.** We performed 31 ankle arthroscopies in 23 male and 8 female patients in the period from October, 2007 to 1 September 2016. All surgeries were performed with tourniquet applied on the thigh, using standard arthroscopy portals, with the optic 4.0, 30 degrees. Anterior and posterior bony and soft tissue impingements were found in 23 patients, 4 patients had osteochondral defects of the talar dome, loose bodies were seen in 4 patients. The majority of patients were athletes and recreational sportspeople (29 cases). The average duration of surgery was 25 minutes. The average stay in hospital was one day. Full weight-bearing was achieved 18 days after surgery on average (from 10 to 28 days). There were no infections. Transitory palsy of *superficial peroneal* nerve was recorded in three cases. **Results.** The average American Orthopedic Foot and Ankle Score value was 46 before surgery and 92 after surgery. According to Foot and Ankle Outcome Score there were improvements in the postoperative range of motion, alleviation of pain, longer walking distance and improvement in daily living activities. **Conclusion.** Ankle arthroscopy resulted in a significant postoperative improvement in functional scores in our study sample.

Key words: Ankle Joint; Arthroscopy; Treatment Outcome; Patient Outcome Assessment; Disability Evaluation; Pain Measurement

Introduction

Ankle arthroscopy became important in the past decade. It is used as diagnostic and therapeutic procedure in acute and chronic cases, and it replaced open surgery [1]. Its application is getting wider because more and more people go in for sports which leads to increased trauma or overuse injuries of the ankle joint. The overall incidence of ankle and foot trauma is high, accounting up to 40% of all injuries in athletes. Of that number 20% to 30% will have some residual problems [2]. The main indications for ankle arthroscopy are ankle impingement, osteochondral and chondral defects, cartilage degeneration, joint instability and synovitis. Depending on the location of injury, anterior,

Sažetak

Uvod. Artroskopija skočnog zgloba omogućava bolju vizuelizaciju, manju traumatizaciju tkiva i brži oporavak, skraćen broj bolničkih dana, smanjenu cenu lečenja. Komplikacije su procentualno smanjene u odnosu na klasičnu hirurgiju. Cilj rada je upoznavanje sa hirurškom tehnikom, prednostima i ograničenjima, komplikacijama, i našim iskustvima. **Materijal i metode.** Od oktobra 2006. godine do septembra 2016. godine artroskopija skočnog zgloba radena je kod 31 pacijenta (23 muškarca i 8 žena). Operacije su radene u ishemiji kroz standardne pristupe, optikom 4.0, 30 stepeni. Prednji i zadnji koštani i mekotkivni *impingement* je bio zastupljen kod 23 pacijenta, osteohondralne lezije talusa kod četiri, zglobna tela kod četiri. Sportisti i aktivni rekreativci bili su najzastupljeniji (ukupno 29). Prosečno trajanje operacije bilo je 25 minuta. Pacijenti su provodili u bolnici u proseku jedan dan. Pun oslonac je u proseku bio postignut 18. postoperativnog dana (10–28). Nismo imali infekcije. Kod tri pacijenta je registrovana tranzitorna pareza *n. peroneus superficialis*. **Rezultati.** Prosečne vrednosti *American Orthopedic Foot and Ankle Score* bile su 46 preoperativno, 92 postoperativno. Prema upitniku *Foot and Ankle Outcome Score* došlo je do postoperativnog povećanja obima pokreta, smanjenja bola, povećanja distance hoda i poboljšanja aktivnosti dnevnog života. **Zaključak.** Artroskopske operacije skočnog zgloba, na našem uzorku, dovele su do značajnog poboljšanja funkcionalnih skorova postoperativno.

Gljučne reči: skočni zglob; artroskopija; ishod lečenja; pacijentova procena ishoda; merenje bola

posterior or combined approach can be used. There are differences in surgical technique used in the world: in Europe and Asia surgeons use the so called dorsiflexion method, while in the United States of America surgeons use non-invasive distraction technique [3–5]. It has taken a long time to establish ankle arthroscopy, and turn it from diagnostic to therapeutic procedure. The first article on ankle arthroscopy was published by Burmnan [6] in 1931. He said that the ankle joint was unsuitable for arthroscopy because of the anatomy. But only eight years later, in 1939, the first ankle arthroscopy was performed by Kenji Tagaki [7]. Watanabe reported a series of 28 ankle arthroscopies in 1972 [8]; and Chen published his work on a series of 67 patients in 1976 [9]. The shape of the articular surfaces

Abbreviations

CT	– computed tomography
MRI	– magnetic resonance imaging
ADL	– activities of daily living
AOFAS	– American Orthopedic Foot and Ankle Score
FAOS	– Foot and Ankle Outcome Score
OCD	– osteo-chondral defect
MTP	– metatarso phalangeal
IP	– inter phalangeal
QOL	– quality of life

and little joint laxity was the main reason for difficulty in performing ankle arthroscopy. In 1988 Guhl and Ferkel [3, 10] introduced invasive distraction technique. It was later replaced with non-invasive distraction that produced less complications. Van Dijk and Scholte [11] introduced the dorsiflexion method in 1997. With foot in dorsiflexion, the complication rate was further decreased, and ankle arthroscopy became more popular among surgeons in Europe. Development in technology, such as video transmission, fibre optics, small instruments and cameras, computed tomography (CT) and magnetic resonance imaging (MRI) diagnostics are of the great influence in arthroscopy procedures, particularly the ankle arthroscopy.

Material and Methods

A retrospective study, which was conducted from October 2007 to September 2016, included 31 patients (23 males and 8 females) who had undergone ankle arthroscopy. Inclusion criteria were pain, reduced range of motion, swelling, and no response to physical

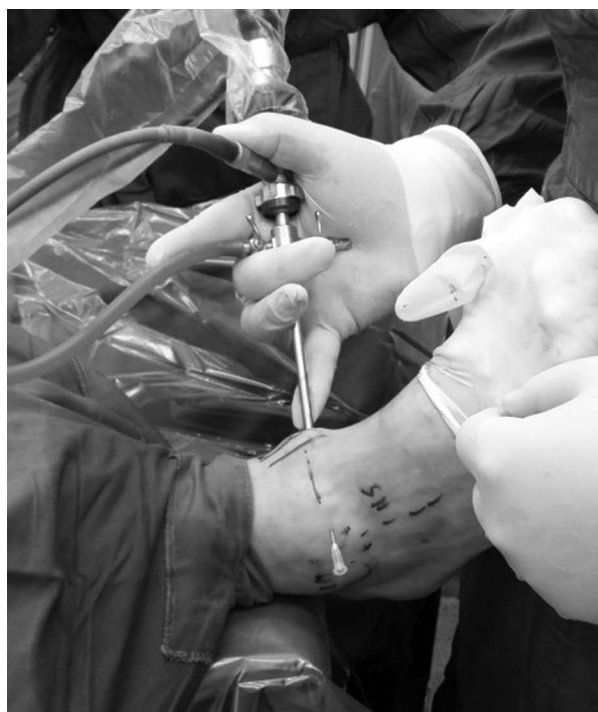

Figure 1. Introducing optic through anteromedial portal
Slika 1. Uvođenje optike kroz anteromedijalni portal


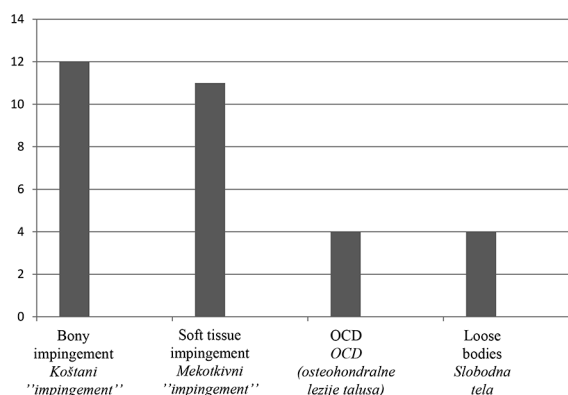


Figure 2. OCD talus prepared for microfracturing anteromedial portal

Slika 2. Osteo-hondralni defekt talusa pripremljen za mikrofrakturu

therapy in the previous six months. Exclusion criteria were infection at the site of ankle and the radiographic signs of narrowing of the joint space that suggested the presence of ankle osteoarthritis. Anterior and posterior bony and soft tissue impingements were treated in 23 patients, osteochondral defects of the talar dome loose bodies were treated in 4 patients, each (**Graph. 1**).

The majority of patients were athletes and recreational sportspeople (29 cases). The follow-up period was 1 year on average (ranging from 1 month to 18 months). The average duration of surgery was 25 minutes. The average stay in hospital was one day. Full weight-bearing was achieved 18 days after surgery on average (from 10 to 28 days). There were no infections. Transitory palsy of *superficial peroneal* nerve was recorded in three cases. Prior to surgery, radiographs, CT or MRI diagnostic were performed. If bony impingement was seen on standard radiographs we did not use CT or MRI. Surgeries were performed with tourniquet applied on the thigh, using general or epidural anesthesia. The patients were placed in supine or prone position, depending on the pathology that had



Graph. 1. Pathology distribution
Grafikon 1. Distribucija patologije

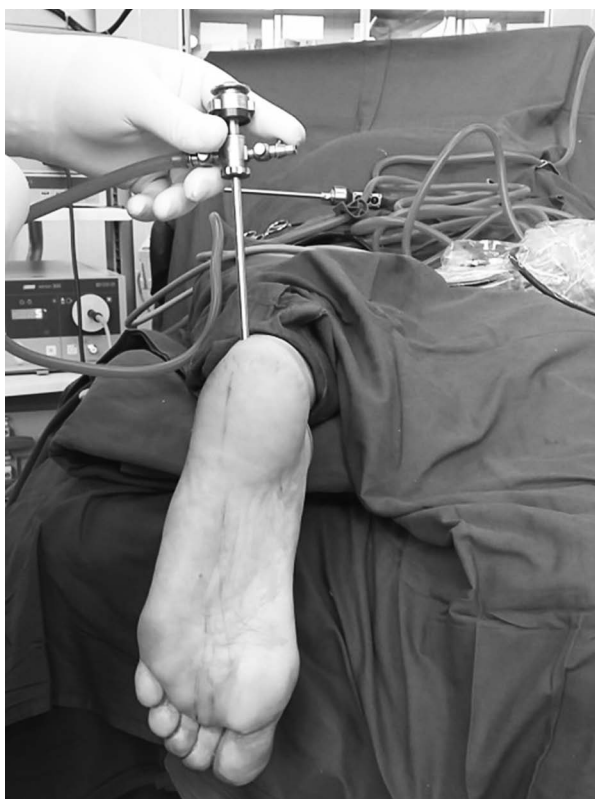

Figure 3. Trocar placed through posterolateral portal
Slika 3. Vodič postavljen kroz posterolateralni portal

to be treated. The affected limb was placed in a slight elevation and with the foot at the edge of the operating table, thus enabling the surgeon to manipulate with the foot and to dorsiflex it fully. The joint distraction was performed by an assistant. Standard anteromedial and anterolateral portals were used for anterior ankle arthroscopy (**Figures 1 and 2**), and posterolateral and posteromedial portals were used for posterior an-

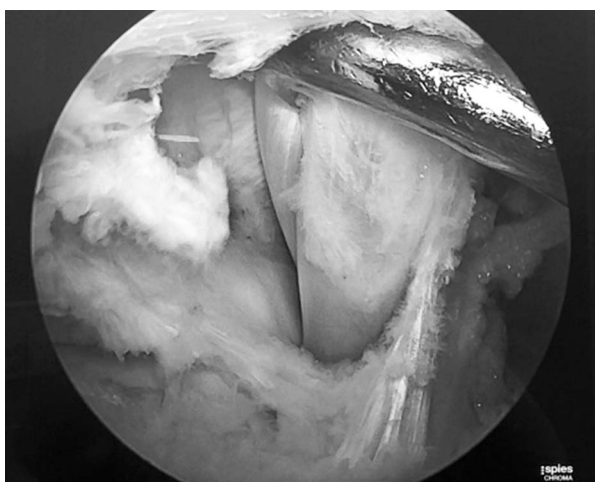

Figure 4. Flexor hallucis longus tendinosis of posterolateral portal
Slika 4. Tendinoza tetive dugog pregibača palca

kle arthroscopy, as described by van Dijk [12] (**Figures 3 and 4**).

The arthroscope which we used was 4 mm wide at the angle of 30 degrees, without an arthropump. The landmarks were drawn on the skin prior to the skin incision. After surgery the wound was closed by single sutures, and an elastic bandage was applied running from the foot to the knee. The patients were discharged from hospital the day after surgery, they were allowed to walk on the crutches without weight-bearing for 3 days, and after that with progressive load.

Results

The results were assessed by means of two scoring systems. The American Orthopedic Foot and Ankle Society Score (AOFAS) [13] is one of the most widely used clinician-reporting tools for foot and ankle conditions. Developed in 1994, AOFAS is a clinician-based score that measures outcomes for four different anatomic regions of the foot: the ankle-hindfoot, midfoot, metatarsophalangeal (MTP)-interphalangeal (IP) for the hallux, and MTP-IP for the lesser toes. The four anatomic regions of the AOFAS are all represented by a different version of the survey with each tool designed to be used independently. The questionnaire consists of nine items that are distributed over three categories: Pain (40 points), function (50 points) and alignment (10 points). These are all scored together for a total of 100 points. The average values of AOFAS score in our study was 46 before surgery and 92 after surgery.

Foot and Ankle Outcome Score (FAOS) [14] was developed to assess the patients' opinion about a variety of foot and ankle-related problems. FAOS consists of 5 subscales: pain, other symptoms, function in daily living (ADL), function in sport and recreation (Sport/Rec), and foot and ankle-related Quality of Life (QOL). The previous week has to be taken into consideration when answering the questionnaire. Standardized answer options are given and each question gets a score from 0 to 4. A normalized score (100 indicating no symptoms and 0 indicating extreme symptoms) is calculated for each subscale. In our study sample there were improvements in the postoperative range of motion, alleviation of pain, longer walking distance and improvement in daily living activities.

Conclusion

Ankle arthroscopy is one of the latest surgical procedures performed at our Department. Although we have a lot of experience in knee arthroscopy, the ankle arthroscopy is the field that we want to enter more rapidly. A limitation of the study is a small number of patients treated by ankle arthroscopy. However, in spite of a small sample we have achieved satisfactory results according to American Orthopedic Foot and Ankle Score and Foot and Ankle Outcome Score system. The first results have encouraged us to continue to improve our skills.

References

1. Milankov M, Jovanović A, Miličić A, Savić D, Stanković M, Kecojević V, et al. Knee arthroscopy: "surgery without complications". *Med Pregl*. 2000;53(3-4):187-92.
2. Shah S, Weiss DS, Burchette RJ. Injuries in professional modern dancers: incidence, risk factors, and management. *J Dance Med Sci*. 2012;16:17-25.
3. Guhl JF. New concepts (distraction) in ankle arthroscopy. *Arthroscopy*. 1998;4:160-7.
4. Rouvillian JL, Daoud W, Donica A, et al. Distraction-free ankle arthroscopy for anterolateral impingement. *Eur J Orthop Surg Traumatol*. 2014;24:1019-23.
5. De Leeuw PA, Golano P, Clavero JA, et al. Anterior ankle arthroscopy, distraction or dorsiflexion? *Knee Surg Sports Traumatol Arthrosc*. 2010;18:594-600.
6. Burman MS. Arthroscopy or the direct visualization of joints: an experimental cadaver study. 1931. *Clin Orthop Relat Res*. 2001;390:5-9.
7. Tagaki K. The arthroscope. *Jpn J Orthop Assn*. 1939; 14:359.
8. Watanabe M. Selfoc arthroscope. Watanabe No. 24 Arthroscopy. Tokyo, Japan: Teishin hospital; 1972.
9. Chen YS. Clinical and cadaver studies on the ankle joint arthroscopy. *J Jpn Orthop Assoc*. 1976;50:631-51.
10. Ferkel RD, Fischer SP. Progress in ankle arthroscopy. *Clin Orthop Relat Res*. 1989;240:210-20.
11. van Dijk CN, Scholte D. Arthroscopy of the ankle joint. *Arthroscopy*. 1997;13:90-6.
12. van Dijk CN. Anterior and posterior ankle impingement. *Foot Ankle Clin*. 2006;11:663-83.
13. SooHoo NF, Vyas R, Samini, D. Responsiveness of the foot function index, AOFAS clinical rating systems, and SF-36 after foot and ankle surgery. *Foot Ankle Int*. 2006;27:930-4.
14. Roos EM, Brandsson S, Karlsson J. Validation of the foot and ankle outcome score for ankle ligament reconstruction. *Foot Ankle Int*. 2001;22:788-94.

Rad je primljen 2. 11. 2016.

Recenziran 10. 12. 2016.

Prihvaćen za štampu 16. 12. 2016.

BIBLID.0025-8105:(2016):LXIX:Suppl 1:73-76.

Clinical Center of Vojvodina, Department of Orthopedic Surgery and Traumatology¹
 University Novi Sad, Faculty of Medicine²
 Atlas Hospital, Belgrade³

UDK 616.728.3-08:602.6
 DOI: 10.2298/MPNS16S1077D

IN STEP WITH CONTEMPORARY TRENDS-STEM-CELLTHERAPY AS A KEY DRIVER OF REGENERATIVE ORTHOPEDICS AT THE CLINICAL CENTER OF VOJVODINA – PRELIMINARY DATA FOR THE TREATMENT OF KNEE OSTEOARTHRITIS AND OSTEOCHONDRAL LESIONS

U KORAK SA SAVREMENIM TRENDOVIMA – TERAPIJA MATIČNIM ČELIJAMA KAO KLJUČNI POKRETAČ REGENERATIVNE ORTOPEDIJE U KLINIČKOM CENTRU VOJVODINE – PRELIMINARNI REZULTATI LEČENJA OSTEOARTRITISA I OSTEOCHONDRALNIH LEZIJA

Oliver DULIĆ¹, Ivica LALIĆ^{1,2}, Nataša JANJIĆ^{1,2}, Predrag RAŠOVIĆ^{1,2},
 Gordan GAVRILOVIĆ³ and Džihan ABAZOVIĆ³

Summary

Introduction. In the treatment of various orthopedic conditions, regenerative therapies, including *platelet rich plasma* and autologous stem-cell therapy, have recently been advancing. Knee cartilage lesions are a debilitating disease resulting in fibrillation and subsequent degradation which can also involve the subchondral bone and lead to the development of osteoarthritis. Bone marrow mesenchymal stem cells are a heterogeneous mixture of cells involved in cartilage formation and regenerative repair, whereas other mesenchymal stem cells have the capacity to play a role as immunomodulatory and trophic factors. Nowadays, stem-cell therapy is widely used for the treatment of knee osteoarthritis and cartilage lesions. The purpose of this study was to evaluate preliminary clinical data of treatment of knee osteoarthritis with stem cell injection and treatment of osteochondral lesions with stem-cell scaffold. **Material and Methods.** Stem cells were obtained by concentrating the content taken with aspiration needles from the bone marrow by means of Arthrex Angel Bone Marrow Aspirate Concentrate centrifuge. **Results.** The study sample consisted of 39 patients who were included in knee osteoarthritis treatment. Surgical implantation was performed in 7 patients from the osteochondral group. In the first group, an average Visual Analogue Scale pain felt before intervention decreased statistically significantly three days after the intervention (from 7.27 to 2.12, $p \leq 0.05$) and remained 1.2 until the check-up after 3 months. The same results were achieved in the average Western Ontario and McMaster Universities Arthritis Index score (prior to intervention=51.5; after 1 month=72 and after 3 months=76). For the second group, an average pre-intervention Visual Analogue Scale pain decreased statistically significantly three days after intervention (from 8.1 to 2.7) and remained 1.2 until the check-up after 3 months. The same results were achieved on the Knee injury and Osteoarthritis Outcome Score pain ($p \leq 0.05$). Both procedures were proved as safe providing pain relief and function improvement of treated knee joints.

Key words: Stem Cell Transplantation; Bone Marrow Cells; Regenerative Medicine; Osteoarthritis, Knee; Osteochondritis; Cartilage, Articular; Orthopedic Procedures; Pain Measurement

Sažetak

Uvod. Regenerativna medicina danas je klinička realnost u tretmanu mnogih ortopedskih stanja unazad nekoliko godina. Pored terapije *platelet rich plasma*, terapija matičnim ćelijama postaje sve popularnija. Lezije hrskavice predstavljaju onesposobljavajuću bolest koja vremenom progredira ka zdravoj hrskavici i suphondralnoj kosti; dovodeći do razvoja osteoartritisa. Matične ćelije poreklom iz koštane srži su heterogena mešavina ćelija koje učestvuju u formiranju i regeneraciji hrskavice, ali imaju i imunomodulatorna i trofička svojstva. Danas je korišćenje terapije matičnim ćelijama široko rasprostranjeno za lečenje kako osteoartritisa tako i za lečenje lezije hrskavice velikih zglobova. Cilj ovog rada bio je da se predstavje preliminarni klinički rezultati lečenja osteoartritisa injekcijama matičnih ćelija kao i lečenja osteochondralnih lezija skafoldima od matičnih ćelija. **Materijal i metode.** Matične ćelije su dobijene koncentrovanjem sadržaja uzetog punkcijom iz koštane srži uz pomoć *Arthrex Angel* centrifuge. **Rezultati.** U našoj ustanovi, 39 pacijenata lečeno je injekcijama matičnih ćelija, dok je sedam pacijenata lečeno implantacijom matičnih ćelija u autologi biološki skafold. Kod prve grupe, skala bola *Visual Analogue Scale* značajno je pala tri dana nakon intervencije (od prosečno 7,27 na 2,12, $p \leq 0,05$) i održavala se niskom do trećeg meseca sa rezultatom 1,2. Slični rezultati su postignuti i na skali *Western Ontario and McMaster Universities Arthritis Index* (pre-interventno = 51,5; prvi mesec = 72 i treći mesec = 76). U drugoj grupi, skala bola *Visual Analogue Scale* značajno je pala tri dana nakon intervencije (od prosečno 8,1 na 2,7, $p \leq 0,05$) i održavala se niskom do trećeg meseca sa rezultatom 1,2. Slični rezultati postignuti su i na skali bola *Knee injury and Osteoarthritis Outcome Score*. **Zaključak.** Obe procedure su dokazane kao bezbedne po pacijente sa dramatičnim poboljšanjem funkcije tretiranog kolena i smanjenjem bola.

Ključne reči: transplantacija stem ćelija; ćelije koštane srži; regenerativna medicina; osteoarthritis kolena; osteochondritis; zglobna hrskavica; ortopedske procedure; merenje bola

Abbreviations

BMAC	– Bone Marrow Aspirate Concentrate
FASSG	– autologous scaffold covered by bio-regenerative glue augmented with growth factors
IL	– Interleucin
KCV	– Clinical Center of Vojvodina
MSc	– mesenchymal stem cells
OA	– osteoarthritis
OH	– osteochondral
PRP	– platelet rich plasma
PRF	– platelet rich fibrin
TNF	– tumor necrosis factor
VEGF	– vascular endothelial growth factor

Introduction

At the very beginning, we would like to present a short historical overview of regenerative orthopedics at the Department of Orthopedic Surgery and Traumatology, Clinical Center of Vojvodina (CCV) which is at the disposal of our patients. Our Center is the only state-owned hospital having modern equipment and well educated teams capable of offering adequate, contemporary and state-of-the-art regenerative orthopedic procedures. The first regenerative procedures were established 3 years ago when our Center was equipped with the Vivotat® System and a sufficient number of Platelet Rich Fibrin sets (PRF). Early pioneers of these procedures were focused on intra-articular injections of PRF for treatment of osteoarthritis (OA) and soft tissue infiltrations for treatment of painful syndromes such as tennis and golf elbow, rotator cuff tear, subacromial bursitis, muscle and ligament injuries, etc. Unfortunately, there were no methodological records of follow-up results. Encouraged by great results and high levels of patient's satisfaction following the functional improvement our surgeons continued to widen the spectrum of potential regenerative options and to extend their knowledge base. Surgical implantation of bioregenerative scaffold with stem cells from bone marrow aspirate concentrate (BMAC) for treatment of osteochondral (OH) lesion was performed for the first time in our country in November 2015, at the Clinical Center of Vojvodina. It was conducted by Prof. Dusan Maric, Prof. Dragan Savic and Dr. Vaso Kecojevic and supervised by Prof. Stefano Zanasi from the Rizzoli Institute, Bologna, Italy. At the end of 2015, the Clinical Center of Vojvodina applied for the Provincial state funding with a Project for Treatment of OA and osteochondral lesions with BMAC. Upon the approval of budget, the Department was equipped with an Arthrex®Angel centrifuge as well as a number of sets for BMAC and PRP production with the aim of offering the most modern therapy options for our clients but also to extend the base for scientific research. Nowadays, BMAC and PRP therapy is widely used for treatment of OA in knee and hip, OH lesions, avascular necrosis of femoral head and condyles, non-union fractures and a wide

range of soft-tissue pathologies. This project has consequently opened the door for a number of clinical studies approved by ethical and state authorities for research of clinical application of stem cells in different orthopedic conditions.

Regenerative adjunctive treatment is the next logical step in the progression of surgical intervention. Biologically augmented or regenerative techniques are at the very forefront of modern treatment and have the potential to transform the practice of medicine and surgery significantly in a very short period. Although the basic science remains in its infancy, especially in the areas of signaling, regulation, and mechanism, regenerative knowledge has expanded significantly in volume and across disciplines [1]. In the treatment of various orthopedic conditions, regenerative treatments have recently been advanced, including platelet-rich plasma and autologous stem-cell therapy. The term orthobiologics has been used to describe these various biologic agents that are obtained directly from our bodies tapping into our own intrinsic capabilities to heal [2]. Multiple studies on platelet-rich plasma have been published that demonstrate the modulation of pain and inflammation in degenerative arthritis of the knee [3–7] and the healing capabilities of this treatment for chronic refractory tendinopathies [8, 9]. On the other hand, studies are emerging that support the benefit of mesenchymal stem cells (MSC) for cartilage pathology including osteoarthritis and osteochondral lesions. Positive functional outcomes have been reported 12 (for OA) to even 60 months after implantation of stem cells in different types of treatment options for OH lesions, but future work is required to assess long-term outcomes with respect to other treatment modalities [10–14]. Besides varying degrees of beneficial clinical outcomes, most currently published articles have reported that the application of BMAC is a safe procedure without any complications which occur in general population according to the statistics [15].

Articular cartilage lesions are a debilitating disease resulting in fibrillation and subsequent degradation which can also involve the subchondral bone and lead to the development of OA [16, 17]. One limiting factor in the repair of these defects is the well-known low intrinsic regeneration potential of cartilage, which might be due to the difficulty encountered by progenitor cells from the blood, bone marrow, or even other compartments in entering the defect and the inability of resident articular chondrocytes that are entrapped within the surrounding matrix to migrate into the lesion to secrete a reparative matrix [18]. The avascular, aneural, and alymphatic nature of articular cartilage hinders repair and regeneration potential once injured. Articular cartilage lesions may be focal defects resulting from direct trauma, avascular necrosis (AVN), or osteochondritis dissecans. These lesions are described as chondral (limited to the cartilage surface) or osteochondral (extending beyond the calcified

cartilage layer into the subchondral bone). Chondral lesions have a poor intrinsic ability to repair themselves because they lack blood vessels that are critical for circulation and delivery of progenitor cells as a part of the normal healing processes. Instead of progenitor cells filling chondral defects, cells from the synovial membrane migrate to the articular cartilage defect and fail to integrate completely, leading to continued degeneration. In contrast, osteochondral lesions have access to the bone marrow, which provides a supply of mesenchymal stem cells that can create the repair tissue [18]. This tissue, however, resembles fibrocartilage, which does not integrate well with the adjacent matrix and does not withstand mechanical stress, resulting in eventual degeneration over time. Articular cartilage lesions may also be more generalized, or diffuse and lacking lesion margins as in degenerative joint disease or OA. Once early OA begins, the repair capacity of articular cartilage is further compromised by a cascade of catabolic events including inflammation, recruitment of cells that release pro-inflammatory factors, and proteinase activation that leads to degeneration and cell senescence with apoptosis. Disease progression is believed to result from an imbalance between pro-inflammatory cytokines (including interleukin 1a (Il-1a), IL-1, and tumor necrosis factors (TNF) and anti-inflammatory cytokines (including IL-4, IL-10, and IL-1ra) [18]. This cytokine imbalance is thought to promote proteolytic enzymes, which lead to cartilage deterioration [19–22]. In addition, the subchondral trabecular bone is thought to play an important role in OA because subchondral bone changes are potentially both a result and a cause of cartilage loss [23].

Bone marrow MSCs are a heterogeneous mixture of cells with at least two different functions. Some of these cells are already involved in the osteogenic pathway and accelerate bone formation and regenerative repair [24–27], whereas other MSCs have the capacity to play a role as immunomodulatory and trophic factor [28]. These MSCs are formed at broken and inflamed blood vessels where the local pericyte detaches from the vessel and becomes an activated MSC. This *in situ* MSC secretes a curtain of bioactive agents that locally inhibit the over-aggressive immune system from sending in integrating cells. This is the body's first line of control and defense against establishing an autoimmune reaction against the antigens exposed by the injured tissue [1].

The "trophic" effects of MSCs establish a regenerative microenvironment at the site of injury by (a) inhibiting ischemia-related apoptosis, (b) by inhibiting scar formation, (c) by stimulating angiogenesis by secreting large amounts of vascular endothelial growth factor (VEGF) and by transforming some of the MSCs back into pericytes that function to stabilize the fragile, newly forming capillaries, and (d) by secreting tissue progenitor-specific mitogens

so that the slow process of tissue regeneration is enhanced [29]. In conclusion, MSCs serve as "drug stores" [28, 29] for sites of injury and/or inflammation by providing an array of bioactive molecules tailored for that site and the injury [1]. MSCs are characterized on the basis of surface expression markers as CD73, CD90, and CD105 positive, and CD34 and CD45 negative [30].

Adult stem cells consist of 2 general classifications: hematopoietic stem cells, which are responsible for the formation of blood products, and mesenchymal stem cells (MSCs) [8]. In the early 1990s, adult MSCs were discovered to have an active role in connective tissue repair [31]. Since that time, impressive progress toward the development of safe clinical applications for MSC-mediated therapy has been achieved. It is now technically feasible to harvest tissue cells, culture them (if needed) to expand the cell population, and then inject these cells directly into areas of injury. Several injectable stem-cell therapies with differing cell origins now abound, including MSCs, tenocyte-derived stem cells, adipose-derived stem cells, amniotic-derived cells, and dermal fibroblasts. The most well-studied sources of MSCs include bone marrow derived MSCs and adipose-derived stem cells [8].

Bone marrow concentrate contains bone marrow derived mesenchymal stem cells, hematopoietic stem cells, platelets (containing growth factors), and cytokines. Bone marrow cells consist of erythroblasts, neutrophils, eosinophils, basophils, monoid cells (monocytes containing mesenchymal stem cells and macrophages), lymphocytes, and plasma cells [18]. These cells are present in various stages of differentiation [32]. The hematopoietic progenitor cells can morph into mesenchymal stem cells, differentiate into chondrocytes, and are more osteoinductive than adipose-derived cells [33]. Following the knowledge base derived from pre-clinical, basic studies about the role of MSC in an inflammatory environment in the knee, a ratio for the treatment of OA and OH with stem cells from different sources is justified.

The purpose of this study is to evaluate preliminary clinical data of treatment of knee OA with BMAC injection and treatment of osteochondral lesions with BMAC and Fully Autologous Scaffold covered by bioregenerative glue augmented with growth factors (FASGG).

Material and Methods

The group included into osteoarthritis treatment (OA group) consisted of 39 outpatients complaining of knee pain who underwent physical examination, laboratory test and X-ray from April 2016 to a thorough clinical history. The study was performed only if the patients understood and agreed to the treatment method and procedure. After careful review of all the test results, the following exclusion criteria for this study were set: knee instability, severe

malignment, flexion contracture of more than 10, inflammatory arthritis such as rheumatoid arthritis and ankylosing spondylitis, presenting muscle pain, and underlying diseases such as hematologic disorders, septicemia, coagulopathy, neoplasm, active infection, and immune deficiency. According to these criteria, 39 patients who were diagnosed with degenerative arthritis (Kellgren-Lawrence grade from 2 to 4) of the knee were included in this study.

For the procedure, the patient was placed in supine position, following preparation and draping of tuberosity, then local anesthesia (Marcaine, 10 ml) was infiltrated from skin to periosteum. Autologous bone marrow of 100 cc was aspirated using Arthrex Angel BMAC set with aspiration needles. The punctured bone marrow was injected into the plastic bag including the anti-coagulant inside the kit and then mixed. The Arthrex Angel centrifuge was used to separate 6 ml cc of BMAC and an injection of BMAC was injected into the treated knee. After the intervention, the patients were allowed to go back home to return to their daily lives with a recommendation to decrease activities in next 5 to 7 days and not to take any NSAID therapy for 2 weeks. After 7 days, there was no limitation on daily routines other than the instruction to refrain from extreme exercise for 3 weeks following the intervention. The patients were followed up for VAS pain and swelling 3 and 7 days after intervention and invited for the check-up after 1 and 3 months. The clinical results were also analyzed using the WOM-AC score.

For the osteochondral lesion treatment (OH group), the procedure and surgical method of implantation were performed on 7 patients. Previously, they were recruited for the study after physical examination and magnetic resonance imaging (MRI) confirmation of cartilage lesion presence. Having given their signed consent, they were operated on under general anesthesia. For the procedure, the patient was placed in supine position, with the knee prepared for arthroscopic surgery. An amount of 100 ml cc blood was taken for PRP and platelet poor plasma (PPP) preparation and sent to a separate centrifuge for production of FASSG. Autologous bone marrow of 100 cc was aspirated by means of Arthrex Angel BMAC set. The punctured bone marrow was injected into the plastic bag including the anti-coagulant inside the kit and then was mixed. The Arthrex Angel centrifuge was used to separate 6 ml cc of BMAC. Then, the presence of lesions was confirmed by means of knee arthroscopy. The lesion was approached through the mini arthrotomy. Debridement of lesion was conducted on the borders of the damaged cartilage including the healthy cartilage tissues, and the subchondral bone of the lesion which was exposed. After the microfracture had been performed, BMAC was placed, then FASSG was placed and at the end after FASSG changed consistency and became solid, bioregenerative fibrin (BFR) was sprayed to cover the

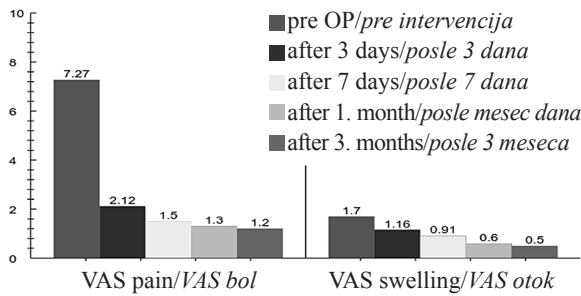
scaffold. The remaining BMAC and PRP were injected into the knee, and the wound was closed. When it was necessary to control the pain, the use of oral non-steroidal anti-inflammatory drugs was not allowed, and Acetaminophen pain relievers or opioids were prescribed. When the stitches were removed, the patients were sent to rehabilitation. The patients were banned from weight bearing in the next 4 to 6 weeks during which the patients themselves conducted the joint angle exercise until the full range of motion (ROM) was reached with an increase after 6 weeks. After that, the patients were allowed to return to their daily routines with the progression to full sports activities about 3 months after the operation. The clinical evaluation was based on the survey completed at outpatient visits before the operation and 1 and 3 months after the operation, the physical examination, and the direct follow-up. This study evaluated the degree of pain of patients through the visual analogue scale (VAS) scores, and the clinical results were analyzed by means of the International Knee Documentation Committee (IKDC). Both procedures were approved by the Ethics committee. Statistical analyses were performed with ANOVA model analyzing the differences among group means. IBM SPSS 20.0 was used for statistical calculations.

Results

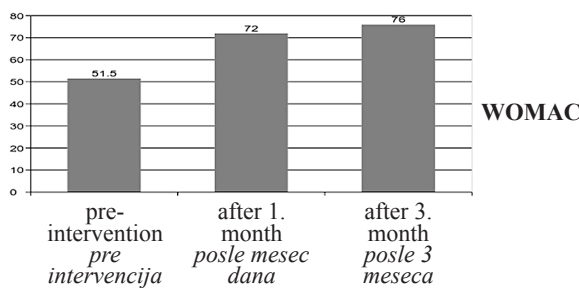
No serious adverse events were reported either in the OA or in the OH group.

The OA group consisted of 25 male (64%) and 14 female (36%) patients, whose mean age was 56 years, ranging from 38 to 75 years. The average body mass index BMI was 28.19. The average number of total nucleated cells per 1 ml was 17.2 million. The viability of cells was 98.6%. The degree of degenerative arthritis was evaluated by K-L grade (Kellgren-Lawrence grading scale) on standing anteroposterior (AP) view: there were 15 (38%) cases of grade II, 21 (53%) cases of grade III, 8 (9%) cases of grade IV. The average VAS pain was 7.27 before intervention; 2.12 after 3 days; 1.5 after 7 days; 1.3 after 1 month and 1.2 after 3 months. There was a statistically significant difference between the pre-intervention values and other values on follow-up starting from 3 days to 3 months. ($p \leq 0.05$). The average VAS swelling was 1.7 before intervention, 1.1 6 after 3 days, 0.91 after 5 days; 0.6 after 1 month and 0.5 after 3 months (**Graph. 1**). There was a statistically significant difference between the pre-intervention values and other values on follow-up starting from 3 days to 3 months. ($p \leq 0.05$). The average WOMAC score was 51.5 before intervention; 72 after 1 month and 76 after 3 months (**Graph. 2**).

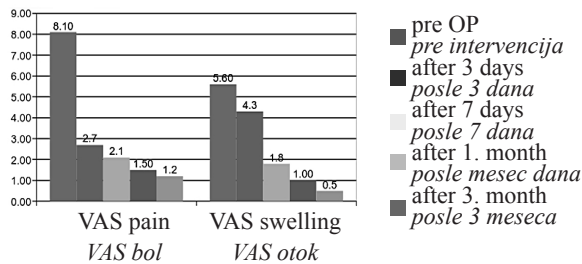
There were 6 (86%) male and 1 (14%) female patients in the OH group, whose mean age was 43 years, ranging from 30 to 59 years. The average BMI core was 28.92. The average number of total



Graph. 1. VAS pain and VAS swelling for OA group
Grafikon 1. VAS bol i VAS skala otoka za OA grupu

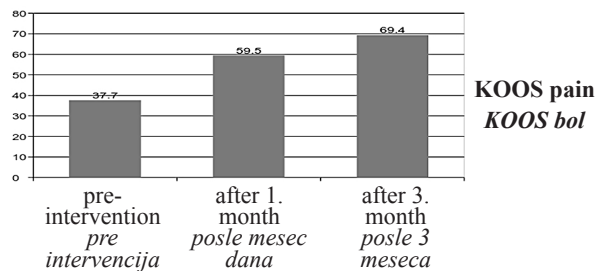


Graph. 2. WOMAC score for OA group
Grafikon 2. WOMAC skor za OA grupu



Graph. 3. VAS pain and VAS swelling for OH group
Grafikon 3. VAS bol i VAS skala otoka za OH grupu

nucleated cells per 1 ml was 19.4 million. The viability of cells was 99.1%. There were 1 medial condyle lesion, 1 lateral condyle lesion, 3 cases with both medial and lateral condyle, 1 trochlear lesion and 1 patient with lateral condyle and patella lesion. The average VAS pain was 8.1 before interven-



Graph 4. KOOS pain score for OH group
Grafikon 4. KOOS skor bola za OH grupu

tion; 2.7 after 3 days; 2.1 after 7 days; 1.5 after 1 month and 1.2 after 3 months. There were statistically significant differences between the values prior to intervention and other results starting from 3 days follow up ($p \leq 0.05$). The average VAS swelling was 5.6 before intervention, 4.3 after 3 days, 1.8 after 7 days; 1 after 1 month and 0.5 after 3 months (**Graph. 3**). There were also statistically significant differences between the values before intervention and other results starting from 3 days follow up ($p \leq 0.05$). The average KOOS pain score was 37.7 prior to intervention, 59.5 after 1 month and 69.4 after 3 months (**Graph. 4**). There were statistically significant differences between the values before intervention and other results starting from 1 month follow-up ($p \leq 0.05$).

Discussion

Osteoarthritis of the knee is a highly prevalent joint disease with prominent symptoms affecting the daily lives of millions of people. The most current evidence-based therapies focus on the symptom improvement or total joint replacement versus prevention or improvement in the progressive destruction of OA joints. The concept of intra-articular delivery of MSCs opens up novel treatment options for this disease process [34]. Consistent with previously published results from other publications, these preliminary results have shown that BMAC injection in the knee is a safe procedure, without any serious adverse effects. Significant improvement of knee function and pain relief, with immense analgesic effect in a previously painful knee (measured by a significant decrease in VAS pain score after 3 days and continuation of good results measured by a decrease of pain and an increase of joint function as far as 3 months after one injection), were confirmed. Besides, preliminary results among the patients treated with a FASSG have shown very encouraging results with a dramatic increase of KOOS and a decrease in VAS pain score starting from one month after surgical intervention followed by further improvement after 3 months.

Not much is known about this topic which is confirmed by numerous pre-clinical studies; whereas studies done at the clinical level are characterized by methodological shortcomings, small study samples and short follow-up period. Nonetheless, the available studies suggest a potential for these cell-based treatments to be developed in many directions, with different available cell sources, the possibility to use them concentrated or expand them in vitro, to apply them as a simple minimally invasive injective approach, or to be delivered surgically, alone or augmented with growth factors or scaffolds, and many other improvements are being developed. Mesenchymal stem cells in cartilage regeneration represent a promising new approach with preliminary interesting findings ranging from focal chondral defects to articular OA degeneration. How-

ever, many aspects are still controversial, and they have to be clarified [35].

Safety of the BMAC therapy was investigated in many trials, both for scientific, clinical or regulatory purposes [10, 15, 35, 36]. Our safety results are similar to previously published reports of BMAC use in osteoarthritic knees as they were without pain. There was no clinical evidence to suggest that treatment with MSCs (alone or in mixture with other stem cells or PRP) increase a risk of neoplasm, immunological or other related diseases. Having performed an investigation in multi-center analysis among 2,372 adults undergoing autologous stem-cell therapy Centeno C. et al. concluded that the rate of reported neoplasms is even lower in treatment group in comparison with the general population [15]. Lack of any adverse events is logical; BMAC, with its ingredients is fully autologous so there is no single substance which could elicit to any foreign body reactions which could induce reactions to foreign body, immunological attacks or toxic spreads. With these interventions, we simply transplant specific body cells from one body part to the other because there is no way to be transported through circulation.

There is a general agreement among researchers about pain relief reaction after BMAC injection in the knee [18, 37–39]. Therefore, theories of MSC paracrine signaling mechanisms to modulate joint homeostasis have further been corroborated by many BMAC studies demonstrating symptomatic pain relief, despite low cell numbers compared with culture-expanded techniques [29, 40, 41].

Having analyzed our preliminary results after surgical transplantation of BMAC in FASSG, we are encouraged with almost full absence of knee pain, which was a dominant sign before the surgery. In addition, a dramatic increase of joint function additionally supports our belief in this method. Although it is very early for arthroscopic or MRI diagnostic of cartilage defect consistency, we believe that after these clinical signs, a regenerative biological process is ongoing inside the knee at the site of implantation which is expected to result in the

full creation of cartilage-like tissue. Wakitani et al. [42] injected autologous BM-MSCs embedded in the collagen gel directly into the articular cartilage defect of osteoarthritic knee joints. Twelve patients received autologous bone marrow cell transplants, and twelve were cell-free controls. A better arthroscopic and histological score was observed in the cell-transplanted group even though no clinical improvement was demonstrated after 6 months. Another non-randomized study, performed by Nejadnik H. et al. [43], compared 36 patients with autologous chondrocyte implantation (ACI) and 36 patients with autologous BM-MSCs. After 2 years, similar outcomes were obtained for the two procedures but the autologous BM-MSC-based approach was safer and less expensive. This year, Gobbi et al. [14] published a paper with clinical outcome data on the five-year follow up after the same concept of cartilage surgery as we did in this study with a conclusion that cartilage repair using HA-BMAC leads to successful medium-term outcomes independent of age or lesion size. All these studies generally reported the presence of a hyaline-like cartilage repair tissue within the primitive cartilage defects.

Weaknesses in this study are clear- a very short follow-up period and a small size of study sample to yield systematic clinical conclusions. Despite these shortcomings, the consistency, strength, and rapidity of improvement suggest that more extensive and more strongly designed prospective observational studies are warranted and we will continue to perform these procedures at our Department.

Conclusion

Cellular-based therapies for osteoarthritis are rapidly evolving; however, much remains to be understood regarding their efficacy and mechanism of action. Mesenchymal stem cells therapy may be a valid alternative treatment for chronic knee osteoarthritis. The intervention is simple, it does not require hospitalization or surgery, it provides pain relief, and significantly improves cartilage quality.

References

1. Murrell WD, Anz AW, Badsha H, Bennett WF, Boykin RE, Caplan AI. Regenerative treatments to enhance orthopedic surgical outcome. *PM R*. 2015;7(4 Suppl):S41-52.
2. Malanga GA. Regenerative treatments for orthopedic conditions. *PM R*. 2015;7(4 Suppl):S1-3.
3. Jang SJ, Kim JD, Cha SS. Platelet-rich plasma (PRP) injections as an effective treatment for early osteoarthritis. *Eur J Orthop Surg Traumatol*. 2013;23(5):573-80.
4. Gobbi A, Karnatzikos G, Mahajan V, Malchira S. Platelet-rich plasma treatment in symptomatic patients with knee osteoarthritis: preliminary results in a group of active patients. *Sport Health*. 2012;4:162-72.
5. Kon E, Mandelbaum B, Buda R, Filardo G, Delcogliano M, Timoncini A, et al. Platelet-rich plasma intra-articular injection versus hyaluronic acid viscosupplementation as treatments for cartilage pathology: from early degeneration to osteoarthritis. *Arthroscopy*. 2011;27(11):1490-501.
6. Laudy AB, Bakker EW, Rekers M, Moen MH. Efficacy of platelet-rich plasma injections in osteoarthritis of the knee: a systematic review and meta-analysis. *Br J Sports Med*. 2015;49(10):657-72.
8. Mautner K, Blazuk J. Where do injectable stem cell treatments apply in treatment of muscle, tendon, and ligament injuries? *PM R*. 2015;7(4 Suppl):S33-40.
9. Andia I, Maffulli N. Clinical outcomes of biologic treatment for chronic tendinopathy. *Oper Tech Orthop*. 2016;26(2):98-109.
10. Filardo G, Perdisa F, Roffi A, Marcacci M, Kon E. Stem cells in articular cartilage regeneration. *J Orthop Surg Res*. 2016;11:42.
11. Centeno C, Pitts J, Al-Sayegh H, Freeman M. Efficacy of autologous bone marrow concentrate for knee osteoarthritis with and without adipose graft. *Biomed Res Int*. 2014;2014:1-9.
12. Pers YM, Ruiz M, Noël D, Jorgensen C. Mesenchymal stem cells for the management of inflammation in osteoarthritis: State of the art and perspectives. *Osteoarthritis Cartilage*. 2015;23(11):2027-35.
13. Bornes TD, Adesida AB, Jomha NM. Mesenchymal stem cells in the treatment of traumatic articular cartilage defects: a comprehensive review. *Arthritis Res Ther*. 2014;16(5):432.
14. Gobbi A, Whyte GP. One-stage cartilage repair using a hyaluronic acid-based scaffold with activated bone marrow-derived mesenchymal stem cells compared with microfracture five-year follow-up. *Am J Sports Med*. 2016; 44(11):2846-54.
15. Centeno CJ, Al-Sayegh H, Freeman MD, Smith J, Murrell WD, Bubnov R. A multi-center analysis of adverse events among two thousand, three hundred and seventy two adult patients undergoing adult autologous stem cell therapy for orthopaedic conditions. *Int Orthop*. 2016;40(8):1755-65.
16. Sladojevic I, Krivokuca Z, Gajanin V, Manojlovic S. Expression of collagen type I in unaltered and osteoarthritic menisci of knee joint. *Med Pregl*. 2016;69(1-2):16-23.
17. Nikolić G, Đorđević B. Clinical manifestations of osteoarthritis of the knee joints. *Praxis medica*. 2014;43(1):13-8.
18. Sampson S, Botto-van Bemden A, Aufiero D. Stem cell therapies for treatment of cartilage and bone disorders: osteoarthritis, avascular necrosis, and non-union fractures. *PM R*. 2015;7(4):526-32.
19. Goldring MB. The role of the chondrocyte in osteoarthritis. *Arthritis Rheum*. 2000;43(9):1916-26.
20. Goldring MB. Chondrogenesis, chondrocyte differentiation, and articular cartilage metabolism in health and osteoarthritis. *Ther Adv Musculoskelet Dis*. 2012;4(4):269-85.
21. Centeno CJ, Schultz JR, Cheever M, Robinson B, Freeman M, Marasco W. Safety and complications reporting on the re-implantation of culture-expanded mesenchymal stem cells using autologous platelet lysate technique. *Curr Stem Cell Res Ther*. 2010;5(1):81-93.
22. Marković M, Tomić S, Đokić J, Čolić M. Mesenchymal stem cells from periapical lesions upregulate the production of immunoregulatory cytokines by inflammatory cells in culture. *Acta Fac Med Naiss*. 2015;32(3):171-9.
23. Kraus VB, Feng S, Wang S, White S, Ainslie M, Graverand MH Le, et al. Subchondral bone trabecular integrity predicts and changes concurrently with radiographic and magnetic resonance imaging-determined knee osteoarthritis progression. *Arthritis Rheum*. 2013;65(7):1812-21.
24. Connolly JF. Injectable bone marrow preparations to stimulate osteogenic repair. *Clin Orthop Relat Res*. 1995;313:8-18.
25. Connolly JF, Guse R, Tiedeman J, Dehne R. Autologous marrow injection as a substitute for operative grafting of tibial nonunions. *Clin Orthop Relat Res*. 1991;266:259-70.
26. Kitaori T, Ito H, Schwarz EM, Tsutsumi R, Yoshitomi H, Oishi S, et al. Stromal cell-derived factor 1/CXCR4 signaling is critical for the recruitment of mesenchymal stem cells to the fracture site during skeletal repair in a mouse model. *Arthritis Rheum*. 2009;60(3):813-23.
27. Masaki H, Ide H. Regeneration potency of mouse limbs. *Dev Growth Differ*. 2007;49(2):89-98.
28. Murphy MB, Moncivais K, Caplan AI. Mesenchymal stem cells: environmentally responsive therapeutics for regenerative medicine. *Exp Mol Med*. 2013;45(11):e54.
29. Caplan AI, Correa D. The MSC: an injury drugstore. *Cell Stem Cell*. 2011;9(1):11-5.
30. Prockop DJ. Marrow stromal cells as stem cells for non-hematopoietic tissues. *Science*. 1997;276(5309):71-4.
31. Bruder SP, Fink DJ, Caplan AI. Mesenchymal stem cells in bone development, bone repair, and skeletal regeneration therapy. *J Cell Biochem*. 1994;56(3):283-94.
32. Lewandowski K, Kowalik MM, Pawlaczyk R, Rogowski J, Hellmann A. Microscopic examination of bone marrow aspirate in healthy adults: comparison of two techniques of slide preparation. *Int J Lab Hematol*. 2012;34(3):254-61.
33. Caplan AI. Review: mesenchymal stem cells: cell-based reconstructive therapy in orthopedics. *Tissue Eng*. 2005;11(7-8):1198-211.
34. Oliver KS, Bayes M, Crane D, Pathikonda C. Clinical outcome of bone marrow concentrate in knee osteoarthritis. *J Prolotherapy*. 2015;7:937-46.
35. Filardo G, Madry H, Jelic M, Roffi A, Cucchiari M, Kon E. Mesenchymal stem cells for the treatment of cartilage lesions: from preclinical findings to clinical application in orthopaedics. *Knee Surg Sports Traumatol Arthrosc*. 2013;21(8):1717-29.
36. Shapiro SA, Kazmerchak SE, Heckman MG, Zubair AC, O'Connor MI. A prospective, single-blind, placebo-controlled trial of bone marrow aspirate concentrate for knee osteo-

oarthritis. *Am J Sports Med.* 2016; Aug 26. [Epub ahead of print].

37. Jo CH, Lee YG, Shin WH, Kim H, Chai JW, Jeong EC, et al. Intraarticular injection of mesenchymal stem cells for the treatment of osteoarthritis of the knee: a proof-of-concept clinical trial. *Stem Cells.* 2014;32(5):1254–66.

38. Chu CR. The challenge and the promise of bone marrow cells for human cartilage repair. *Cartilage.* 2015;6(2 suppl):36S–45S.

39. Veronesi F, Giavaresi G, Tschon M, Borsari V, Nicoli Aldini N, et al. Clinical use of bone marrow, bone marrow concentrate, and expanded bone marrow mesenchymal stem cells in cartilage disease. *Stem Cells Dev.* 2012;22(2):181–92.

40. Kuroda K, Kabata T, Hayashi K, Maeda T, Kajino Y, Iwai S, et al. The paracrine effect of adipose-derived stem cells

Rad je primljen 2. 11. 2016.

Recenziran 10. 12. 2016.

Prihvaćen za štampu 16. 12. 2016.

BIBLID.0025-8105:(2016):LXIX:Suppl 1:77-84.

inhibits osteoarthritis progression. *BMC Musculoskelet Disord.* 2015;16(1):236.

41. Ham O, Lee CY, Kim R, Lee J, Oh S, Lee MY, et al. Therapeutic potential of differentiated mesenchymal stem cells for treatment of osteoarthritis. *Int J Mol Sci.* 2015;16(7):14961–78.

42. Wakitani S, Imoto K, Yamamoto T, Saito M, Murata N, Yoneda M. Human autologous culture expanded bone marrow mesenchymal cell transplantation for repair of cartilage defects in osteoarthritic knees. *Osteoarthritis Cartilage.* 2016;10(3):199–206.

43. Nejadnik H, Hui JH, Choong EPF, Tai BC, Lee EH. Autologous bone marrow-derived mesenchymal stem cells versus autologous chondrocyte implantation an observational cohort study. *Am J Sports Med.* 2010;38(6):1110-6.

Clinical Center of Vojvodina, Novi Sad
Department of Orthopedic Surgery and Traumatology¹
University of Novi Sad, Faculty of Medicine²

UDK 616.71-007.234:613.25
DOI: 10.2298/MPNS16S1085M

RELATIONSHIP BETWEEN BODY MASS INDEX AND OSTEOPOROSIS

ODNOS IZMEĐU INDEKSA TELESNE MASE I OSTEOPOROZE

Radmila MATIJEVIĆ^{1,2}, Vladimir HARHAJI^{1,2}, Srđan NINKOVIĆ^{1,2}, Zoran GOJKOVIĆ^{1,2},
Predrag RAŠOVIĆ^{1,2}, Veselin BOJAT² and Ivica LALIĆ^{1,2}

Summary

Introduction. Osteoporosis is a metabolic skeletal disease characterized by bone mineral density reduction, which may lead to an increased risk of bone fractures. Obesity is a condition of excessive body fat that causes or aggravates many public health problems. As it is easy to be measured, body mass index is widely used as an index of the degree of obesity. **Material and Methods.** The study included 1.372 female orthopedic patients between the ages of 30 to 79 years who visited the Clinical Centre of Vojvodina in Novi Sad to have a dual-energy x-ray absorptiometry (DEXA) examination in the period from March, 2010 to June, 2013. The following anthropometric data were collected: body mass index, body weight, height, dual-energy x-ray absorptiometry T-score and bone mineral density (BMD), as well as some other data. **Results.** The mean age was 62.08 years, the mean weight was 73.59 kg and the mean height was 1.6 m. There were 392 participants in the group of normal body mass index, 14 participants were underweight, and 966 were overweight and obese. In the overweight and obese group, 25.25% participants had osteoporosis, 35.4% had osteopenia and 39.33% had the normal T-score. In the normal body mass index group, 42.34% of the participants had osteoporosis, 29.3% had osteopenia and 28.31 had the normal T-score. In the underweight group, 57.14% of the participants had osteoporosis, 21.42% had osteopenia and 21.42% had the normal T-score. **Conclusion.** No strong correlation between body mass index and bone mineral density was found in our study, but it is obvious that there was a stronger correlation between body mass index and bone mineral density of the total hip than between body mass index and bone mineral density of the lumbar spine.

Key words: Body Mass Index; Osteoporosis; Fractures, Bone; Obesity; Bone Density; Absorptiometry, Photon; Bone Diseases, Metabolic

Introduction

Osteoporosis is a metabolic skeletal disease characterized by bone mineral density reduction (BMD), which may lead to an increased risk of bone fractures. Accelerated bone loss can be detected in premenopausal patients, in subjects with different diseases such as primary hyperparathyroidism, Cushing's syndrome, and thyrotoxicosis but it is generally reflected as a disorder in postmenopausal women. With the aging of the world's population,

Sažetak

Uvod. Osteoporoza je metabolička bolest za koju je karakteristično smanjenje koštane gustine što može da dovede do povećanog rizika za nastanak koštanih preloma. Gojaznost je stanje koje se ispoljava povećanim nakupljanjem masti i povećanjem telesne težine. Zahvaljujući lakoći merenja, indeks telesne mase široko rasprostranjenu primenu kao indeks stepena gojaznosti. **Materijal i metode.** U studiji je učestvovalo 1 372 žene, starosti 30–79 godina, pacijenti Klinike za ortopedsku hirurgiju Kliničkog centra Vojvodine, kojima je urađen pregled *dual-energy x-ray absorptiometry* u periodu od marta 2010. do juna 2013. godine. Pored ovog pregleda, uzeti su podaci o visini, težini, indeks telesne mase, kao i prisustvu različitih faktora rizika. **Rezultati.** Prosečna starost ispitanika bila je 62,08 godina, visina 1,6 m, težina 73,59 kilograma. U grupi sa normalnim indeksom telesne mase bilo je 392 ispitanika, u grupi sa povišenim indeksom telesne mase 966, a sa sniženim samo 14. U grupi gojaznih, 25,25% ispitanika imalo je osteoporozu, 35,4% osteopeniju a 39,33% imalo je normalan *T-skor*. U grupi sa normalnim indeksom telesne mase, 42,34% ispitanika imalo je osteoporozu, 29,3% osteopeniju a 28,31% imalo je normalan *T-skor*. U grupi sa sniženim indeksom telesne mase 57,14% ispitanika imalo je osteoporozu, 21,42% osteopeniju a 21,42% imalo je normalan *T-skor*. **Zaključak.** U ovoj grupi ispitanika nismo uspjeli da dobijemo jaku korelaciju između indeksa telesne mase i *bone mineral density*, ali je uočljiv trend da je korelacija indeksa telesne mase i *bone mineral density* kuka jača nego indeksa telesne mase i *bone mineral density* lumbalnih pršljenova.

Cljučne reči: indeks telesne mase; osteoporoza; prelomi kosti; gojaznost; mineralna gustina kosti; DEXA; osteopenija

the occurrence of osteoporosis and its consequential fragility fractures is bound to increase significantly. Fragility fracture is defined by the World Health Organization as "a fracture caused by injury that would be insufficient to fracture a normal bone... the result of reduced compressive and/or torsional strength of bone" [1–3]. Osteoporosis can be diagnosed based on low bone density as measured by osteodensitometry which is based on dual-energy x-ray absorptiometry (DEXA). Low bone mass (osteopenia) is defined as a T-score between –1.0 and

Abbreviations

BMI	– body mass index
DEXA	– dual-energy x-ray absorptiometry
BMD	– bone mineral density
CDC	– Centre for Disease Control
SD	– standard deviation
WHO	– World Health Organization

–2.49 by DEXA findings. Osteodensitometry T-score of –2.5 or lower (determined by the lowest calculation from the lumbar spine, femoral neck, or total femur T-score) is a diagnostic threshold for osteoporosis. A fragility fracture, fracture sustained on weak force, regardless of DEXA results, entails the diagnosis of osteoporosis. Worldwide, osteoporosis causes more than 8.9 million fractures annually, resulting in an osteoporotic fracture every 3 seconds and 1 out of 3 women over the age of 50 years will experience osteoporotic fractures, as will 1 out of 5 men over the age of 50 years [4]. Such fractures frequently result in chronic pain, disfigurement, height loss, impairment in activities of daily living, loss of independence, and lower quality of life. The 1-year mortality rate for patients following a hip fracture is estimated to be 14–36% [4, 5]. Women with a vertebral fracture have a 1.2-fold greater age-adjusted mortality rate compared with women without fractures [5]. A 2005 estimate calculated \$19 billion annually as the direct cost of fragility fractures [6].

Obesity is a condition of excessive body fat that causes or aggravates many public health problems. As it is easy to be measured, body mass index (BMI) is widely used as an index of the degree of obesity. Although several studies have investigated the association between body mass index (BMI) and bone mineral density (BMD), the results are inconsistent.

Material and Methods

The study included female orthopedic patients who visited the Clinical Centre of Vojvodina in Novi Sad to have a DEXA examination in the period from March, 2010 to June, 2013. The following anthropometric data were collected: BMI, body weight, height, DEXA T-score and BMD, as well as other data such as hypertension, diabetes, thyroid malfunction, walking, smoking and drinking habits,

dairy products consumption, prescribed drugs use, menopause onset, history of fracture and family history of fracture. Men were excluded from the study due to an unrepresentative number in the examined population.

While having their height and weight measured, the participants were dressed in light clothes and did not wear shoes. The BMI was calculated based on the formula weight (kg)/height (m)². According to the standard categorization of BMI by CDC [16] less than 18.5 is taken as underweight, 18.5–24.9 as normal, 25.0–29.9 as overweight, and 30.0 and above as obese. Dual-energy X-ray absorptiometry scans were performed and analyzed in line with the manufacturer's recommendations. Lumbar spine T-scores (number of standard deviations (SD) above or below young adult mean BMD) and Z-scores (number of SDs above or below age-matched mean BMD) were calculated using the manufacturer's USA white female reference values. According to the WHO classification T-score of –2.5 or lower was considered to be osteoporotic, between –2.5 and –1 was osteopenia, and above –1 was a normal finding.

Results

The study sample consisted of 1,372 women between the ages 30 and 79 years, their mean age being 62.08 years. The mean weight and the height of the study participants was 73.59 kg and 1.6 m, respectively. The study participants were divided by standard categorization of BMI set by the Centre for Disease Control (CDC) [16] into the group of normal BMI (392 participants), underweight (14 participants), and overweight and obese (966 participants) (**Table 1**).

In the overweight and obese group, 25.25% of the participants had osteoporosis, 35.4% had osteopenia and 39.33% had the normal T-score. In the normal BMI group, 42.34% of the participants had osteoporosis, 29.3% had osteopenia and 28.31% had the normal T-score. In the underweight group, 57.14% of the participants had osteoporosis, 21.42% had osteopenia and 21.42% had the normal T-score.

Discussion

Fat and bone are linked by many pathways providing a skeleton appropriate to the mass of adipose

Table 1. BMI and T score in all groups of participants
Tabela 1. BMI i T-skor u svim grupama pacijenata

	Underweight/ <i>Pothranjeni</i> (BMI < 18.5)	Normal/ <i>Idealna</i> masa (BMI 18.5–24.9)	Overweight and obese/ <i>Gojazni</i> (BMI > 25.9)	
Osteoporosis/ <i>Osteoporoz</i>	8	166	244	418
Osteopenia/ <i>Osteopenija</i>	3	115	342	460
Normal finding <i>Normalan nalaz</i>	3	111	380	494
	14	392	966	1372

Table 2. Correlation between BMI and BMD of the lumbar spine and the hip in all groups of participants
Tabela 2. BMI/BMD za lumbarne pršljenove i kuk u svim grupama pacijenata

	Underweight <i>Pothranjeni</i> (BMI < 18.5)	Normal <i>Idealna masa</i> (BMI 18.5–24.9)	Overweight and obese <i>Gojazni</i> (BMI > 25.9)
Correlation between BMI and BMD of lumbar spine <i>Korelacija BMI/BMD za lumbalnu kičmu</i>	0.14532	0.083473	0.041486
Correlation between BMI and BMD of hip <i>Korelacija BMI/BMD za kuk</i>	0.31266	0.258	0.163965

BMI - indeks telesne mase, BMD - mineralna gustina kosti

tissue it is carrying. Leptin, adiponectin, adipocyte estrogens and insulin/amylin are involved in this connection. However, excessive body fat, and particularly abdominal fat, causes production of inflammatory cytokines which may consequently stimulate bone resorption, resulting in reduction of bone strength.

Traditionally, body weight is positively associated with BMD, from childhood through adulthood (with correlations to the order of 0.3 to 0.6) and obesity is believed to be protective against fragility fracture; many earlier studies support this view [7–10]. For example, hip fracture risk in women was increased by 7.4% for each unit decrease in body mass index (BMI) [8]. Our findings in those 1,372 cases correspond with this result since there is the lowest percentage of patients with osteoporosis in the overweight and obese group in comparison with the patients with normal BMI and underweight.

Body weight is usually considered a strong predictor of bone mass in both men and women. In fact, large-scale epidemiological studies have shown that increased body weight, or body mass index, is positively correlated with higher bone mineral density and with lowered risk of fragility fractures. The most prevalent explanation of this correlation is that a larger body mass causes greater mechanical loading on bone, which consequently increases BMD to accommodate the greater load [17]. In our group of participants we could not get a strong correlation between BMI and BMD, but it is obvious that there is a stronger correlation between BMI and BMD of the total hip than between BMI and BMD of the lumbar spine.

Contrary to this, more recent findings suggest that obesity may not be beneficial to bone health. Some studies have even shown that a higher body mass poses a significant risk factor for fragility fracture, especially for those occurring at sites other than hip [11–14]. Obviously, most of the findings supporting a detrimental effect of body mass on fracture risk were deduced from bone mineral density (BMD) adjusted data. Individuals with higher BMI had greater risk of fracture than those with low BMI as shown in these studies after BMD effect had been controlled [11, 14, 16]. For instance, in a prospective study on elderly women, a greater risk of hip fracture before adjustment for BMD was associated with lower BMI, but the association was reversed after including BMD in the statistical model [16]. Similarly this adjustment needs to be done with the data obtained by our study which included an even bigger group of participants (approximately 3.000 over a period of 6 years during which DEXA was performed for our orthopedic patients).

Conclusion

No strong correlation between body mass index and bone mineral density was found in our study, but it is obvious that there was a stronger correlation between body mass index and bone mineral density of the total hip than between body mass index and bone mineral density of the lumbar spine.

References

1. Johnell O, Kanis JA, Oden A, Johansson H, De Laet C, et al. Predictive value of BMD for hip and other fractures. *J Bone Miner Res.* 2005;20:1185-94.
2. Marshall D, Johnell O, Wedel H. Meta-analysis of how well measures of bone mineral density predict occurrence of osteoporotic fractures. *BMJ.* 1996;312:1254-9.
3. World Health Organization. Prevention and management of osteoporosis. Geneva: WHO; 2003.
4. Johnell O, Kanis JA. An estimate of the worldwide prevalence and disability associated with osteoporotic fractures. *Osteoporos Int.* 2006;17:1726-33.
5. Miyamoto RG, Kaplan KM, Levine BR, Egol KA, Zuckerman JD. Surgical management of hip fractures: an evidence-based review of the literature. I: femoral neck fractures. *J Am Acad Orthop Surg.* 2008;16(10):596-607.
6. Kado DM, Browner WS, Palmero L, Nevitt MC, Genant HK, Cummings SR. Vertebral fractures and mortality in older women: a prospective study. Study of osteoporotic fractures research group. *Arch Intern Med.* 1999;159(11):1215-20.
7. Reid IR. Relationships among body mass, its components and bone. *Bone.* 2002;31:547-55.
8. Johnell O, Gullberg B, Kanis JA, et al. Risk factors for hip fracture in European women: the MEDOS study. *J Bone Miner Res.* 1995;10(11):1802-15.
9. Joakimsen RM, Fonnebo V, Magnus JH, Tollan A, Sogaard AJ. The Tromso Study: body height, body mass index and fractures. *Osteoporos Int.* 1998;8:436-42.

10. Kanis JA, Johnell O, Gullberg B, et al. Risk factors for hip fracture in men from Southern Europe: the MEDOS study. *Osteoporos Int.* 1999;9:45-54.

11. Compston JE, Watts NB, Chapurlat R, et al. Obesity is not protective against fracture in postmenopausal women: GLOW. *Am J Med.* 2011;124(11):1043-50.

12. Neilson CM, Marshall LM, Adams AL, et al. BMI and fracture risk in older men: the osteoporotic fractures in men study (MrOS). *J Bone Miner Res.* 2011;26(3):496-502.

13. Piro M, Fabbriani G, Leli C, et al. High weight or body mass index increase the risk of vertebral fractures in postmenopausal osteoporotic women. *J Bone Miner Metab.* 2010;28:88-93.

14. King CM, Hamilton GA, Cobb M, Carpenter D, Ford LA. Association between ankle fractures and obesity. *J Foot Ankle Surg.* 2012;51(5):543-7.

Rad je primljen 2. 11. 2016.

Recenziran 10. 12. 2016.

Prihvaćen za štampu 16. 12. 2016.

BIBLID.0025-8105:(2016):LXIX:Suppl 1:85-88.

15. Ensrud KE, Lipschutz RC, Cauley JA, et al. Body size and hip fracture risk in older women: a prospective study. *Am J Med.* 1997;103(4):274-80.

16. Centers for Disease Control and Prevention [Internet]. Credible health information, 2009. Available from: http://www.cdc.gov/healthyweight/assessing/bmi/adult_BMI/index.html.

17. De Laet C, Kanis JA, Odén A, Johanson H, Johnell O, Delmas P, et al. Body mass index as a predictor of fracture risk: a meta-analysis. *Osteoporos Int.* 2005;16:1330-8.

18. Felson DT, Zhang Y, Hannan MT, Anderson JJ. Effects of weight and body mass index on bone mineral density in men and women: the Framingham study. *J Bone Miner Res.* 1993;8:567-73.

PRODUCTION OF MEDICAL PRODUCTS FOR THE PURPOSES IN ORTHOPEDICS AND TRAUMATOLOGY IN NOVI SAD

PROIZVODNJA MEDICINSKIH SREDSTAVA ZA POTREBE ORTOPEDIJE I TRAUMATOLOGIJE U NOVOM SADU

Jovan GRUJIĆ and Milica GRUJIĆ

Summary

The simplest and most secure way to new knowledge and innovations is possible if scientific and multidisciplinary approach is applied. Treatment of certain phenomena, degenerative changes, injuries or diseases of the bone and joint system of human is possible by applying the implant. In Novi Sad, manufacturing and clinical application of external fixator began in 1985, and the production and application of total cemented endoprosthesis of the hip joint in 1987. With these events Yugoslavia joined the highly developed countries producing implants, which still present a high technology product. Production and application of total cemented knee endoprosthesis began in 1996. The production of implants and instruments for application of screw for anterior cruciate ligament of the knee joint began in 1998, and the production and application of anchors for ligamentoplasty of shoulder began in 2004.

Key words: External Fixators; Prostheses and Implants; Hip Joint; Knee Joint; Arthroplasty Replacement; Bone Screws

Sažetak

Najjednostavniji i najsigurniji put do novih saznanja i napretka moguć je ako se primeni multidisciplinarni naučni pristup. Rešavanje određenih pojava, degenerativne promene, povrede ili oboljenja koštano-zglobnog sistema čoveka moguće je primenom implantata. U Novom Sadu, proizvodnja i klinička primena spoljašnjih fiksatora počela je 1985. godine, a proizvodnja i ugradnja totalne cementne endoproteze zglobova kuka 1987. godine. Time se Jugoslavija pridružila visokorazvijenim zemljama sa proizvodnjom implantata, koji i danas predstavljaju proizvodnju visoke tehnologije. Proizvodnja i ugradnja totalne cementne endoproteze kolena počela je 1996. godine. Godine 1998. počinje proizvodnja implantata i kompletnog instrumentarijuma za ugradnju vijaka za ligamentoplastiku zglobova kolena, dok proizvodnja i ugradnja anкера za ligamentoplastiku ramena počinje tek 2004. godine.

Glavne reči: spoljašnji fiksatori; proteze i implantati; zglob kuka; zglob kolena; artroplastika; vijci

Introduction

Since the development of medical thought there has been a tendency not only to preserve the general health but also to improve human function of movement in order to achieve security, functionality, speed, esthetics, economy because moving means to live.

In case of the development of pathological changes which make movement difficult or impossible, the

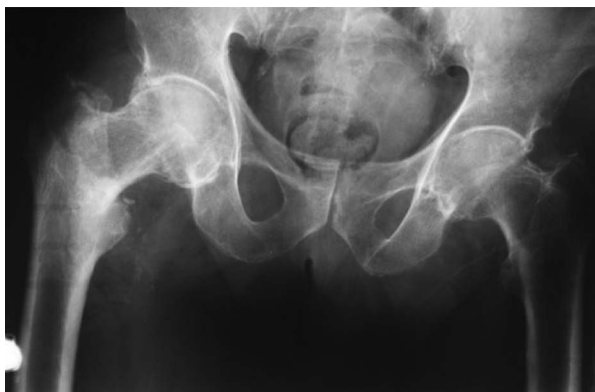

Figure 1. X-ray of the pelvis and hip joints
Slika 1. Rendgenski snimak karlice i zglobova kuka

application of appropriate methods of rehabilitation, surgical methods or transplants, implants or prosthetic system makes it possible to re-establish normal functioning of the musculoskeletal system of a human body and thus enable movement. We have to know and believe that normal functioning of the musculoskeletal system can be reconstructed and reestablished by the application of appropriate measures and resources that are available, as well as by developing new ones. The hip joint is certainly one of the most important joints of the locomotor system as it allows ambulation, especially upright walk, which is one of the important characteristics that distinguish the human population from the rest of vertebrates.

Of all the joints in the body, the hip joint is most commonly affected by degenerative changes, injuries or illness, thus it undergoes the most numerous, most likely, and most successful surgical procedures in the world (**Figure 1**).

“Carry each other’s burdens, and so fulfill the law of Christ.” Galatians 6:2; Paul the Epistle to the Galatians, the Gospel of Christian Freedom and Obedient Holy Love and Charity.

Modern medicine faces increasing demands for re-establishment of the function of human organs

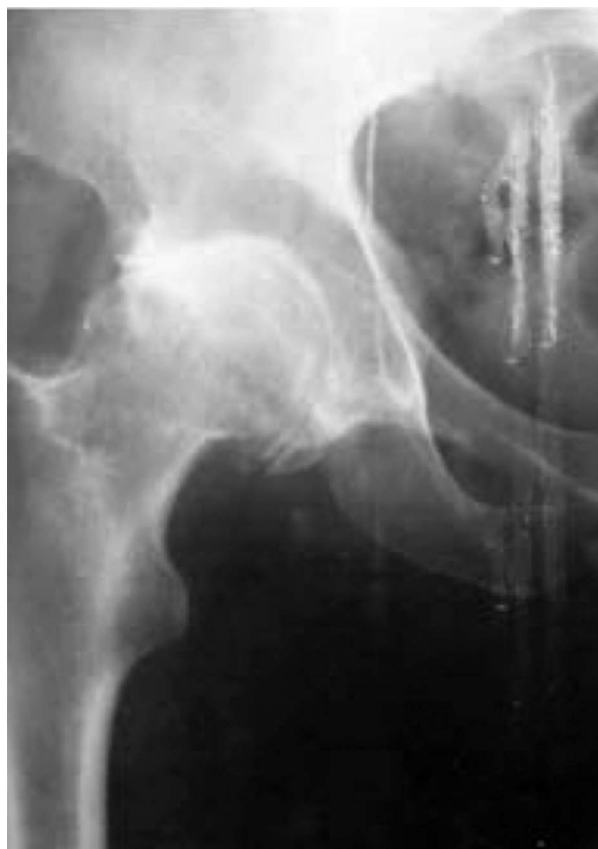

Figure 2 a. Degenerative changes of hip joint
Slika 2 a. Degenerativne promene zgloba kuka

that have been damaged by degenerative changes (**Figure 2 a**), diseases (**Figure 2 b**), or injuries (**Figure 2 c**). A complication on the skeletal system can be managed by applying implants, which presents a gold standard.

The application of the implant and prosthetic components fulfills an old medical aspiration to replace a damaged part of the human body both functionally and esthetically. Modern computer software allows modeling of implants and prosthetic components, performing calculations and verifications, preparation of codes and simulation of its functionality for production with computer-controlled machines. This software is known as CAD/CAM systems [1].

All this serves to enable normal life and work of the users of implants and prosthetic elements.

According to modern research [2] a half million hip replacements are done in 15 developed countries of Western Europe per year, which is statistically 131 surgeries per 100,000 people. If that could be converted for Serbia for approximately 6,000,000 residents, the expected number of surgically installed hip endoprostheses would be $60 \times 131 = 7860$. The reason for this upward trend of total number of implanted hip endoprostheses, as a result of improved communication between surgeon and patient, can be found in the following:

- Improved diagnostics

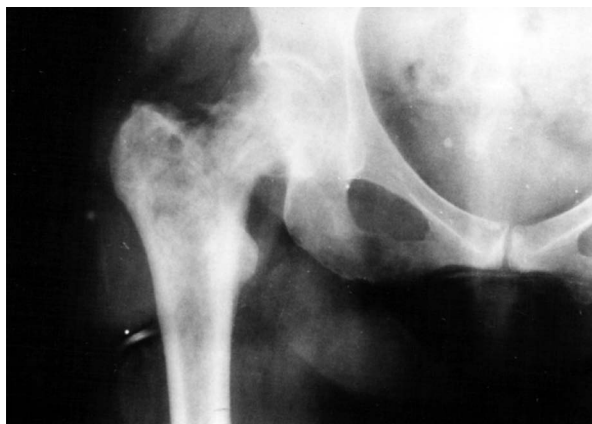

Figure 2 b. Proximal femur tumor
Slika 2 b. Maligno oboljenje proksimalnog dela butne kosti

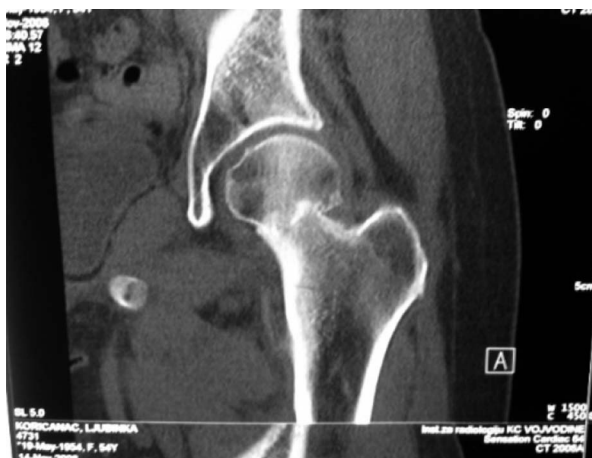

Figure 2 c. Injury, femoral neck bone dislocation
Slika 2 c. Povreda, prelom vrata butne kosti

- Improved surgical conditions
- Improved surgical technique
- Improved training of surgeons-orthopedists
- Increased number of surgeon-orthopedist
- Extended life expectancy and the elderly must receive appropriate medical care

In Novi Sad, in the period from 1987 to 2005 year, 3,850 hip endoprostheses (total cemented endoprostheses) were produced, which were surgically installed in the Socialist Federal Republic of Yugoslavia (SFRJ) and Federal Republic of Yugoslavia (SRJ) [3].

Material and Methods

The idea to produce medical equipment, especially hip joint endoprosthesis, which was then called an artificial hip or hip prosthesis or prosthesis of the hip, was promoted by Dr Branko Secerov, an orthopedist, at the beginning of the 1980s. He first worked at the Department of Orthopedics and Traumatology, Novi Sad and then moved to Germany in the mid-seventies, where he successfully performed orthopedic trauma surgeries. With the help of German company "Mec-



Figure 3. Uroš Mandić, Director
Slika 3. Uroš Mandić, Direktor

kron”, he designed a cemented hip joint endoprosthesis with centralizer. He easily convinced the former general director of “DES” company, Novi Sad, Uros Mandic, BSc in Economics (**Figure 3**) to start producing implants for purposes of dentistry, traumatology and orthopedics in Novi Sad.

The development and organization of production of the hip endoprosthesis was initiated in 1982. It took the leading position in the mid-term plans for period 1986-1990 of the company “DES”, Novi Sad, on the basis of the decision made by the work council No. 10844 on 14.10.1986 [4]. This decision was supported by all departments of “DES”, the Municipality of Novi Sad and Province of Vojvodina. It was accepted by all famous orthopedists who participated in JUOT in Novi Sad in 1986 and most of the clinics and hospitals from all over Yugoslavia. One could say it was a Yugoslavian program since many business entities from all over the country participated in its realization.



Figure 4. Prof. dr Jovan Krajčinović
Slika 4. Prof. Dr. Jovan Krajčinović

External fixator

Having specialized at the Department of Orthopedics and Traumatology in Novi Sad, Prof. Dr. Jovan Krajcinovic (**Figure 4**) went to Paris in 1972 to get sub-specialization with the scholarship granted by the French government. There he noted the importance of surgical treatment in orthopedics. He became aware of the need of multidisciplinary approach in orthopedics, including implant production and its installation. When he became Chief of the Department of Orthopedics and Traumatology 1981-1998, he tried to share his knowledge in Novi Sad. In partnership with Jelena Stankov, PhD, Faculty of Technical Sciences, Novi Sad, he initiated a project on the construction of external fixator according to the “Hoffman” within a graduation thesis to be done at the Institute for Mechanical Engineering. Production of the fixator was offered to the company “Jugodent”, Novi Sad, the manufacturer of medical devices and equipment for dentistry. Unfortunately, they were not interested in this program. Thanks to the initiative of directors of the company “DES”, Uros Mandic and Vladimir Krklec (**Figure 5**), and with the consent of the Chief of the Department of Orthopedics and Traumatology Prof. Dr. Jovan Krajcinovic, an agreement was made between the Institute of Surgery, Faculty of Medicine, Novi Sad and the company “DES”, Novi Sad in 1984. It




Figure 5. Vladimir Krklec, Director of Metalac Company
Slika 5. Vladimir Krklec, direktor JUR Metalac



Figure 6. Jovan Grujić dipl.ing
Slika 6. Jovan Grujić

was based on mutual cooperation on production and clinical testing of medical devices.

Mr. Jovan Grujić, an engineer (**Figure 6**), was in charge of development of technical and technological documentation of production and control of medical devices for the company "DES" Novi Sad. During 1984 a complete technological documentation and samples of external fixator were made according to the system "Hoffman". Manufacturing and clinical application began in 1985. In the meantime, the controls of biocompatibility of materials and technologies of the production of implants and needles for the external fixator were provided.

From the material intended for the production of implants, screw-like test tubes were made and embedded into the animal bone (**Figure 7**) at the Department of Experimental Surgery within the Ward for Orthopedics and Traumatology in Sremska Kamenica. This building used to be the Children's Sanatorium for Bone Tuberculosis, and it was founded by Dr. Katherine Macphail Stuart, a Scottish physician, a great friend and benefactor of our people.

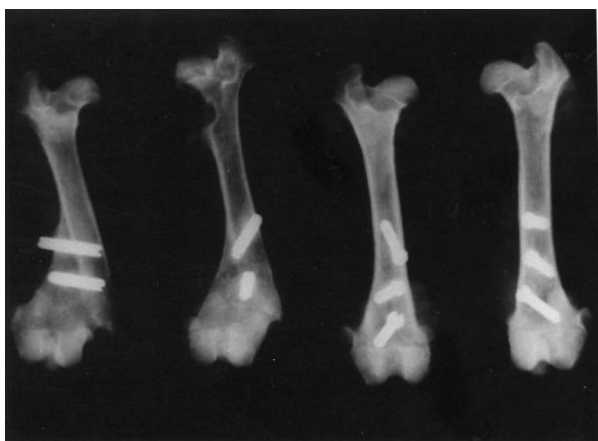


Figure 7. X-ray of tubes embedded into the bone of an animal
Slika 7. Rendgenski snimak ugrađenih epruveta u kost životinje

As a result of war conflicts in former Yugoslavia and the influx of refugees, this building was converted into a collective accommodation for the reception of refugees in 1993. Since then it has not been in use for the needs of orthopedics and traumatology and experimental surgery.

After three to four months the animals were sacrificed. The necessary pathological-histological analysis of the surrounding bone and soft tissue was made at the Department of Pathology and the Institute for Mechanical Engineering, Faculty of Technical Sciences, Novi Sad. Research of metallic material incorporated into the animal bone was conducted to identify any possible changes. Thanks to the positive results, the Institute for Surgery prepared a "report on testing physical and biological effects of metallic material implanted into the animal bone."

As a result of this research Prof. Dr. Jovan Krajinović, Faculty of Medicine Novi Sad and Mr. Jovan Grujić, from the company "DES", Novi Sad did a study about production of external fixator.

On the basis of this study, Prof. Dr. Jovan Krajinović, wrote the first book "External Fixation" in Serbian language.

The hip endoprosthesis

TYPE: KPD 1

Production of external fixator per the "Hoffman" system took place according to the desired schedule. Prof. Dr. Jovan Krajinović proposed and developed the design for total cemented endoprosthesis of the hip joint (**Figure 8 a**). Mr. Jovan Grujić made the structure (**Figure 8 b**) and prepared technology for production of total cemented hip arthroplasty called KPD1 (hip prosthesis "DES" model I). Casting in vacuum from super alloy CoCrMo was done in LPO Ada. Final processing of stem (body) of endoprosthesis, head and acetabular cup, as well as final verification and packaging were done by the company "DES", Novi Sad. The production of the

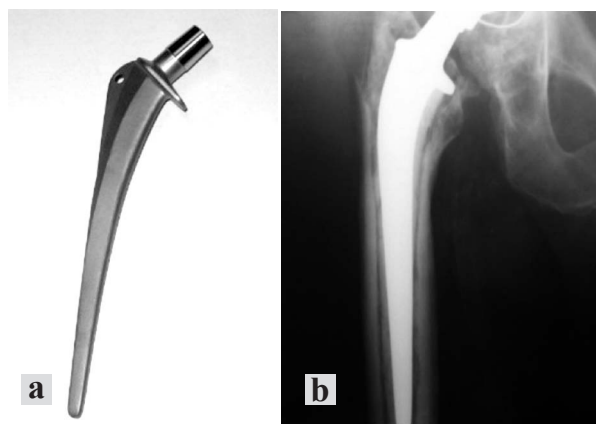


Figure 8 a) Model FBL1 endoprosthesis, **b)** installed endoprosthesis KPD1
Slika 8. a) Model KPD1 endoproteza, b) ugrađena endoproteza KPD1



Figure 9 a. Partial endoprosthesis "Austin Moore," produced by "DES"

Slika 9 a. Parcijalna endoproteza "Ostin Mur" proizvedena u DES-u

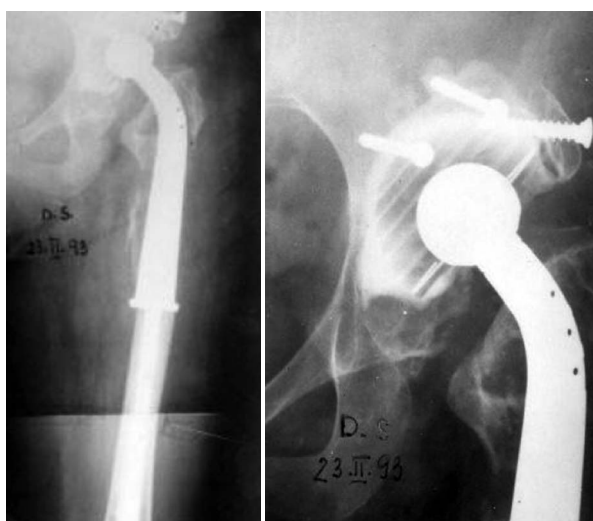

Figure 9 b. Tumor endoprosthesis, type "Custom Made", produced in Novi Sad from 1989 to 1993 year.

Slika 9 b. Tumorska endoproteza Custom Made koja se proizvodila u Novom Sadu 1989–1993 god.

total cemented endoprosthesis of the hip joint was carried out during 1986 and 1987 followed by appropriate marketing promotions. In September 1987, since the assessment had positive verification, the first cemented total hip endoprosthesis produced in Novi Sad was installed in human body. Implantation was done by Prof. Dr. Jovan Krajinovic, at the Department of Orthopedics and Traumatology. Few days after the installation in Novi Sad, Prof. Dr. Zika Jovanovic installed the second cemented total hip endoprosthesis type KPD1 at the Military Medical Academy in Belgrade. Soon after, all clinics and hospitals in Yugoslavia began to install the total cemented hip endoprosthesis KPD 1 of domestic production. In order to promote marketing a film, whose synopsis was written by Grujic Jovan, was made about the production of total cemented endoprostheses. The film, directed by Prvoslav Maric, Radio Television of Vojvodina Novi Sad, was broadcast by Yugoslav Radio Television (JRT) on three occasions after the national news "Dnevnik" on Sunday. Several more models of total hip joint endoprosthesis were developed in cooperation with Prof. Dr. Jovan

Krajinovic, as well as partial "Austin Moore" endoprosthesis (**Figure 9 a**) which were successfully produced and incorporated all over SFRJ.

"Custom made" type endoprosthesis

Application of resection tumor endoprosthesis in reconstructive surgery after removal (extractions) of bone tumors, made according to "Custom Made" or modular "Ready Made" types, is a safe procedure and the "gold standard". In 1989 Prof. Dr. Jovan Krajinovic, designed a tumor endoprosthesis type "Custom Made" (**Figure 9 b**). Four endoprostheses of this type were produced that year and installed by Dr. Mika Tubic, MD and Prof. Dr. Jovan Krajinovic. One prosthesis was a revision due to loss of bone density of proximal part of the femur as a complication of previously installed endoprosthesis of the hip joint.

The knee joint endoprosthesis

Production of total cemented knee joint endoprosthesis began in 1995 within the cooperation between the Department of Orthopedics and Traumatology, Novi Sad especially Prof. Dr. Goran Ercegan, and Dr. Aleksandar Lazetic, and the company "Grujic & Grujic". Tools for precise casting of endoprosthesis of the knee joint were made in two sizes: 58 and 64. Precise vacuum casting was done in "LPO" Ada and the final processing and production of insole and patella made of polyethylene took place in the company "Grujic & Grujic", Novi Sad. The production program also included the revision knee joint endoprosthesis with extended stem for femoral and tibia component (**Figure 10**). Most of the knee joint endoprostheses produced in Novi Sad were installed by Prof. Dr. Goran Ercegan. About 40 knee joint endoprostheses were produced and installed in the period from 1995 to 2005.

Implants for ligament

Screws for ligamentoplasty of the knee joint

Design, construction and production of screw for ligamentoplasty for the knee joint were performed in

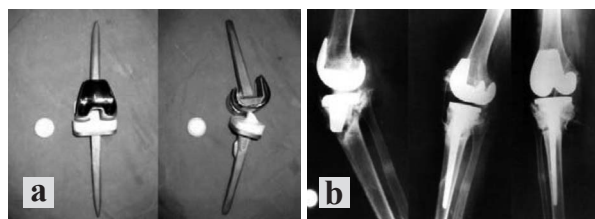

Figure 10. Revision knee endoprosthesis with extended stem **a)** implant, **b)** indication and installed endoprosthesis of the knee joint

Slika 10. Revizionna endoproteza kolena sa produzenim stemom: a) implantat, b) indicacija i ugradena endoproteza zgloba kolena




Figure 11. Screw for ligamentoplasty **a)** with rounded tops, **b)** with sharp peaks

Slika 11. Vijak za ligamentoplastiku: **a)** sa zaobljenim vrhovima, **b)** sa oštrim vrhovima

the company “Grujić & Grujić” Novi Sad during 1998 in cooperation with the Department of Orthopedics and Traumatology in Novi Sad, at the request of Prof Dr Miroslav Milankov. It was intended for anterior cruciate ligament injuries. The first model was made according to the type “Kurosaki” with sharp peaks of the thread (**Figure 11**), with a specific screw profile in shape of olive for easier and more reliable application of bone-tendon-bone method during installation. The design was modified and the screw with rounded tops was made in order to increase reliability and decrease complications during installation. All instruments necessary for installation were produced, for both open and arthroscopic method of installation. Several instruments and devices were innovative and they were registered in Patent Office. In the period from 1998 to 2016 around 500 ligamentoplasties were done and around 7000 ligament screws were installed in Novi Sad. The material used for the production was of stainless steel 316LVM and titanium Ti6Al4V “ELI”.

Screws for ligamentoplasty of the shoulder joint

Production of screws for ligamentoplasty of shoulder joint and instruments for their arthroscopic installation began in 1999 as the business and technical cooperation between IOHB “Banjica” (Dr Ivan Diklic was in charge) and the company “Grujić & Grujić” Novi Sad. Production of screws for ligamentoplasty of the shoulder joint and complete instruments for open and arthroscopic installation began to increase in 2005 when Dr Srdjan Ninkovic from the Department of Orthopedics and Traumatology Novi Sad opted for sub-specialization in diagnosis and surgical treatment of shoulder.

Results

As the consequences of the war that led to disintegration of Yugoslavia in the early 1990s, and especially in the presence of uncontrollable high inflation which resulted in high prices of imported materials and low-cost finished products, the company “DES” had to discontinue production of medical materials and implants thus ending the idea of directors Uros Mandic and Prof. Dr. Jovan Krajcinovic and the whole team that the company “DES” should become a major production system of medical materials, especially of endoprosthesis. The company “DES” ceased the production in 1993, in the time of economic sanctions in Yugoslavia. A few small companies emerged especially in Serbia and they had more or less successful production of medical devices for the needs of orthopedics and traumatology. Their production was based on the experience gained in the company “DES” Novi Sad and “LPO” Ada, and it might be said that “DES” was the school for manufacturing implants.

Discussion

The external fixator and implants, total cemented hip endoprosthesis, partial hip joint prostheses, total cemented knee joint endoprosthesis, screws for ligamentoplasty of knee and shoulders joints, as well as the instrumentation required for their installation, which were designed at the Department of Orthopedics and Traumatology Novi Sad, and produced by companies “DES” and “Grujić & Grujić” Novi Sad, represent high technology products. Good clinical results, affordable price and expediency of production were not sufficient for its intensification and expansion. Thanks to the cooperation among the Department of Orthopedics and Traumatology, the company “Grujić & Grujić” Novi Sad, and the Faculty of Technical Sciences, Novi Sad several research projects and patent solutions were realized, scientific studies were published and master’s theses were defended (Grujić Jovan, Srdjan Ninkovic, Natasa Janjic), as well as doctoral theses (Natasa Miljkovic, Srdjan Ninkovic, Natasa Janjic, Vladimir Harhaji).

Conclusion

The cooperation among the Department of Orthopedics and Traumatology, Novi Sad, the Faculty of Technical Sciences and companies engaged in the production, i.e. “DES”, Novi Sad and “Grujić & Grujić”, Novi Sad resulted in the realization of the idea of good manufacturing of implants on scientific principles.

References

1. Grujic J, Tabakovic S, Zeljković M, Zivkovic A, Vucinic Z, Djordjevic A, et al. Design of special endoprosthesis "Spacer". Acta Chir Jugosl. 2013;60(2):109-15

2. Zeljkovic M, Tabakovic S, Milojevic Z, Zivkovic A, Navalosic S. Contemporary Approach to Product Development specific purposes. Novi Sad: FTN; 2016.

3. Grujic J. Computer modeling and experimental testing of the hip joint [master's thesis]. Novi Sad: Medical faculty; 2008.

4. Mandic U, Krklec V, Grujic J. Study of technical and economic analysis of production endoprosthesis. Novi Sad: ZRO 'DES'; 1986.

Rad je primljen 2. 11. 2016.

Recenziran 10. 12. 2016.

Prihvaćen za štampu 16. 12. 2016.

BIBLID.0025-8105:(2016):LXIX:Suppl 1:89-95.



Ward D of the Department of Orthopedic Surgery and Traumatology
Odeljenje Poliklinike Klinike za ortopedsku hirurgiju i traumatologiju

CONTRIBUTION FROM HISTORY OF MEDICINE

PRILOG IZ ISTORIJE MEDICINE

Short History of Development of Orthopedic Surgery and Traumatology in Novi Sad, written by Dr. Đorđe Gusman, is hereby published for the first time after 1979 and for the very first time in English as the expression of our deep respect for the tradition and those whose names were mentioned in this booklet.

We are grateful to everybody, especially Prim. Dr. Gusman.

Orthopedic surgeons of Novi Sad

Gusman Đ. Short History of Orthopedic Surgery and Traumatology in Novi Sad (*Kratak istorijat razvoja Ortopedske hirurgije i traumatologije u Novom Sadu*). Novi Sad: Serbian National Theater; 1979.

Orthopedic surgery began to develop in Novi Sad in the 1930s. Since there were no specialists in orthopedics in this region at that time, surgeons of other specialties dealt with orthopedic problems. Thus, Dr. Jakov Vujić, Dr. Pravdica, Dr. Holender and Dr. Brezovski, who were distinguished doctors of that time, treated orthopedic patients either at the Surgical Ward of the General Hospital or within their private practice.

One of the milestones in further development of this medical discipline in that period was the foundation of Children's Sanatorium for the Treatment of Bone Tuberculosis in Sremska Kamenica in 1934. A well-known benefactor of our people, Dr. Katherine S. Macphail used the money donated by Lord Hyde and the Canadian Red Cross and succeeded in buying a piece of land in Sremska Kamenica on a beautiful slope of Fruska Gora with a lot of sunshine and fresh air good for treating bone tuberculosis. A hospital-sanatorium was built there and it is still used for treating orthopedic patients. This health resort was in operation until the beginning of the World War II and was reopened in 1945 when Dr. Macphail returned to Sremska Kamenica and had the dilapidated buildings restored. Dr. Macphail stayed there until 1947, when this hospital was nationalized but remained active in treatment of bone tuberculosis in children under the supervision of Prof. Dr. Svetislav Stojanovic and other doctors from the Department of Orthopedic Surgery and Traumatology from Belgrade until 1963 when it was affiliated to the newly founded Hospital in Novi Sad.

In the period from the end of the World War II until 1956, there was a small section within the I Surgical Ward of the General Provincial Hospital. This section with 10 beds was used to perform orthopedic surgeries in a very narrow range but in accordance with the contemporary conditions and demands. Since this section was run by general surgeons, i.e. residents supervised by one of the speci-

alists, the whole activity was mostly reduced to managing injuries to bones and joints or their conservative treatment. The rest of orthopedic surgery was neglected, which is understandable when it is known that there was not a single orthopedist in Novi Sad at that time.

Such a range of activities was sufficient for the post-war period; however, it soon became evident that the ever growing demands could not be satisfied. The first step in solving this problem was made in

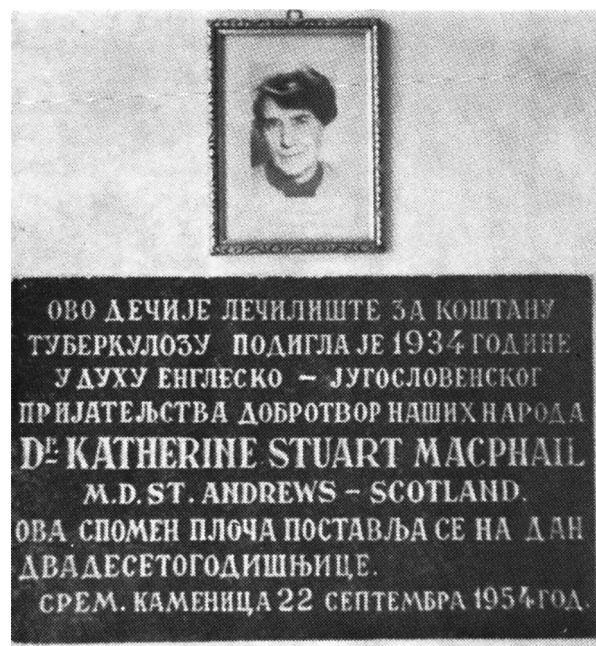

Figure 1. The photograph of Dr. Katherine Macphail and the memorial plaque placed on the Building of Ward for Orthopedics and Traumatology in Sremska Kamenica. Dr. Katherine Stuart Macphail was born in Scotland in 1881 and died in 1974 in St Andrews, Scotland. In December 1914, she went to Thessaloniki with the Scottish Women's Hospital and later came to Serbia at war, where she devoted herself to treating the wounded and ill people. After the World War I she went to Belgrade, where she organized several hospitals and in 1934 she moved to Sremska Kamenica.

Slika 1. Fotografija i spomen ploča dr Katherine Macphail u Zgradi Ortopedsko-traumatološkog odeljenja u Sremskoj Kamenici. Dr Katherine Macphail rođena je 1881. godine u Škotskoj, a umrla je 1974. godine u gradu St. Andrews u Škotskoj. Decembra 1914. godine dolazi sa bolnicom škotskih žena u Solun, a kasnije u zaraćenu Srbiju gde predano radi na lečenju ranjenih i obolelih. Po završetku I svetskog rata dolazi u Beograd gde je bila organizator nekoliko bolnica i gde radi do 1934. godine, kada prelazi u Sremsku Kamenicu



Figure 2. The building of Children's Sanatorium for the Treatment of Bone Tuberculosis in Sremska Kamenica
Slika 2. Zgrada bivšeg Dečjeg lečilišta za koštanu tuberkulozu u Sremskoj Kamenici.

October 1956, when orthopedic surgery was separated from the Surgical Ward and became independent Ward for Orthopedics and Traumatology, whose first head was Dr. Vladimir Raženj. Thus, the conditions were




Figure 3. Prof. Dr. Svetislav Stojanović (born on November 28, 1895 – died on July 16, 1974 in Belgrade) visiting Sremska Kamenica in 1968

Slika 3. Prof. dr Svetislav Stojanović (rođen 28. novembra 1895. godine, umro 16. jula 1974. god. u Beogradu) prilikom jedne posete Sremskoj Kamenici 1968. godine.

created for further development of orthopedic service in Novi Sad.

This Children's Sanatorium for the Treatment of Bone Tuberculosis was established by Dr. Katherine Stuart Macphail M.D. St. Andrews – Scotland in 1934, the benefactor of our people, as the token of English-Yugoslav friendship. This memorial plaque is placed to celebrate the twentieth anniversary. Sremska Kamenica on 22nd of September, 1954

The beginnings of the newly founded Ward were very modest. It was not easy to organize the complete medical service (both for out- and in-patients) with three doctors (one specialist and two residents) and about 40 beds. However, thanks to the good organization and enthusiasm of this small team, which included 20 members, the Ward overcame the initial difficulties and weaknesses successfully and became what it was in two years time.

In the middle of 1958 Dr Vladimir Raženj moved from Novi Sad, leaving behind a well-organized service in full operation. However, since he was not only the head of the Ward but the only specialist, his departure endangered normal functioning of the Ward and a solution to this problem had to be found fast. And it was indeed found fast thanks to understanding and active support of the late Prof. Dr. Svetislav Stojanović, contemporary manager of the Department of Orthopedic Surgery and Traumatology.



Figure 4. Dr. Vladimir Raženj
Slika 4. Dr. Vladimir Raženj

logy in Belgrade. Prof. Dr. Živojin Bumbaširević, Prof. Dr. Djordje Milošević, Prof. Dr. Branko Radulović and Prof. Dr. Cvetko Rakić, who were then young specialists and assistant lecturers at the Faculty of Medicine in Belgrade, and now distinguished and leading experts in orthopedic surgery, took turns in coming to Novi Sad and stayed for 2 months to perform the duties of the head of the ward and thus enabled continuous functioning of the Ward until the end of 1959, when a new head of the Ward was elected. It was Dr. Dobrivoje Gradištanac, who was then assistant lecturer at the Faculty of Medicine in Belgrade. Being an excellent expert and organizer, he led the Ward into its second phase of development. The number of beds rose from 40 to 80, the number of doctors increased from 3 to 6 and later to 7, thus widening the scope of work.

When the Faculty of Medicine was established in Novi Sad in 1961, the former General Provincial Hospital became the Clinical Hospital with departments and institutes instead of former wards. Thus the Department of Surgical Diseases was formed in 1963 and it included previously independent wards: surgical, orthopedic-traumatology and urological ward. Further development of surgical service created the conditions as well as the necessity for opening new wards such as the Ward for Reanimation



Figure 5. Prim. Dr. Dobrivoje Gradištanac (born on March 13, 1915 – died on July 16, 1969)

Slika 1. Prim. dr Dobrivoje Gradištanac (rođen 13. marta 1915. god., umro 16. jula 1969. god).



Figure 6. The Ward for Orthopedics and Traumatology within the Clinical Center in Novi Sad

Slika 6. Zgrada Ortopedsko-traumatološkog odeljenja u kliničkom krugu u Novom Sadu.

and Anesthesia, Children's Surgical Ward, Neurosurgical Ward, Ward for Plastic and Reconstructive Surgery and the Ward for Maxillo-facial Surgery. There have been only minor changes to this organizational scheme so far.

When the Department of Surgical Diseases was formed in 1963, the former Ward for Orthopedics and Traumatology was divided into two separate units: the Ward for Orthopedics and the Ward for Traumatology. In the same year, Dr. Dobrivoje Gradištanac left Novi Sad and Dr. Milenko Došen became the head of the Ward for Orthopedics and Dr. Stojan Letić was appointed the head of the Ward for Traumatology. Both wards were situated in the same building which was given to this Department when the Department of Gynecology and Obstetrics was moved to another location. The ground floor with about 30 beds was within the Ward for Orthopedics and the first floor with about 45 beds was allocated to the Ward for Traumatology. Each Ward had its own operating room under the same roof, and the emergency medical service was within the Emergency Service of the Department and outpatient service was shared with the united specialist polyclinic.

In addition, the former Children's Sanatorium for the Treatment of Bone Tuberculosis in Sremska Kamenica was affiliated to these two wards, thus the Ward for Orthopedics got 30 beds and the rest of beds were given to the Ward for Traumatology.

Such an organizational division into two wards lasted for more than 12 years. The two wards developed during that period, each in its own domain. A considerable number of young specialists were educated in the meantime, one of who became the doctor of medical science, the first one from the field of orthopedic surgery. Having defended his doctoral thesis, Dr. Milenko Došen was elected Associate Professor at the Faculty of Medicine at the beginning of 1971 and he started teaching orthopedics at the Faculty of Medicine.



Figure 7. Prof. Dr. Svetislav Stojanović and Prof. Dr. Milenko Došen, visiting Novi Sad in 1968

Slika 7. Prof. dr Svetislav Stojanović u društvu sa prof. dr Milenkom Došenom prilikom jedne posete Novom Sadu 1968. godine.

Due to the increasing demands and further development of this medical discipline, these two Wards merged into one, the Ward for Orthopedics and Traumatology within the Department of Surgical Diseases. It happened in June, 1975 and Dr. Milenko Došen was appointed its chief. Dr. Došen was



Figure 8. Staff members of the Ward for Orthopedics and Traumatology in Sremska Kamenica and Prof Dr Svetislav Stojanović during his last visit in 1968

Slika 8. Osoblje Ortopedsko-traumatološkog odeljenja u Sremskoj Kamenici 1968. godine kada je ovo odeljenje po poslednji put posetio prof. dr Svetislav Stojanović.

elected Full Professor of Orthopedic Surgery at the Faculty of Medicine in Novi Sad in June 1978.

The capacity of the Ward for Orthopedics and Traumatology is 140 beds, 77 beds are in the building on the hospital ground and 33 beds are in Sremska Kamenica. In order to achieve better performance and to improve its development, the Ward is divided into six sections whose heads are Prim. Dr. Djordje Gusman, Dr. Aleksandar Jovanović, Assist. Prof. Jovan Krajčinović, Prim. Dr. Branko Lakić, Assist. Prof. dr. Želimir Mikić and Dr Dragoslav Stanić. There are four more orthopedists (Dr Milutin Fratucan, Assist. Lecturer Dr. Djordje Janjić, Dr. Vladislav Stojić and Dr. Stevan Vukadinović), one physiatrist (Dr. Deže Szep) as well as six residents (Dr. Vučko Ćirić, Dr. Goran Ercegan, Dr. Aleksandar Miličić, Dr. Tibor Somer, dr. Vladimir Šarčev and Dr. Miloš Tubić). Several residents specializing in other disciplines also come to the Ward on a regular basis to perform their duties. Apart from doctors there are 71 employees of various profiles, including 5 nurses with high school diploma and 20 nurses with secondary school diploma, 2 physiotherapists, 9 orthopedic cast technicians as well as 7 clerks, 4 hospital orderlies, 8 hospital food service workers and 14 cleaners.

The Ward for Orthopedics and Traumatology is the teaching basis of the Faculty of Medicine and it includes one full professor, 2 assistant professors and one assistant lecturer. It is also the basis for specialization in orthopedics. Dr. Želimir Mikić was the first doctor




Figure 9. Medical Staff of the Ward for Orthopedics and Traumatology – September 1979. Sitting from left to right: Dr. Aleksandar Jovanović, Assist Prof. Dr. Želimir Mikić, Prim. Dr. Đorđe Gusman, Prof. Dr. Milenko Došen, Prim. Dr. Branko Lakić, Assist Prof. Dr. Jovan Krajčinović, Dr. Dragan Stanić; standing from left to right: Dr. Milutin Fratucan, Dr. Goran Ercegan, Dr. Vučko Ćirić, Ddr Stevan Vukadinović, Assist Lecturer Dr. Đorđe Janjić, Dr. Vladislav Stojić, Dr. Miloš Tubić, Dr. Vladimir Šarčev, Dr. Tibor Somer and Dr. Deže Szep.

Slika 9. Kolegijum Ortopedsko-traumatološkog odeljenja septembra meseca 1979. godine. Sede (sa leva na desno): dr Aleksandar Jovanović, doc. dr Želimir Mikić, prim, dr Đorđe Gusman, prof, dr Milenko Došen, prim, dr Branko Lakić, doc. dr Jovan Krajčinović, dr Dragan Stanić; stoji (sa leva na desno): dr Milutin Fratucan, dr Goran Ercegan, dr Vučko Ćirić, dr Stevan Vukadinović, asist. dr Đorđe Janjić, dr Vladislav Stojić, dr Miloš Tubić, dr Vladimir Šarčev, dr Tibor Somer i dr Deže Szep.

who passed the specialist examination in orthopedics on February 28, 1969 in front of the newly-formed examination board, and since that day there has been a great number of residents coming from Vojvodina and other parts of our country who have taken this examination at the Ward.

In addition to rendering health care service and teaching, doctors working at this Ward perform significant scientific research and publicizing activities. There are 3 doctors of medical science at the Ward and 3 master theses are being done as well as several research and experimental projects.

When the Department of Surgical Diseases was established in 1963, the service of the Ward for Orthopedics and Traumatology was divided into the part for treating adults and the part for treating children which is affiliated to the Institute of Maternal and Child Health as the Ward for Children's Surgery, where two orthopedists, Assistant Professor Dr. Dušan Pajić and Dr. Stevan Veselinov, perform surgeries.

With its versatile and intensive activities, the Ward for Orthopedics and Traumatology in Novi Sad has significantly contributed to the development of this service in Vojvodina. In order to promote this service even further, the Section for Orthopedic Surgery and Traumatology was founded on May 21, 1971 within the Society of Physicians of Vojvodina. Nowadays, the Section has 53 members, whose activities are remarkable.

At the present moment, the Ward for Orthopedics and Traumatology is at another important turning

point since the procedure of separating this Ward from the Department of Surgical Diseases is under way and this Ward is about to become an independent Department of Orthopedic Surgery and Traumatology affiliated to the Faculty of Medicine in Novi Sad.

This reorganization will be followed by the general adaptation and restoration of the building on the hospital ground which will have 60 beds, reception desk for emergencies and two operating theaters with state-of-the-art equipment. In addition, the new polyclinic building within the Clinical Center is under construction which will provide this service with 650 m² of modernly equipped space besides 60 beds in the old building of the Children's Sanatorium in Sremska Kamenica, which was fully restored in 1976.

The newly-established Department of Orthopedic Surgery and Traumatology will thus have all the necessary conditions for its activities and further development of orthopedic surgery in Novi Sad.


This is a short history of the development of orthopedics in this region which started 45 years ago, running from a small ward established 23 years ago to a modern university department. At the end of this short review of the development of orthopedic surgery in Novi Sad I feel obliged to offer my apologies to all those who have not been mentioned here by name but who have contributed greatly to all these achievements.



Rehabilitation team of the Department of Orthopedic Surgery and Traumatology
Rehabilitacioni tim Klinike za ortopedsku hirurgiju i traumatologiju



ALEKSANDAR MN



Preduzeće za spoljnu i unutrašnju trgovinu



Science For A Better Life



Proizvodnja osteosintetskog materijala i veštačkih proteza kuka



Mylan

Seeing is believing

UPUTSTVO ZA AUTORE

Časopis *Medicinski pregled* objavljuje radove koji prethodno nisu objavljeni niti poslani u drugi časopis. U Časopisu mogu biti objavljeni radovi iz različitih oblasti biomedicine, koji su namenjeni lekarima različitih specijalnosti.

Od 1. januara 2013. godine *Medicinski pregled* je počeo da koristi usluge *e-Ur* – Elektronskog uređivanja časopisa. Svi korisnici sistema – autori, recenzenti i urednici, moraju biti registrovani korisnici sa jednom elektronskom adresom.

Korisnici časopisa treba da se registruju na adresi:

<http://aseestant.ceon.rs/index.php/medpreg/user/register>

Prijava rada treba da se učini na adresi:

<http://aseestant.ceon.rs/index.php/medpreg/>

U postupku prijave neophodno je da se pošalje saglasnost i izjava autora i svih koautora da rad nije delimično ili u celini objavljen ili prihvaćen za štampu u drugom časopisu.

Elektronsko uređivanje časopisa obezbeđuje korišćenje sistema *CrossCheck*, koji prijavljene radove automatski proverava na plagijarizam i autoplagijarizam. Autori ne bi smeli da pošalju isti rad u više časopisa istovremeno. Ukoliko se to desi, glavni urednik časopisa *Medicinski pregled* ima pravo da rad vrati autorima bez prethodnog slanja rada na recenziju; da odbije štampanje rada; da se obrati urednicima drugih časopisa u koje je rad poslat ili da se obrati direktoru ustanove u kojoj su autori rada zaposleni.

Primaju se samo radovi koji su napisani na engleskom jeziku, uz sažetak rada i naslov rada koji treba da budu napisani na engleskom i srpskom jeziku.

Radove koji su pristigli u časopis *Medicinski pregled* pregleda jedan ili više članova Uređivačkog odbora Časopisa. Oni radovi koji su napisani prema pravilima Časopisa šalju se na anonimnu recenziju kod najmanje dva recenzenta, stručnjaka iz odgovarajuće oblasti biomedicine. Načinjene recenzije radovala pregleda glavni urednik ili članovi Uređivačkog odbora i one nisu garancija da će rad biti prihvaćen za štampu. Materijal koji je pristigao u časopis ostaje poverljiv dok se rad nalazi na recenziji, a identitet autora i recenzentata su zaštićeni, osim u slučaju ako oni odluče drugačije.

U časopisu *Medicinski pregled* objavljuju se: uvodnici, originalni članci, prethodna ili kratka saopštenja, pregledni članci, stručni članci, prikazi slučajeva, članci iz istorije medicine i drugi članci.

1. Uvodnici – do 5 strana. Sadrže mišljenja ili diskusiju o posebno značajnoj temi za Časopis, kao i o podacima koji su štampani u ovom ili nekom drugom časopisu. Obično ih piše jedan autor po pozivu.

2. Originalni članci – do 12 strana. Predstavljaju rezultate istraživanja autora rada i njihovo tumačenje. Istraživanje treba da bude obrađeno i izloženo na način da se može ponoviti, a analiza rezultata i zaključci jasni da bi se mogli proveriti.

3. Pregledni članci – do 10 strana. Predstavljaju sistematsko, sveobuhvatno i kritičko izlaganje problema na osnovu analiziranih i diskutovanih podataka iz literature, a koji oslikavaju postojeću situaciju u određenom području istraživanja. Literatura koja se koristi u radu mora da sadrži najmanje 5 radova autora članka iz uže naučne oblasti koja je opisana u radu.

4. Prethodna ili kratka saopštenja – do 4 strane. Sadrže izuzetno važne naučne rezultate koje bi trebalo objaviti u što kraćem vremenu. Ne moraju da sadrže detaljan opis metodologije rada i rezultata, ali moraju da imaju sva poglavlja kao originalni članci u sažetoj formi.

5. Stručni članci – do 10 strana. Odnose se na proveru ili prikaz prethodnog istraživanja i predstavljaju koristan izvor za širenje znanja i prilagođavanja originalnog istraživanja potrebama postojeće nauke i prakse.

6. Prikazi slučajeva – do 6 strana. Opisuju retke slučajeve iz prakse. Slični su stručnim člancima. U ovim radovima pri-

kazuju se neobičajeni oblici i tokovi oboljenja, neočekivane reakcije na primenjenu terapiju, primene novih dijagnostičkih procedura ili retke i nove bolesti.

7. Članci iz istorije medicine – do 10 strana. Ovi članci opisuju događaje iz prošlosti sa ciljem da omogućе očuvanje medicinske i zdravstvene kulture. Imaju karakter stručnih članaka.

8. Ostali članci – U časopisu *Medicinski pregled* objavljuju se feljtoni, prikazi knjiga, izvodi iz strane literature, izveštaji sa kongresa i stručnih sastanaka, saopštenja o radu pojedinih zdravstvenih organizacija, podružnica i sekcija, saopštenja Uredništva, pisma Uredništvu, novosti u medicini, pitanja i odgovori, stručne i staleške vesti i članci napisani u znak sećanja (*In memoriam*).

Priprema rukopisa

Kompletan rukopis, uključujući tekst rada, sve priloge i propratno pismo, treba poslati na elektronsku adresu koja je prethodno navedena.

Propratno pismo:

– mora da sadrži izjavu svih autora da se radi o originalnom radu koji prethodno nije objavljen niti prihvaćen za štampu u drugim časopisima;

– autori svojim potpisom preuzimaju odgovornost da rad ispunjava sve postavljene uslove i da ne postoji sukob interesa i

– autor mora navesti kategoriju članka (originalni rad, pregledni rad, prethodno saopštenje, stručni rad, prikaz slučaja, rad iz istorije medicine, itd.).

Rukopis

Opšta uputstva

Tekst rada treba da bude napisan u programu *Microsoft Word* za *Windows*, na A4 formatu stranice (sve četiri margine 2,5 cm), proreda 1,5 (isto važi i za tabele), fontom *Times New Roman*, veličinom slova 12 pt. Neophodno je koristiti međunarodni sistem mernih jedinica (*SI*), uz izuzetak temperature (°C) i krvnog pritiska (*mmHg*).

Rukopis treba da sadrži sledeće elemente:

1. Naslovna strana

Naslovna strana treba da sadrži: kratak i sažet naslov rada, bez skraćenica, skraćeni naslov rada (do 40 karaktera), imena i prezimena autora (ne više od 6) i afilijacije svih autora. Na dnu strane treba da piše ime, prezime i titula autora zaduženog za korespondenciju, njena/njegova adresa, elektronska adresa, broj telefona i faksa.

2. Sažetak

Sažetak ne može da sadrži više od 250 reči niti skraćenice. Treba da bude strukturisan, kratak i sažet, sa jasnim pregledom problema istraživanja, ciljevima, metodama, značajnim rezultatima i zaključcima.

Sažetak originalnih i stručnih članaka treba da sadrži uvod (sa ciljevima istraživanja), materijale i metode, rezultate i zaključak.

Sažetak prikaza slučaja treba da sadrži uvod, prikaz slučaja i zaključak.

Sažetak preglednih članaka treba da sadrži Uvod, podnaslove koji odgovaraju istima u tekstu i Zaključak.

Naveći do 10 ključnih reči ispod sažetka. One su pomoć prilikom indeksiranja, ali autorove ključne reči mogu biti izmenjene u skladu sa odgovarajućim deskriptorima, odnosno terminima iz *Medical Subject Headings, MeSH*.

Sažetak treba da bude napisan na srpskom i engleskom jeziku. Sažetak na srpskom jeziku trebalo bi da predstavlja prevod sažetka na engleskom, što podrazumeva da sadrži jednake delove.

3. Tekst članka

Originalni rad treba da sadrži sledeća poglavlja: Uvod (sa jasno definisanim ciljevima istraživanja), Materijal i metode, Rezultati, Diskusija, Zaključak, spisak skraćenica (ukoliko su

korišćene u tekstu). Nije neophodno da se u posebnom poglavlju rada napiše zahvalnica onima koji su pomogli da se istraživanje uradi, kao i da se rad napiše.

Prikaz slučaja treba da sadrži sledeća poglavlja: Uvod (sa jasno definisanim ciljevima), Prikaz slučaja, Diskusija i Zaključak.

Uvod

U poglavlju Uvod potrebno je jasno definisati predmet istraživanja (prirodu i značaj istraživanja), navesti značajne navode literature i jasno definisati ciljeve istraživanja i hipoteze.

Materijal i metode

Materijal i metode rada treba da sadrže podatke o vrsti studije (prospektivna/retrospektivna, uslove za uključivanje i ograničenja studije, trajanje istraživanja, demografske podatke, period praćenja). Detaljno treba opisati statističke metode da bi čitaoci rada mogli da provere iznesene rezultate.

Rezultati

Rezultati predstavljaju detaljan prikaz podataka koji su dobijeni istraživanjem. Sve tabele, grafikoni, sheme i slike moraju biti citirani u tekstu rada i označeni brojevima po redosledu njihovog navođenja.

Diskusija

Diskusija treba da bude koncizna, jasna i da predstavlja tumačenje i poređenje rezultata studije sa relevantnim studijama koje su objavljene u domaćoj i međunarodnoj literaturi. U poglavlju Diskusija potrebno je naglasiti da li su postavljene hipoteze potvrđene ili nisu, kao i istaknuti značaj i nedostatke istraživanja.

Zaključak

Zaključci moraju proisteći isključivo iz rezultata istraživanja rada; treba izbegavati uopštene i nepotrebne zaključke. Zaključci koji su navedeni u tekstu rada moraju biti u saglasnosti sa zaključcima iz Sažetka.

4. Literatura

Potrebno je da se literatura numeriče arapskim brojevima redosledom kojim je u tekstu navedena u parentezama; izbegavati nepotrebno velik broj navoda literature. Časopise bi trebalo navoditi u skraćenom obliku koji se koristi u *Index Medicus* (<http://www.nlm.nih.gov/tsd/serials/lji.html>). Pri citiranju literature koristiti Vankuverski sistem. Potrebno je da se navedu svi autori rada, osim ukoliko je broj autora veći od šest. U tom slučaju napisati imena prvih šest autora praćeno sa *et al.*

Primeri pravilnog navođenja literature nalaze se u nastavku.

Radovi u časopisima

* Standardni rad

Ginsberg JS, Bates SM. Management of venous thromboembolism during pregnancy. *J Thromb Haemost* 2003;1:1435-42.

* Organizacija kao autor

Diabetes Prevention Program Research Group. Hypertension, insulin, and proinsulin in participants with impaired glucose tolerance. *Hypertension* 2002;40(5):679-86.

* Bez autora

21st century heart solution may have a sting in the tail. *BMJ*. 2002;325(7357):184.

* Volumen sa suplementom

Magni F, Rossoni G, Berti F. BN-52021 protects guinea pig from heart anaphylaxis. *Pharmacol Res Commun* 1988;20 Suppl 5:75-8.

* Sveska sa suplementom

Gardos G, Cole JO, Haskell D, Marby D, Pame SS, Moore P. The natural history of tardive dyskinesia. *J Clin Psychopharmacol* 1988;8(4 Suppl):31S-37S.

* Sažetak u časopisu

Fuhrman SA, Joiner KA. Binding of the third component of complement C3 by *Toxoplasma gondi* [abstract]. *Clin Res* 1987;35:475A.

Knjige i druge monografije

* Jedan ili više autora

Murray PR, Rosenthal KS, Kobayashi GS, Pfaller MA. *Medical microbiology*. 4th ed. St. Louis: Mosby; 2002.

* Urednik (urednici) kao autor (autori)

Danset J, Colombani J, eds. *Histocompatibility testing 1972*. Copenhagen: Munksgaard, 1973:12-8.

* Poglavlje u knjizi

Weinstein L, Shwartz MN. Pathologic properties of invading microorganisms. In: Soderman WA Jr, Soderman WA, eds. *Pathologic physiology: mechanisms of disease*. Philadelphia: Saunders; 1974. p. 457-72.

* Zbornik radova sa kongresa

Christensen S, Oppacher F. An analysis of Koza's computational effort statistic for genetic programming. In: Foster JA, Lutton E, Miller J, Ryan C, Tettamanzi AG, editors. *Genetic programming. EuroGP 2002: Proceedings of the 5th European Conference on Genetic Programming; 2002 Apr 3-5; Kinsdale, Ireland*. Berlin: Springer; 2002. p. 182-91.

* Disertacija

Borkowski MM. *Infant sleep and feeding: a telephone survey of Hispanic Americans* [dissertation]. Mount Pleasant (MI): Central Michigan University; 2002.

Elektronski materijal

* Članak iz časopisa u elektronskom formatu

Aboud S. Quality improvement initiative in nursing homes: the ANA acts in an advisory role. *Am J Nurs* [Internet]. 2002 Jun [cited 2002 Aug 12];102(6):[about 1 p.]. Available from: <http://www.nursingworld.org/AJN/2002/june/Wawatch.htm#Article>

* Monografija u elektronskom formatu

CDI, clinical dermatology illustrated [monograph on CD-ROM]. Reeves JRT, Maibach H. CMEA Multimedia Group, producers. 2nd ed. Version 2.0. San Diego:CMEA;1995.

* Kompjuterska datoteka

Hemodynamics III: the ups and downs of hemodynamics [computer program]. Version 2.2. Orlando (FL): Computerized Educational Systems; 1993.

5. Prilozi (tabele, grafikoni, sheme i slike)

BROJ PRILOGA NE SME BITI VEĆI OD ŠEST!

Tabele, grafikoni, sheme i slike se postavljaju kao posebni dokumenti.

– Tabele i grafikone bi trebalo pripremiti u formatu koji je kompatibilan programu u kojem je napisan tekst rada. Slike bi trebalo poslati u jednom od sledećih oblika: *JPG, GIF, TIFF, EPS*.

– Svaki prilog mora biti obeležen arapskim brojem prema redosledu po kojem se navodi u tekstu rada.

– Naslovi, tekst u tabelama, grafikonima, shemama i legendi slika bi trebalo da budu napisani na srpskom i engleskom jeziku.

– Nestandardne priloge označiti u fusnoti uz korišćenje sledećih simbola: *, †, ‡, §, ||, ¶, **, † †, ‡ ‡.

– U legendi slika trebalo bi napisati korišćeno uveličanje okulara i objektivna mikroskopa. Svaka fotografija treba da ima vidljivu skalu.

– Ako su tabele, grafikoni, sheme ili slike već objavljene, navesti originalni izvor i priložiti pisano odobrenje autora za njihovo korišćenje.

– Svi prilozi će biti štampani kao crno-bele slike. Ukoliko autori žele da se prilozi štampaju u boji, obavezno treba da plate dodatne troškove.

6. Dodatne obaveze

AUTORI I SVI KOAUTORI RADA OBAVEZNO TREBA DA PLATE GODIŠNJU PRETPLATU ZA ČASOPIS *MEDICINSKI PREGLED*. U PROTIVNOM, RAD NEĆE BITI ŠTAMPAN U ČASOPISU.

INFORMATION FOR AUTHORS

Medical Review publishes papers (previously neither published in nor submitted to any other journals) from various fields of biomedicine intended for broad circles of doctors.

Since January 1st, 2013 the Medical Review has been using the service e-Ur: Electronic Journal Editing. All users of the Registration system, i.e. authors, reviewers, and editors have to be registered users with only one e-mail address. Registration should be made on the web address:

<http://aseestant.ceon.rs/index.php/medpreg/user/register>.

Manuscript submission should be made on the web address:

<http://aseestant.ceon.rs/index.php/medpreg/>

A SUPPLEMENTARY FILE, WITH THE STATEMENT THAT THE PAPER HAS NOT BEEN SUBMITTED OR ACCEPTED FOR PUBLICATION ELSEWHERE AND A CONSENT SIGNED BY ALL AUTHORS, HAVE TO BE ENCLOSED WITH THE MANUSCRIPT.

Authors may not send the same manuscript to more than one journal concurrently. If this occurs, the Editor may return the paper without reviewing it, reject the paper, contact the Editor of the other journal(s) in question and/or contact the author's employers.

Papers should be written in English language, with an abstract and title page in English, as well as in Serbian language.

All papers submitted to **Medical Review** are seen by one or more members of the Editorial Board. Suitable articles are sent to at least two experts to be reviewed, their reports are returned to the assigned member of the Editorial Board and the Editor. Revision of an article gives no guarantee of acceptance and in some cases revised articles are rejected if the improvements are not sufficient or new issues have arisen. Material submitted to *the Journal* remains confidential while being reviewed and peer-reviewers' identities are protected unless they elect to lose anonymity.

Medical Review publishes the following types of articles: editorials, original studies, preliminary reports, review articles, professional articles, case reports, articles from history of medicine and other types of publications.

1. Editorials – up to 5 pages – convey opinions or discussions on a subject relevant for the Journal. Editorials are commonly written by one author by invitation.

2. Original studies – up to 12 pages – present the authors' own investigations and their interpretations. They should contain data which could be the basis to check the obtained results and reproduce the investigative procedure.

3. Review articles – up to 10 pages – provide a condensed, comprehensive and critical review of a problem on the basis of the published material being analyzed and discussed, reflecting the current situation in one area of research. Papers of this type will be accepted for publication provided that the authors confirm their expertise in the relevant area by citing at least 5 self-citations.

4. Preliminary reports – up to 4 pages – contain scientific results of significant importance requiring urgent publishing; however, it need not provide detailed description for repeating the obtained results. It presents new scientific data without a detailed explanation of methods and results. It contains all parts of an original study in an abridged form.

5. Professional articles – up to 10 pages – examine or reproduce previous investigation and represent a valuable source of knowledge and adaption of original investigations for the needs of current science and practice.

6. Case reports – up to 6 pages – deal with rare casuistry from practice important for doctors in direct charge of patients and are similar to professional articles. They emphasize unusual characteristics and course of a disease, unexpected reactions to a therapy, application of new diagnostic procedures and describe a rare or new disease.

7. History of medicine – up to 10 pages – deals with history with the aim of providing continuity of medical and health care culture. They have the character of professional articles.

8. Other types of publications – The journal also publishes feuilletons, book reviews, extracts from foreign literature, reports from congresses and professional meetings, communications on activities of certain medical institutions, branches and sections, announcements of the Editorial Board, letters to the Editorial Board, novelties in medicine, questions and answers, professional and vocational news and In memoriam.

Preparation of the manuscript

The complete manuscript, including the text, all supplementary material and covering letter, is to be sent to the web address above.

The covering letter:

– It must contain the proof given by the author that the paper represents an original work that it has neither been previously published in other journals nor is under consideration to be published in other journals.

– It must confirm that all the authors meet criteria set for the authorship of the paper, that they agree completely with the text and that there is no conflict of interest.

– It must state the type of the paper submitted (an original study, a review article, a preliminary report, a professional article, a case report, history of medicine).

The manuscript:

General instructions.

Use Microsoft Word for Windows to type the text. The text must be typed in font *Times New Roman*, page format A4, space 1.5 (for tables as well), margins set to 2.5 cm and font size 12pt. All measurements should be reported in the metric system of the International System of Units – SI. Temperature should be expressed in Celsius degrees (°C) and pressure in mmHg.

The manuscript should contain the following elements:

1. The title page.

The title page should contain a concise and clear title of the paper, without abbreviations, then a short title (up to 40 characters), full names and surnames of the authors (not more than 6) indexed by numbers corresponding to those given in the heading along with the full name and place of the institutions they work for. Contact information including the academic degree(s), full address, e-mail and number of phone or fax of the corresponding author (the author responsible for correspondence) are to be given at the bottom of this page.

2. Summary.

The summary should contain up to 250 words, without abbreviations, with the precise review of problems, objectives, methods, important results and conclusions. It should be structured into the paragraphs as follows:

– Original and professional papers should have the introduction (with the objective of the paper), materials and methods, results and conclusion

– Case reports should have the introduction, case report and conclusion

– Review papers should have the introduction, subtitles corresponding to those in the paper and conclusion.

The authors should provide up to 10 keywords below the summary. These keywords will assist indexers in cross-indexing the article and will be published with the summary, but the authors' keywords could be changed in accordance with the list of Medical Subject Headings, MeSH of the American National Medical Library.

The summary should be written in both languages, English as well as Serbian. The summary in Serbian language should be the translation of the summary in English; therefore, it has to contain the same paragraphs.

3. The text of the paper.

The text of original studies must contain the following: introduction (with the clearly defined objective of the study), materials and methods, results, discussion, conclusion, list of abbreviations (if used in the text) and not necessarily, the acknowledgment mentioning those who have helped in the investigation and preparation of the paper.

The text of a case report should contain the following: introduction (with clearly defined objective of the study), case report, discussion and conclusion.

Introduction contains clearly defined problem dealt with in the study (its nature and importance), with the relevant references and clearly defined objective of the investigation and hypothesis.

Materials and methods should contain data on design of the study (prospective/retrospective, eligibility and exclusion criteria, duration, demographic data, follow-up period). Statistical methods applied should be clear and described in details.

Results give a detailed review of data obtained during the study. All tables, graphs, schemes and figures must be cited in the text and numbered consecutively in the order of their first citation in the text.

Discussion should be concise and clear, interpreting the basic findings of the study in comparison with the results of relevant studies published in international and national literature. It should be stated whether the hypothesis has been confirmed or denied. Merits and demerits of the study should be mentioned.

Conclusion must deny or confirm the attitude towards the Obased solely on the author's own results, corroborating them. Avoid generalized and unnecessary conclusions. Conclusions in the text must be in accordance with those given in the summary.

4. References are to be given in the text under Arabic numerals in parentheses consecutively in the order of their first citation. Avoid a large number of citations in the text. The title of journals should be abbreviated according to the style used in Index Medicus (<http://www.nlm.nih.gov/tsd/serials/lji.html>). Apply Vancouver Group's Criteria, which define the order of data and punctuation marks separating them. Examples of correct forms of references are given below. List all authors, but if the number exceeds six, give the names of six authors followed by 'et al'.

Articles in journals

** A standard article*

Ginsberg JS, Bates SM. Management of venous thromboembolism during pregnancy. *J Thromb Haemost* 2003;1:1435-42.

** An organization as the author*

Diabetes Prevention Program Research Group. Hypertension, insulin, and proinsulin in participants with impaired glucose tolerance. *Hypertension* 2002;40(5):679-86.

** No author given*

21st century heart solution may have a sting in the tail. *BMJ*. 2002;325(7357):184.

** A volume with supplement*

Magni F, Rossoni G, Berti F. BN-52021 protects guinea pig from heart anaphylaxis. *Pharmacol Res Commun* 1988;20 Suppl 5:75-8.

** An issue with supplement*

Gardos G, Cole JO, Haskell D, Marby D, Pame SS, Moore P. The natural history of tardive dyskinesia. *J Clin Psychopharmacol* 1988;8(4 Suppl):31S-37S.

** A summary in a journal*

Fuhrman SA, Joiner KA. Binding of the third component of complement C3 by *Toxoplasma gondii* [abstract]. *Clin Res* 1987;35:475A.

Books and other monographs

** One or more authors*

Murray PR, Rosenthal KS, Kobayashi GS, Pfaller MA. *Medical microbiology*. 4th ed. St. Louis: Mosby; 2002.

** Editor(s) as author(s)*

Danset J, Colombani J, eds. *Histocompatibility testing 1972*. Copenhagen: Munksgaard, 1973:12-8.

** A chapter in a book*

Weinstein L, Shwartz MN. Pathologic properties of invading microorganisms. In: Soderman WA Jr, Soderman WA, eds. *Pathologic physiology: mechanisms of disease*. Philadelphia: Saunders; 1974. p. 457-72.

** A conference paper*

Christensen S, Oppacher F. An analysis of Koza's computational effort statistic for genetic programming. In: Foster JA, Lutton E, Miller J, Ryan C, Tettamanzi AG, editors. *Genetic programming. EuroGP 2002: Proceedings of the 5th European Conference on Genetic Programming*; 2002 Apr 3-5; Kinsdale, Ireland. Berlin: Springer; 2002. p. 182-91.

** A dissertation and theses*

Borkowski MM. *Infant sleep and feeding: a telephone survey of Hispanic Americans [dissertation]*. Mount Pleasant (MI): Central Michigan University; 2002.

Electronic material

** A journal article in electronic format*

Abood S. Quality improvement initiative in nursing homes: the ANA acts in an advisory role. *Am J Nurs* [Internet]. 2002 Jun [cited 2002 Aug 12];102(6):[about 1 p.]. Available from: <http://www.nursingworld.org/AJN/2002/june/Wawatch.htmArticle>

** Monographs in electronic format*

CDI, clinical dermatology illustrated [monograph on CD-ROM]. Reeves JRT, Maibach H. CMEA Multimedia Group, producers. 2nd ed. Version 2.0. San Diego:CMEA;1995.

** A computer file*

Hemodynamics III: the ups and downs of hemodynamics [computer program]. Version 2.2. Orlando (FL): Computerized Educational Systems; 1993.

5. Attachments (tables, graphs, schemes and photographs).

THE MAXIMUM NUMBER OF ATTACHMENTS ALLOWED IS SIX!

– Tables, graphs, schemes and photographs are to be submitted as separate documents, on separate pages.

– Tables and graphs are to be prepared in the format compatible with Microsoft Word for Windows programme. Photographs are to be prepared in JPG, GIF, TIFF, EPS or similar format.

– Each attachment must be numbered by Arabic numerals consecutively in the order of their appearance in the text

– The title, text in tables, graphs, schemes and legends must be given in both Serbian and English languages.

– Explain all non-standard abbreviations in footnotes using the following symbols *, †, ‡, §, ||, ¶, **, † †, ‡ ‡.

– State the type of color used and microscope magnification in the legends of photomicrographs. Photomicrographs should have internal scale markers.

– If a table, graph, scheme or figure has been previously published, acknowledge the original source and submit written permission from the copyright holder to reproduce it.

– All attachments will be printed in black and white. If the authors wish to have the attachments in color, they will have to pay additional cost.

6. Additional requirements

SHOULD THE AUTHOR AND ALL CO-AUTHORS FAIL TO PAY THE SUBSCRIPTION FOR MEDICAL REVIEW, THEIR PAPER WILL NOT BE PUBLISHED.